

Clinical Image

Projectile Injury Near the Brachial Plexus

Boussaidane M*, Boukhriss J, Chafry B, Benchebba D and Boussouga M

Department of Traumatology and Orthopedics, Military Hospital Mohammed V, Faculty of Medicine and Pharmacy of Rabat, University Mohammed V, Rabat, Morocco

*Corresponding author: Boussaidane Mohammed, Department of Traumatology and Orthopedics, Military Hospital Mohammed V Rabat, Morocco

Received: November 08, 2021; Accepted: December 29, 2021; Published: January 05, 2022

Clinical Image

We report the case of a young 36-year-old rider with no notable pathological history, victim of an explosion from the fire fighting (black powder chamber) of his rifle when firing during the celebrations of TBOURIDA (ancient equestrian art, dating from the 15th century. It is an equestrian representation which simulates a succession of military parades, reconstituted according to ancestral Arab-Amazigh conventions and rituals), Causing the departure of projectile (percussion lock); with impact point on the front of the right shoulder. The examination at the emergency room admission 30 minutes from the accident found a conscious patient, stable hemodynamic state, normal breathing, the inspection objected a wound of 15mm in diameter at the level of the right deltopectoral groove, without an opening exit (Figure 1). The vasculo-nervous examination of the right upper limb was normal. The standard x-ray showed the presence of a foreign body between the glenohumeral joint and the rib cage (Figure 2), the chest CT scan with injection of the contrast product revealed the foreign body located one centimeter from the axillary artery, without lung lesions (Figure 3).

The patient underwent a surgical trimming plan by plan, from the surface to the depth: the skin and the mortified subcutaneous cellulose-fatty tissue are excised to the healthy and vascularized zone

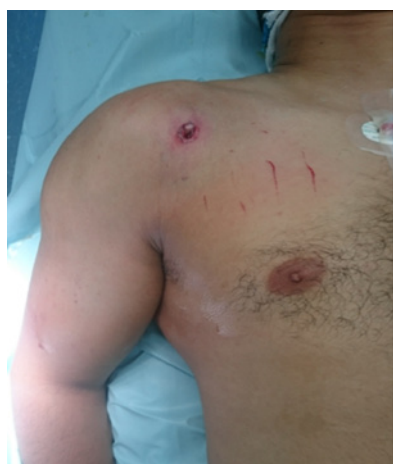

Figure 1: Clinical image showing the entry port.

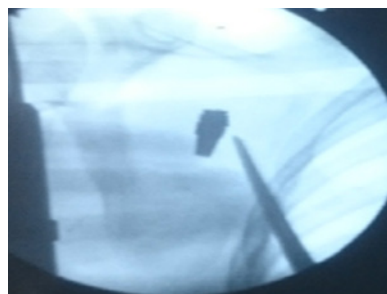

Figure 2: Right shoulder x-ray showing the location of the foreign body.

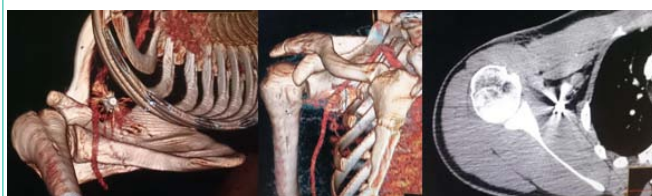

Figure 3: CT scan of the right shoulder showing the location of the foreign body.

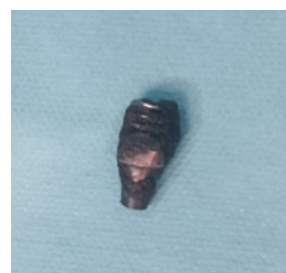


Figure 4: Clinical image showing the nature of the foreign body.

after a prior abundant washing and brushing, then the foreign body is removed (Figure 4), skin closure is deferred to the 3rd day, the patient has benefited from antibiotic therapy based on protected amoxicillin and gentamycin.