

Case Series

# Traumatic Atlantoaxial Rotatory Dislocation in Adult: Report of 10 Cases

**Boukoucha M\*, Chérif A, Loukil H, Ben Khelifa R and Daghfous A**

Department of Radiology, Burns and Trauma Center, Ben Arous, Tunisia

\*Corresponding author: Boukoucha M, Department of Radiology Burns and Trauma Center, Street 1er-Mai 2013 Ben Arous, Tunisia

Received: September 29, 2021; Accepted: October 22, 2021; Published: October 29, 2021

## Introduction

The AARD is related to an extreme rotation of the cervical-occipital hinge following an accidental distraction of the spine. It often occurs in children related to ligament laxity of the cranio-spinal junction. It is rarely encountered in adults, in general, in a context of violent trauma causing a ligament injury. Only about 20 cases have been reported in the literature [1]. The particularity of this entity is its purely rotatory mechanism, which is often without an associated bone fracture. A situation that can make diagnosis difficult and require a trained physician for clinical and radiological diagnosis.

The purpose of this review is to help the young orthopedics and radiologists understand this entity, become familiar with the imaging appearance in CT and discuss patient care procedures.

## Methods

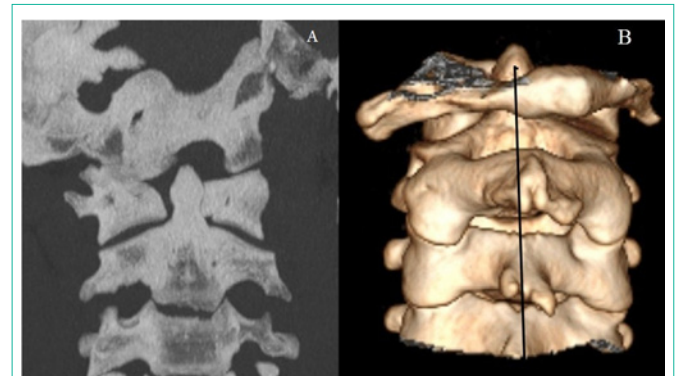This is a descriptive retrospective study conducted over 5 years (from January 1<sup>st</sup>, 2015 to December 31<sup>st</sup>, 2019) at our Traumatology Center. In this study, any polytrauma explored by a body scan or any adult, male or female that consulted for post-traumatic torticollis and explored by a cervical spine Computed Tomography (CT) scan with follow-up insured in the trauma center, was included. On the other side, patients whose CT images were not available or whose follow-up has not been ensure were excluded. All CT scans were performed using a GE 16 slices, with helical acquisition from C1-C2 to C7-T1 and 3D volumetric reconstructions.

All patients were followed for an average period of 6 months. The collection and analysis of all epidemiological and radiological data were carried out using IBM software: SPSS 20.

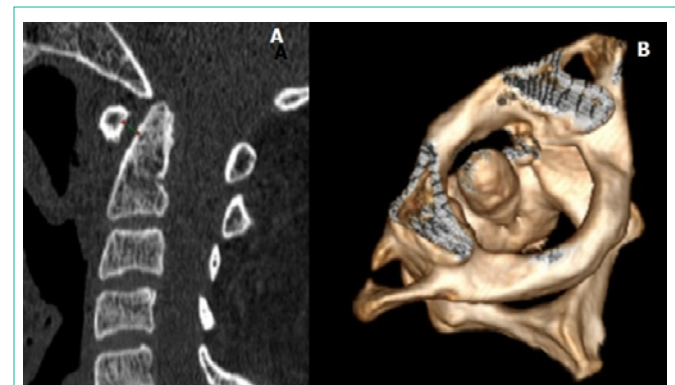## Results

Ten cases were diagnosed with an AARD; 5 men and 5 women. The average age was 34 with extremes ranging from 19 to 60. The causes of trauma were variable; most of the patients were victims of sports accidents.

Physical examination revealed a severe neck pain in all patients with irreducible torticollis and limitation of rotational movements in all directions. No neurological signs were noted. All patients underwent a cervical spine CT scan within 72 hours of the accident.



**Figure 1:** 23-year-old patient with irreducible torticollis following a suicide attempt by hanging. (A) Coronal reconstruction CT showed a rotatory dislocation type I with an asymmetric position of the odontoid on the lateral masses of C1. The left lateral mass appears closer to the midline than right lateral mass. In VR reconstruction (B) easy to detect lateral displacement of the spinous process of C1 on the spinal line.

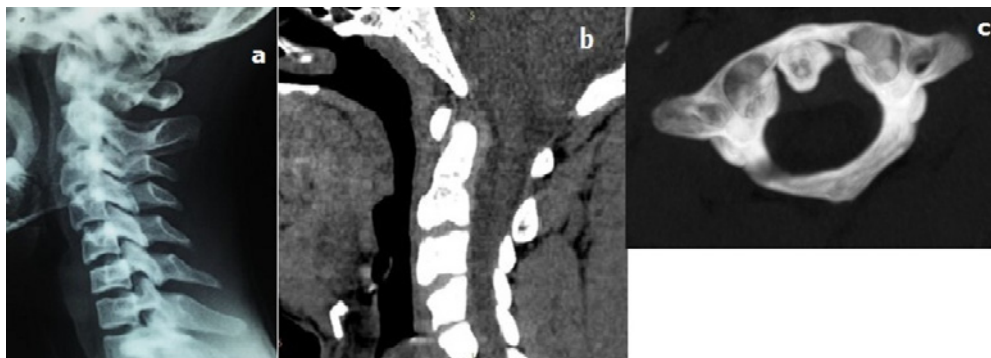


**Figure 2:** 19-year-old patient victim of fall in gymnastics. (A) Sagittal reconstruction CT showed atlantoaxial rotatory dislocation type IIA with anterior displacement of C1 over than 3mm. (B) A superior view in VR reconstruction confirms the rotational displacement of C1 on C2 with an eccentric position of the odontoid in the cervical canal.

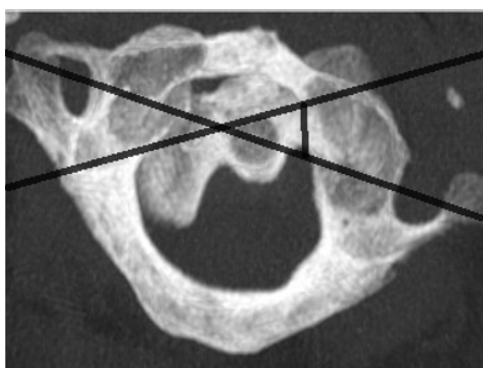
CT established the diagnosis of rotatory dislocation and demonstrated rotational displacement of the C1 on the C2 axis in all patients. According to the Fielding classification [2], there was 9 cases of LRAA type 1 (Figure 1), and only one case type IIA (Figure 2). No bone fracture was detected.

It is to note that realized standard radiography were not contributory. Only one radiography was interpretable and it was without anomaly (Figure 3).

Among 3 patients, manual reduction by gentle traction in the emergency room was performed successfully. In the remaining 7 cases, the reduction was under general anesthesia. After radiological verification of the reduction, cervical immobilization by various



**Figure 3:** (a) Profil X-ray of the cervical spine of a 23-year-old patient victim of sport accident after a roll: absence of C1-C2 diastasis. (b) CT shows soft tissues thickening around the odontoid. (c) The atlantoaxial rotatory dislocation was marked only on the MIP axial CT section showing the eccentric position of the odontoid.



**Figure 4:** Superposition of the CT axial section passing through the lateral masses of C1 and that passing through the body of C2 to specify the direction and the angle of rotation.

devices was performed over a period ranging from 6 to 8 weeks.

The outcome was good in all cases and no neurological complications were reported. Resumption of sports activity was authorized to 3 patients at six months follow-up after the termination of treatment. A patient with a type IIA rotatory dislocation did not tolerate the halo-cranien, requiring surgical treatment, so a posterior arthrodesis was put in place.

## Discussion

LRAA is a fixed rotational displacement of C1 on C2, secondary to a persistent decapitation between the lateral masses of the atlas and the odontoid. It was first described in 1907 by Corner [3]. It is a rare condition in the cranio-vertebral junction with only few cases reported in the English literature [4].

This entity is more frequently encountered in children, especially after a pharyngeal infection or a moderate cervical trauma. This priority for the child's spine is due to his physiological ligament hyperlaxity and horizontal orientation of the facet joints of the vertebrae [5]. On the contrary, in adults, it usually occurs after a violent high-energy trauma such as sports trauma, mechanical fall or by ejection. The mechanism of injury implicates a pure rotation of C1 around the pivot of the odontoid, with kinetic energy exceeding the elastic forces of the ligaments, which is sufficient to provoke the

breaking of the alar ligaments associated or not to the breaking of the transverse ligament [5].

The most common clinical sign is a severe neck pain that is often associated with irreducible torticollis. Neurological damage is rare but possible, ranging from mild nerve root irritation to fatal compression of the cord [6]. With our patients, no neurological symptoms were reported.

CT is considered as a gold standard, for diagnosis and classification of atlantoaxial rotatory dislocation that is able to detect characteristic features and to search for associated bone lesions [7]. In our series, CT allowed the diagnosis of AARD in all cases however, no fracture bone was found.

The most consistently positive diagnostic criterion on CT scan is the presence of an interval between C1 and C2, where there is merging two axial CT slices, one passing through the lateral masses of C1 and another through the body of C2. The measurement of intersection angle between these two lines allows to assess two reference data to evaluate the severity of the dislocation, which are rotation axis (odontoid or lateral mass) and degree of the anterior displacement of C1 on C2 (Figure 4). It is on these two data that the most widely used classification of Fielding and Hawking is based [2]. This classification is correlated to a potential instability by injury of transverse ligament and to a possible neurological complications depending on the type of dislocation. Types I and II are most common and most difficult to recognize on a standard x-ray. In our series, 9 cases of type I AARD were unrecognized on plain radiography.

Volumetric reconstructions in "Maximum Intensity Projection" (MIP) and "Volume Rendering" (VR) mode can help in diagnosis by detecting the eccentric position of odontoid between C1 lateral masses. However, the diagnosis of AARD should not be based on the mere appearance of the joint on a CT scan. Indeed, according to a study conducted by Riasco et al. on healthy volunteers, a physiological decapitation between C1 and C2 is possible in normal condition and it is variable follows on the degree of head rotation [8]. Hence, the need for coordination between vicious attitudes of the head in fixed rotation and CT data to retain the diagnosis.

Except that, a normal CT cannot in any case rule out the diagnosis of AARD and long ago, some authors proposed the realization of a

dynamic CT to check the fixity of the joint but this investigation was not performed [9].

Recently, MR imaging that has been reserved for cases of spinal cord compression and ligament injury is increasingly proposed as a valuable tool for diagnosing atlantoaxial instability [10].

Treatment management controversial gives the difficulty of achieving optimal stability and permanent reduction. The treatment of choice, if stability is confirmed and there is no neurological sign, is the conservative treatment, that should be considered first, consisting of manual reduction or under general anesthesia, followed by rigid cervical immobilization. When choosing the method of immobilization, the elasticity of the ligaments should be taken in consideration. In children, immobilization with a flexible collar for 6 weeks is sufficient, in adults; rigid cervical immobilization is recommended by the Halo vest for 2 to 3 months. In some cases, a rigid cervical collar could be used in place of the Halo vest with good outcomes [11]. In our series, the immobilization by a rigid cervical collar has been successfully used in 4 cases whereas failure of conservative treatment was noted in only one case immobilized by Halo vest.

Unfortunately, in our series, no MRI and no dynamic CT were performed, as the study was retrospective and all the patients were urgently admitted and managed. It would be interesting for the next studies to evaluate the two tools in order to improve the diagnosis and the management of this entity.

## Conclusions

Despite its rarity, post-traumatic AARD in adults should be kept in mind of clinicians to avoid diagnosis mistakes and prevent complications. An accurate diagnosis is based on confrontation on meticulous physical examination with computed tomography data. The measurement of the atlas-axis distance is a main pillar in diagnosis of atlanto-axial instability, that reflects the integrity or not

of the transverse ligament, which is the most important element of the therapeutic decision. Recently, MRI is increasingly proposed as a valuable tool for diagnosis and injury evaluation.

All authors have no conflict of interest.

## References

1. Sinigaglia R, Bundy A, Monterumic DA. Traumatic atlantoaxial rotatory dislocation in adults. *Chir Narzdw Ruchu Ortop Pol.* 2008; 73: 149-154.
2. Fielding JW, Hawkins RJ. Atlantoaxial rotatory fixation: fixed rotatory subluxation of the atlantoaxial joint. *J Bone Joint Surg Am.* 1977; 59: 37-44.
3. Giuseppe M, Eleonora M, and Silvio S. Posttraumatic Atlanto-axial Rotatory Dislocation in a Healthy Adult Patient: A Case Report and Review of the Literature. *Case Rep Orthop.* 2012: 183581.
4. Belli M, Hadhri K, Sridi M, Kooli M. Traumatic atlantoaxial rotatory fixation associated with C2 articular facet fracture in adult patient: Case report. *J Craniovertebral Junction Spine.* 2014; 5: 163-166.
5. García-P, Torres CV, Delgado J, Sola RG. Traumatic atlantoaxial rotatory fixation in an adult patient. *Eur Spine J.* 2017.
6. Tarantino R, Donnarumma P, Marotta N, Missori P, Viozzi I, Landi A, et al. Atlanto Axial Rotatory Dislocation in Adults: A Rare Complication of an Epileptic Seizure-Case Report. *Neurol Med Chir.* 2014; 54: 413-416.
7. Wang YF, Mu-Huo Teng M, Sun YC, Yuan WH, Chang CY. Torticollis due to atlantoaxial rotatory fixation. *J Clin Neurosci.* 2008; 15: 316-318.
8. Riascos R, Bonfante E, Cotes C, Guirguis M, Hakimelahi R, West C. Imaging of Atlanto-Occipital and Atlantoaxial Traumatic Injuries: What the Radiologist Needs to Know. *Radiographics.* 2015; 35: 2121-2134.
9. Atul Goel. Torticollis and rotatory atlantoaxial dislocation: a clinical review. *Journal of craniovertebral junction and spine.* 2019; 10: 77.
10. SC Hung, H-M Wu and W-H Guo. Revisiting Anterior Atlantoaxial subluxation with Overlooked information on MR Images. *American Journal of Neuroradiology.* 2010; 31: 838-843.
11. Dholakia A, Broyer Z, Conliffe A, Mandel S, Section Eds. Post-traumatic atlantoaxial rotatory Fixation in an adult Presenting as torticollis. *Practical Neurology.* 2012.