

Clinical Image

Anterior Dislocation of the Elbow Associated with an Olecranon Fracture: Exceptional Dislocation in Children

Badaoui R^{*}; Rachdi A; Boussaidan M; Benyass Y;
Boukhriss J; Benchaba D; Chafry B

Department of Traumatologie and Orthopedic II,
Military Hospital Mohammed V, Faculty of Medicine and
Pharmacy of Rabat, University Mohammed V. Rabat,
Morocco

***Corresponding author:** Badaoui R

Department of Traumatologie and Orthopedic II, Military
Hospital Mohammed V, Rabat, Morocco.
Email: joudbadaoui17@gmail.com

Received: November 09, 2023

Accepted: December 21, 2023

Published: December 28, 2023

Clinical Image

This is a 7-year-old child, victim of a fall a year ago, with landing on the right elbow in flexion. Clinical examination revealed a deformity of the elbow without a skin opening or vasculonerve lesions. X-rays of the elbow face and profile revealed an anterior dislocation of the elbow with fracture of the olecranon.

The child was given an open pit reduction and skewering of the olecranon. The development has been very favourable. Anterior elbow dislocation in children is an exceptional injury. It represents a real therapeutic emergency that involves the search for an associated lesion such as an olecranon fracture.

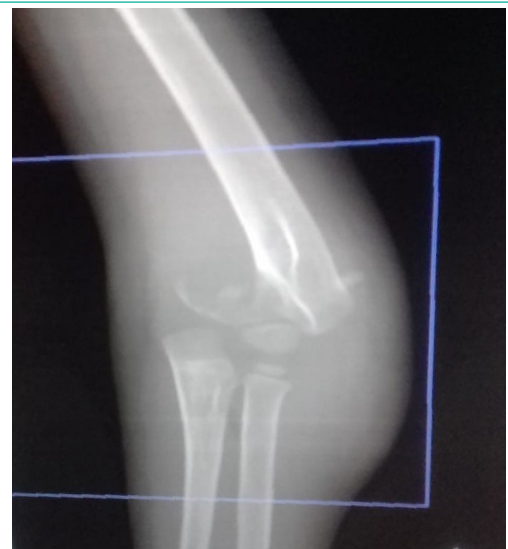

Figure 1: X-ray of the front of the elbow showing an anterior dislocation of the elbow with olecranon fracture.

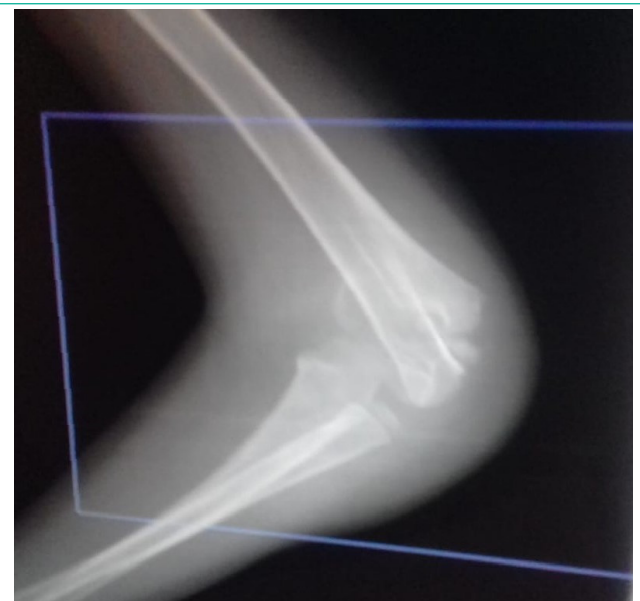


Figure 2: Side X-ray of the elbow showing anterior elbow dislocation with olecranon fracture.