

## Case Report

# Open Triple Disruptions of the Superior Shoulder Suspensory Complex: About a Rare and Controversial Injury

Chalouah B\*, Benchakroun M, El Mhadder M, Bennis A, Zaddoug O, Zine A and Bouabid S

Department of Orthopaedics-Traumatology I, Mohamed V Military Hospital, Morocco

\*Corresponding author: Chalouah B

Resident in Orthopaedics-Traumatology Surgery, Department of Orthopaedics-Traumatology I, Mohamed V Military Hospital, BP 10 100 Rabat, Morocco

Received: January 21, 2023; Accepted: March 01, 2023;

Published: March 08, 2023

## Abstract

The Superior Shoulder Suspensory Complex (SSSC) was introduced by Goss in 1993 as an osteoligamentous ring at the end of superior and inferior struts. This complex as a whole maintains a stable relationship between the upper extremity and the axial skeleton.

Traumatic disruptions of the SSSC can render the structure unstable and compromise the integrity of the complex leading to delayed union, malunion and nonunion, as well as adverse long-term functional limitations or persistent pain to the shoulder. However, the ideal treatment of this type of injury is still controversial with no consensus for best management.

We report the case of a 27 years old patient, who sustained a direct trauma to his right shoulder during a violent car accident, among other injuries, with an Ogawa type I coracoid fracture, a Kuhn type III acromion fracture and a mid-shaft clavicle fracture, causing an open triple disruption of the SSSC which we chose to address with a combined operative and non-operative management, with very satisfactory to excellent functional outcomes after only 8 weeks follow-up.

We believe that the SSSC is an osteoligamentous integrated system where fixing all disruptions is not necessary, sparing additional non-necessary interventions to patients sustaining usually multiple injuries. However, we are aware that large studies are needed to support this choice of strategy to manage such rare and complex injuries of shoulder girdle.

## Introduction

The Superior Shoulder Suspensory Complex (SSSC) was introduced by Goss in 1993 as an osteoligamentous ring at the end of a superior and inferior struts. The ring is composed of the glenoid process, the coracoid process, the Coracoclavicular (CC) ligaments, the distal clavicle, the Acromioclavicular (AC) joint and the acromion process. The superior strut is the middle clavicle while the inferior strut is the lateral scapular body/spine (Figure 5). This complex as a whole maintains a stable relationship between the upper extremity and the axial skeleton, allows limited motion to occur at the AC joint and CC ligaments and provide a firm attachment point for several soft tissue structures [1].

Traumatic disruption of one of the component of the SSSC are common and do not compromise the overall integrity of the complex significantly. However, if the ring fail at two or more places or a disruption of one portion of the ring associated with a fracture of one or both of the bony struts, it create a potentially unstable anatomic situation [1].

In this paper, we report the case of a 27 years old patient, who sustained a direct trauma to his right shoulder during a violent car accident, among other injuries, with an Ogawa type I coracoid fracture, a Kuhn type III acromion fracture and a mid-shaft clavicle fracture, causing an open triple disruption of the SSSC.

The ideal treatment of this type of injury is still controversial, between who prone to fix one component of the disrupted structures or to restore the integrity of all violated components [2]. In our understanding, we believe that Goss's SSSC is an osteoligamentous integrated system where fixing all disruptions is not necessary. In fact, as demonstrated with our case report, by fixing two disruption of the SSSC, the system has auto-corrected itself and the third injury was well reduced without intervention. Hence, we could have very satisfactory results with full recovery of ROM and with no persistent pain at only 8 weeks follow-up.

### Case Presentation

#### Clinical Presentation and Imaging Findings

A 27 year old man without previous shoulder injury was referred to our emergency centre after a high energy car accident. On admission, paramedics had immobilized the neck, applied a lower limb splint, pad the right shoulder wound and the arm was supported in a broad arm sling. The vital signs were normal. A body CT-scan showed no cranial, spine, thoracic or abdominal injuries. The splint and pad were removed revealing a shortened deformed right leg, a gustillo type I wound at the top of his right shoulder with loss of normal contour and abrasion (Figure 1). Physical exam revealed swelling and tenderness of the right shoulder with crepitation over its anterior aspect. Although, no definite neurovascular abnormalities of the right limbs were found, there were important range of motion limitation due to pain.

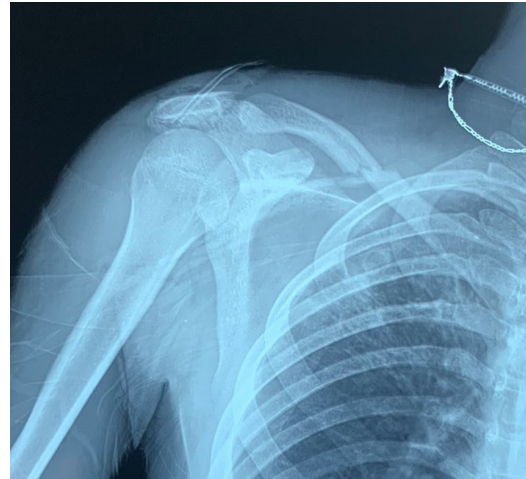
Plain radiographs of the right shoulder, right leg with above and below joints, revealed an Ogawa type I coracoid fracture, a Kuhn type III acromion fracture, a mid-shaft clavicle fracture (Figure 2) associated with a comminuted tibia and fibula fractures.

A right shoulder CT-scan with 3D bone reconstruction was realised to better understand fracture pattern and to plan surgical treatment. It showed an acromion fracture extending into spinoglenoid notch with significant narrowing of the subacromial space (Figure 3A), a displaced coracoid base fracture and a minimally displaced mid-shaft clavicle fracture (Figure 3B). The coracoclavicular distance was normal. Considering the patient's age and the radiographic evidence of multiple breaks of the SSSC, the decision to perform surgery was made after discussing the treatment options and risks with the patient.

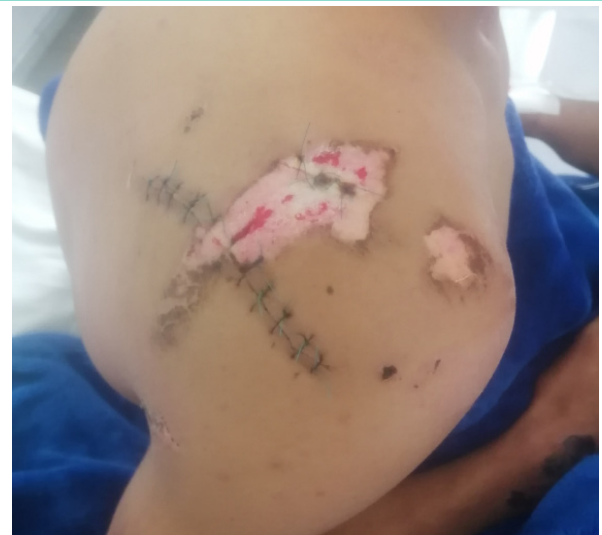#### Surgical Procedure

The surgery was performed under general anaesthesia 24 h after injury. First, the patient was placed in the leg free position for tibial nailing. We used an 11 mm / 38 cm titanium tibial nail under fluoroscopic guidance. Secondly, the patient was placed in true lateral position with the right arm draped free for movement during operation. An 8 cm incision was made along the scapular spine. After retraction of the posterior deltoid laterally, the acromion fracture was exposed. It was located at the junction of the acromion base and the lateral scapular spine, extending inferiorly into the spinoglenoid notch with narrowing of the subacromial space. ORIF of the acromion was performed with two 1.8 mm Kirschner wires and a figure 8 tension band wiring. Finally, we changed position of the patient once more into the beach-chair position to address the clavicle fracture with an S-shaped incision over its anterior border to expose the fracture site. ORIF of the clavicle was made with an anatomical 3.5 mm clavicle plate with 6 screws fixation. After achieving a

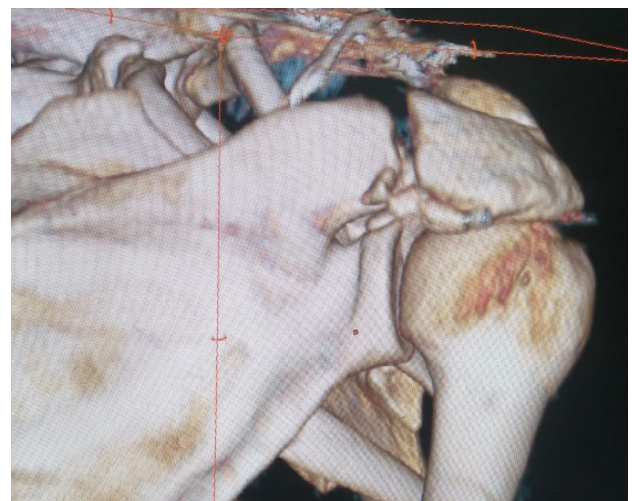good clavicle and acromial fixation tested under direct vision and fluoroscopic view, the coracoid process was satisfactorily reduced and stable without any other surgical step (Figure 4).



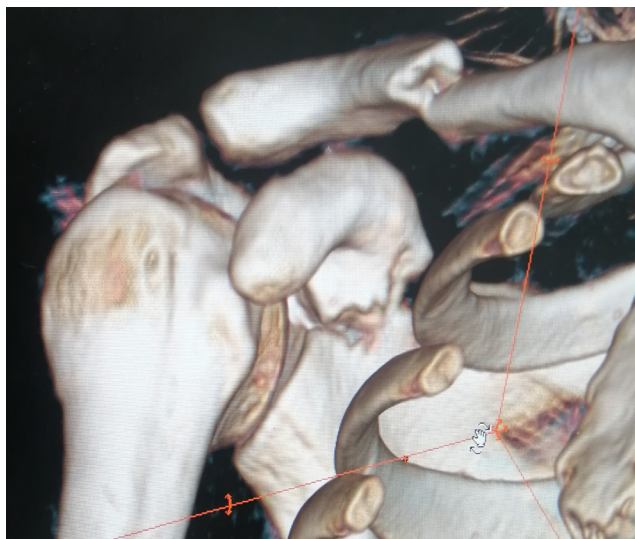
**Figure 1:** clinical image 2 weeks post-operatively showing scars of shoulder wound, dermabrasion at impact point and incision wound for acromion ORIF.



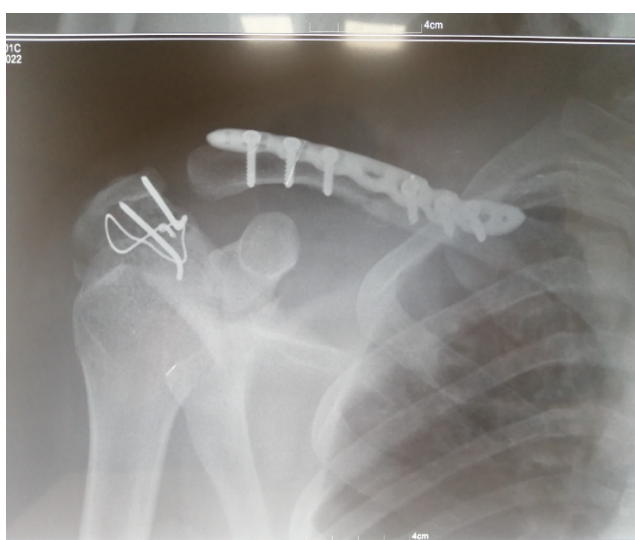**Figure 2:** Anteroposterior radiograph of the right shoulder showing triple disruption of the SSSC.



**Figure 3: A.** 3D-reconstruction image showing Kuhn type III acromion fracture associated with subacromial space narrowing.



**Figure 3: B.** 3D-reconstruction image showing Ogawa type I coracoid fracture and mid-shaft clavicle fracture with normal coracoclavicular distance.



**Figure 4:** postoperative radiograph.

### Postoperative Management

Postoperatively, the arm was supported in a broad arm sling for 2 weeks. Gentle passive range of motion activity under analgesic was encouraged from the second day postoperatively. The rehabilitation program consisted of Codman exercises and passive shoulder range of motion exercises for 4 weeks, followed by active range of motion exercises, which progressed to resistive exercises after 6 weeks.

### Discussion

The shoulder girdle includes three bones (scapula, clavicle, and proximal humerus), three joints (glenohumeral, acromioclavicular, and sternoclavicular), an additional articulation (scapulothoracic), and some 17 musculotendinous units. All these individual elements function in a synchronous and interdependent way to maximize the power and range of motion of the shoulder girdle for the main purpose of the upper limb, the grip function [3].

To understand this unique and particular interaction between all these elements, especially in traumatic context, we believe that the concept of Superior Shoulder Suspensory Complex (SSSC) introduced by Goss in 1993 is most accurate taking in consideration our case report.

The scapula provides vital components of the SSSC and high trauma injuries to the shoulder girdle has been reported to produce significant damage to this construct [4]. However, scapular fractures are rare, accounting for 1% of all fractures [5] with an increasing incidence in patients who sustain multiple injuries as our patient [6].

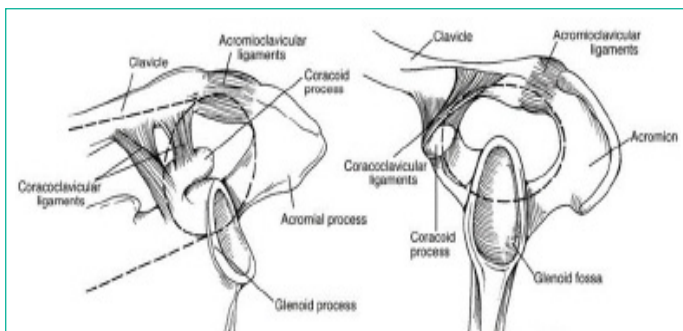
The SSSC is a ring-like combination of bone and ligaments, serving as the attachment of the upper extremity to the axial skeleton [1]. It is composed of six main structures: the glenoid, coracoid, coracoclavicular ligaments, clavicle, the acromioclavicular joint and ligaments and the acromion. The SSSC can also be divided into three component attachments: the acromioclavicular attachment, the coracoclavicular attachment, and the bony scapular body attachment of the acromion, glenoid, and coracoid (Figure 5). The clavicle serves as the primary and solitary bony attachment of the upper extremity to the thorax, acting biomechanically as a strut [7]. While the second strut is represented by the scapula (body/spine) which is a free flat bone, acting as a sesamoid bone trapped in the muscular cloth of the shoulder girdle, conferring the upper extremity its great mobility [8].

Often underestimated, the ligamentous structures in the shoulder girdle impart significant stability, and their disruption can create instability both with and without bony clavicle fractures. Williams et al. demonstrated in a cadaveric study that an artificial interruption of CC and AC ligaments led to greater instability of displaced fragments [9]. Therefore, radiological assessment of multiple disruptions of the SSSC must search for indirect signs of ligamentous lesions such as an increase of the CC distance and/or an AC dislocation. These two signs were negative for our patient.

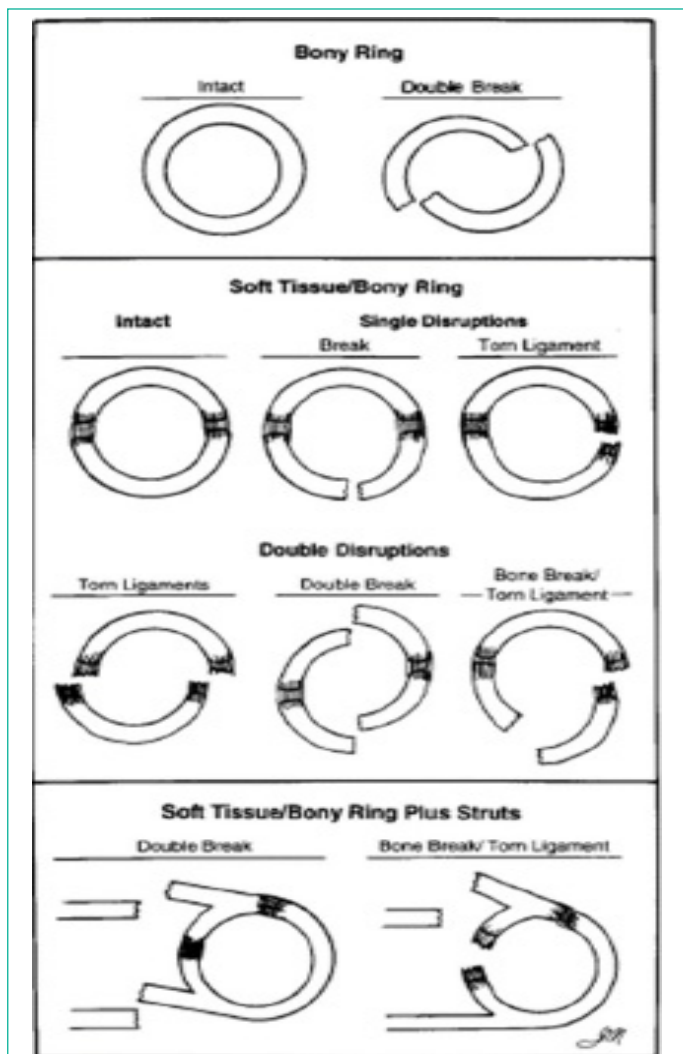
The “double-disruption” concept explains how a single injury can be fairly well-tolerated, while injury in two separate areas of the ring can render the structure unstable (Figure 6) [7]. This double disruptions destabilize the SSSC ring and are susceptible to delayed union, malunion and nonunion, as well as adverse long-term functional limitations or persistent pain to the shoulder [10-14].

Thus, double breaks of the SSSC usually require operative treatment to regain stability of the system [1,4,10,11,14-16]. Triple or more Disruptions of the SSSC during a single trauma are extremely rare events and only a few case reports have described this type of injury [5,17-21] with no consensus for best management. This disparity in surgical management of these types of injuries of the shoulder girdle is, in our understanding, primarily explained by their rarity, the complexity of shoulder anatomy and biomechanics associated with the variety of possible injury combinations, making it difficult to conduct large scale studies and to establish protocols for best management of scapular girdle trauma.

For our patient, we conducted an open reduction and internal fixation for the acromion and clavicle injuries, while the coracoid was managed non-operatively. This choice of combined operative and non-operative management was made out of our belief that the SSSC is an osteoligamentous integrated system where fixing all disruptions is not necessary, sparing additional non-necessary interventions to patients sustaining usually multiple severe life-menacing injuries, with very satisfactory to excellent functional outcomes as observed with our patient after only 8 weeks follow-up (Figure 7A, B, C, D).



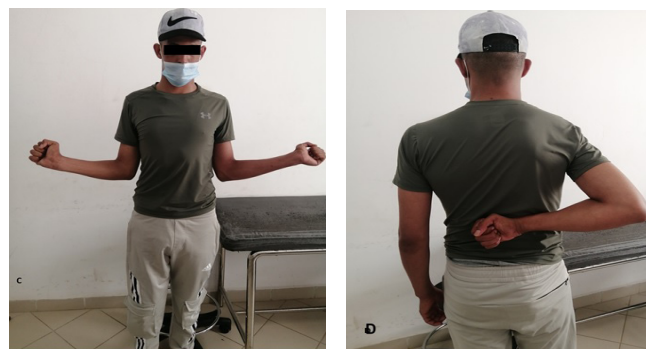**Figure 5:** Illustration depicting the SSSC. A: an anteroposterior view of the bony/soft tissue ring and superior and inferior struts. B: a lateral view of the bony/soft tissue ring [1].



**Figure 6:** illustration depicting traumatic ring/strut disruption [1].



**Figure 7:** A: Antepulsion B: Abduction;



C: External Rotation; D: Internal Rotation  
**Figure 7:** Images showing functional outcome at 8 weeks follow-up.

### Conclusion

It is clear and even careless to adopt a management strategy of such complex injuries as multiple disruptions of the SSSC after one good result. However, we think that our strategy to manage this case report finds solid anatomical and biomechanical arguments that expands from Goss's concept of the SSSC and our understanding of the shoulder girdle, particularly in traumatic context. That is why, we believe that more studies with large series of patients with multiple disruptions of the SSSC are necessary for better understanding of this type of injuries, precise case definition, and thus establishing protocols for best management of multiple disruptions of the superior shoulder suspensory complex.

### Statement of Ethics

The consent for publication of the case (including images) was obtained from the patient.

### Conflict of Interest Statement

The authors have no conflicts of interest to declare.

### Funding Sources

The authors did not receive any funding.

### Author Contributions

CHALOUAH Badr: conception and design of the work; acquisition, analysis, interpretation of the data; drafting the work.

BENCHAKROUN Mohammed: conception and design of the work; drafting the work.

EL MHADDER Mohsine: acquisition; Interpretation of the data

BENNIS Azzelarab: analysis and interpretation of the data;

ZADDOUG Omar: analysis and interpretation of the data;

ZINE Ali: analysis and interpretation of the data; Critical revision

BOUABID Salim: analysis and interpretation of the data; critical revision of the manuscript for important intellectual content.

### References

- Goss TP. Double Disruptions of the Superior Shoulder Suspensory Complex, *Journal of Orthopaedic Trauma*. 1993; 7: 99-106.
- Hashiguchi H, Ito H. Clinical outcome of the treatment of floating shoulder by osteosynthesis for clavicular fracture alone. *J Shoul-*

- der Elbow Surg. 2003; 12: 589–591.
3. Essentials of Orthopedic Surgery Third Edition Edited by Sam W. Wiesel, MD ISBN-10: 0-387-32165-9 ISBN-13: 978-0387-32165-3, 2007 Springer Science+Business Media, LLC.
  4. Mulawka B, Jacobson AR, Schroder LK, Cole PA. Triple and quadruple disruptions of the superior shoulder suspensory complex. *J Orthop Trauma*. 2015; 29: 264–270.
  5. Wu K, Wu XM, Zha XL, Wang QG. Anatomic Restoration of Triple Disruption of the Superior Shoulder Suspensory Complex: A Case Report and Review of the Literature. *Orthop Surg*. 2020; 12: 1526-1530.
  6. Ada JR, Miller ME. Scapular fractures. Analysis of 113 cases. *Clin Orthop*. 1991; 269: 174–180
  7. R. Michael Greiwe, In Woodhead Publishing Series in Biomaterials, Shoulder and Elbow Trauma and its Complications, Woodhead Publishing. 2015; 473-483.
  8. Michel Dufour; Michel Pillu; *Biomécanique fonctionnelle*; 2017, Elsevier Masson SAS. Tous droits réservés ISBN : 978-2-294-75093-9 e-ISBN : 978-2-294-75198-1 Elsevier Masson SAS, 65, rue Camille-Desmoulins, 92442 Issy-les- Moulineaux cedex
  9. Williams GR, Naranja J, Klimkiewicz J, Karduna A, Iannotti J, et al. The floating shoulder: a biomechanical basis for classification and management. *J. Bone Joint Surg Am*. 2001; 83-A: 1182–1187.
  10. Goss TP. Scapular fractures and dislocations: Diagnosis and treatment. *J Am Acad Orthop Surg*. 1995; 3: 22–33
  11. Ogawa K, Matsumura N, Ikegami H. Coracoid fractures: therapeutic strategy and surgical outcomes. *J Trauma Acute Care Surg*. 2012; 72: E20-6.
  12. Oshima M, Nakagawa Y, Mondori T. Complex injury patterns of the shoulder girdle-three or four-site injury. *Shoulder Joint*. 2003; 27: 555–559.
  13. Zilberman Z, Rejovitzky R. Fracture of the coracoid process of the scapula. *Injury*. 1981; 13: 203-6.
  14. Cain TE, Hamilton WP. Scapular fractures in professional football players. *Am J Sports Med*. 1992; 20: 363-5.
  15. Kim SH, Chung SW, Kim SH, Shin SH, Lee YH. Triple disruption of the superior shoulder suspensory complex. *Int J Shoulder Surg*. 2012; 6: 67–70.
  16. Anavian J, Wijdicks CA, Schroder LK, Vang S, Cole PA. Surgery for scapula process fractures. *Acta Orthop*. 2009; 80: 344–350.
  17. Lecoq C, Marck G, Curvale G, Groulier P. Triple fracture of the superior shoulder suspensory complex. *Acta Orthop Belg*. 2001; 67: 68–72.
  18. Badam VK, Harsha TSS, Sankineani SR, Rachakonda KR, Bodanki C, et al. Triple disruption of the superior shoulder suspensory complex – a case report. *J Orthop Case Rep*. 2019; 9: 39–42.
  19. Krticka M, Petras M. Ipsilateral fractures of the coracoid and acromion process of the scapula combined with the distal clavicle end fracture, treatment options Ipsilateral fractures of the coracoid and acromion process of the scapula combined with the distal clavicle end fracture, treatment options. *Acta Chir Orthop Traumatol Cech*, 2019, 86: 299–303
  20. Tamimi Marino I, Martin Rodriguez I, Mora Villadeamigo J. Triple fracture of the shoulder suspensory complex. *Revista Espanola de Cirugia Ortopedica y Traumatologia*, 2013, 57: 371–374.
  21. Oh W, Jeon IH, Kyung S, Park C, Kim T, et al. The treatment of double disruption of the superior shoulder suspensory complex. *Int Orthop*. 2002; 26: 145-9.