

Clinical Image

Mirrored Aneurysmal Bone Cyst Around the Knee

Boussaidane M*, Boukhriss J, Chafry B, Benchebba D and Boussouga M

Department of Traumatology and Orthopedics, Military Hospital Mohammed V, Faculty of Medicine and Pharmacy of Rabat, University Mohammed V, Rabat, Morocco

***Corresponding author:** Boussaidane Mohammed, Department of Traumatology and Orthopedics, Military Hospital Mohammed V Rabat, Morocco

Received: November 08, 2021; **Accepted:** December 29, 2021; **Published:** January 05, 2022

Clinical Image

The aneurysmal bone cyst is a benign pseudotumor that often arises off the center of the long bones metaphysis and which as it grows can blow out the bone. The most widespread etiopathogenic theory is that of a reaction process to a venous malformation but the neoplastic theory is currently being discussed since the discovery of the translocation t (16; 17) (q22; p13) which is recurrent in primary aneurysmal cysts. We report here the case of a 26-year-old patient without medical history, who consults for pain in the right knee with partial functional impairment. The radiological assessment showed an osteolytic mirror image at the metaphyseal level of the lower end of the femur and the upper end of the tibia with thinned cortices exposing the high risk of fracture (Figure 1). A biopsy made confirms the diagnosis of the aneurysmal cyst. The patient underwent curettage with bone grafting.

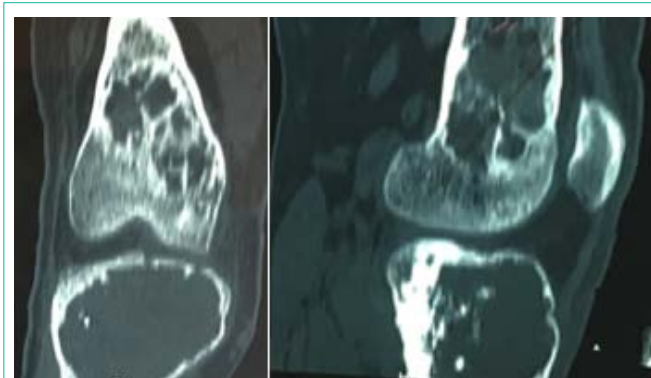


Figure 1: CT sections showing a mirror image of heterogeneous osteolysis at the epiphyso-metaphyseal level of the lower end of the femur and the upper end of the right tibia.