

Case Report

Purulent Infection in a Native Adult Hip with Healed Perthe's Disease: A Rare Presentation

Raval P* and Abbas A

Department of Orthopedics, Wishaw General Hospital, UK

***Corresponding author:** Mr. Pradyumna Raval, Department of Orthopedics, Wishaw General Hospital, Scotland, UK**Received:** September 23, 2019; **Accepted:** October 23, 2019; **Published:** October 30, 2019**Abstract**

Septic arthritis of a joint is one of the few orthopedic emergencies wherein a prompt diagnosis and early intervention is warranted in order to prevent any further joint destruction. Septic arthritis of hip has a dramatic presentation in the pediatric population, but is relatively unheard of in adults. In the few adult patients who present with septic arthritis of native hip joint, an underlying comorbidity like rheumatoid arthritis or diabetes is frequently present. We present an extremely rare case of a purulent septic arthritis in a healthy individual with healed Perthes disease; which was successfully treated with open arthrotomy.

Keywords: Perthe's disease; Hip; Purulent; Infection**Case Presentation**

A 47-year-old gentleman, Heavy Goods Vehicle (HGV) driver by occupation, presented to our Emergency Department (ED) with a one day history of sudden onset left hip pain. There was no history of any antecedent trauma. This person was well built and had no comorbidities. He was diagnosed with Perthes disease of his left hip and underwent an osteotomy for the same as a child. Subsequent implant removal was performed, with him being absolutely asymptomatic till this particular presentation.

Initial blood investigations revealed a high C - reactive protein (CRP) value of 76 mg/L and an elevated WBC count with neutrophilia. Radiographic investigations were inconclusive (Figure 1). In the next 24 hours the CRP value almost doubled to 146 mg/L and WBC continued to rise. An urgent ultrasound scan revealed a collection around the left hip (Figure 2). An arthrotomy was performed as an emergency using the anterolateral approach. Frank purulent material was obtained from the left hip which was sent for microbiological evaluation.

Following the procedure there was a dramatic improvement in the general condition of the patient. This was corroborated by the normalization of the WBC and CRP value, which fell to 58 mg/L post operatively. No organism was isolated on the culture report. The patient was pre-emptively kept on intra-venous flucloxacillin after

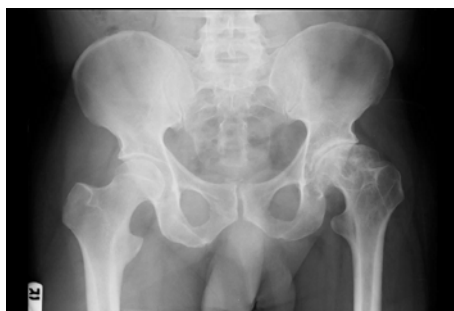

Figure 1: Initial Pelvis with Hip antero-posterior radiograph showing healed Perthes disease with advanced arthritis of left hip joint.

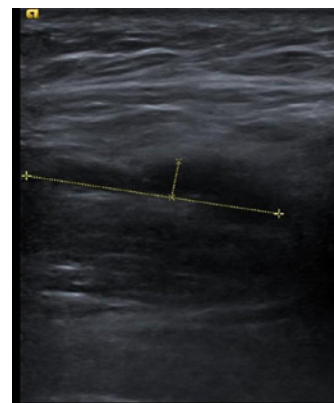


Figure 2: Ultrasound image of collection in the left hip.

consultation with microbiologist. An extended culture report also did not isolate any microorganism.

The patient received intra-venous antibiotics for four weeks and was thereafter discharged on oral antibiotics. Serial CRP monitoring was performed on an outpatient basis till a normal value was attained. On subsequent follow up over a period of six months, this patient had symptoms of left hip pain. After a fresh set of investigations were normal, it was decided to perform a Total Hip Arthroplasty (THA). An un-cemented THA was performed (Figure 3) and the patient remained asymptomatic on his subsequent follow-ups at six months and one year.

Discussion

Septic arthritis of a native hip joint is extremely rare with an incidence of 2 to 10 per 100,000 person years [1]. A multicenter study involving 6 orthopedic departments over a span of 18 years could identify only 18 cases[2], similarly a 12 year retrospective review identified 20 patients in a catchment area of 600,000 [3]. Most patients diagnosed with septic arthritis of native hip have significant underlying co-morbidities such as rheumatoid arthritis, diabetes mellitus, intra-venous drug abuse and low socio-economic status [4,5].

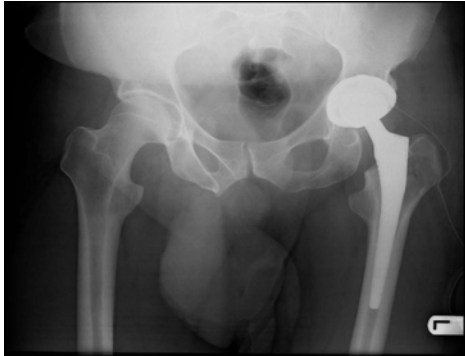


Figure 3: Post-operative radiograph of left un-cemented total Hip Arthroplasty.

The presenting symptoms are pain, restricted joint motion and raised temperature. Inflammatory markers such as CRP and WBC count are often markedly raised on presentation [3,5]. Initial radiologic investigation may not reveal any pathology especially in patients presenting acutely with a shorter duration of symptoms [2]. Synovial fluid culture may help in isolating the causative microorganism, which is *Staphylococcus aureus* in most cases [2-5]. However, Methicillin-Resistant *Staphylococcus aureus* has been shown to cause fatal septic arthritis of a native hip joint [6].

Open debridement is the preferred treatment in cases of septic arthritis and no significant difference has been noted between open and arthroscopic debridement [5]. In rare instances where no microorganism is identified on synovial fluid culture, a subsequent open debridement may reveal a purulent infection, which establishes the diagnosis of septic arthritis [2]. We had a similar experience wherein purulent material was discovered on open debridement.

Early diagnosis and treatment is mandatory to avoid any subsequent damage of the joint. It has been shown that a delayed presentation of more than three weeks may ultimately need an excision arthroplasty [3]. Similarly, a single surgical debridement

may not be sufficient especially in adults with an underlying inflammatory arthropathy, large joint involvement, diabetes mellitus and *Staphylococcus aureus* as a causative organism [5].

Although culture negative cases of septic arthritis have been reported in literature, there has always been an underlying comorbidity such as rheumatoid arthritis, diabetes mellitus or immunocompromised state in patients with septic arthritis of native hips. We did not come across any case in literature of culture negative purulent septic arthritis in a healthy adult with a healed Perthes disease.

Conclusion

Septic arthritis of a native hip joint in an adult is very rare and may not always present with the usual underlying co-morbidities. Excellent result can be expected where prompt decision is taken based on clinical judgement especially in cases with ambiguous investigative results as is evident in this rare case.

References

1. Chen CE, Wang JW, Juhn RJ. Total hip arthroplasty for primary septic arthritis of the hip in adults. *Int orthop*. 2008; 32: 573-580.
2. Muñoz-Mahamad E, Pons M, Matamala A, Tibau R, Puig L, Cordero-Ampuero J, et al. Hematogenous septic arthritis of the hip in adult patients. *Am J Emerg Med*. 2012; 30: 630-631.
3. Matthews PC, Dean BJ, Medagoda K, Gundle R, Atkins BL, Berendt AR, et al. Native hip joint septic arthritis in 20 adults: delayed presentation beyond three weeks predicts need for excision arthroplasty. *J Infect*. 2008; 57: 185-190.
4. Mathews CJ, Weston VC, Jones A, Field M, Coakley G. Bacterial septic arthritis in adults. *Lancet*. 2010; 375: 846-855.
5. Hunter JG, Gross JM, Dahl JD, Amsdell SL, Gorczyca JT. Risk factors for failure of a single surgical debridement in adults with acute septic arthritis. *J Bone Joint Surg Am*. 2015; 97: 558-564.
6. Fangtham M, Baer AN. Methicillin-resistant *Staphylococcus aureus* arthritis in adults: case report and review of the literature. *Semin Arthritis Rheum*. 2012; 41: 604-610.