

Research Article

Pressure Results of Primary Open-Angle Glaucoma Surgery by Trabeculectomy in Kankan, Guinea

Sovogui Md^{1,2*}; Zoumanigui²; Doukoure MB²; Camara F³; Vonor K⁴

¹Faculty of Health Sciences and Techniques, University of Conakry, Republic of Guinea

²Bartimee Ophthalmological Clinic, Republic of Guinea

³Kankan Regional Hospital, Republic of Guinea

⁴University of Kara in Togo, Republic of Guinea

*Corresponding author: Maxime Dantouma SOVOGUI

Assistant at the Faculty of Health Sciences and Techniques, Gamal Abdel Nasser University. BP: 2525 Conakry, Republic of Guinea.

Tel: +224 628 17 93 23

Email: maximesovo79@gmail.com

Received: July 05, 2023

Accepted: August 08, 2023

Published: August 15, 2023

Introduction

Glaucoma is a group of progressive and degenerative optic neuropathies with irreversible loss of visual field (CV) and can lead to blindness [1]. Intraocular hypertension is the main risk factor. Diagnosis and monitoring are based on a joint analysis of structural involvement by clinical examination of the papilla supplemented by Optical Coherence Tomography (OCT) and functional impairment, by the realization of CV. Treatment consists of reducing Intraocular Pressure (IOP), thus slowing the progression of the disease, through medical, physical (laser) treatments and surgical [2]. Surgery is the most effective way to lower IOP. It is usually offered when the maximum tolerated medical treatment is insufficient to achieve a target IOP. Many incisional techniques of variable mode of action facilitate the evacuation of aqueous humor out of the anterior chamber. Some make it possible to remove the trabecular obstacle in whole

(trabeculectomy) or in part (deep non-perforating sclerectomy) and others (micro invasive) try to restore the physiological flow of aqueous humor by trabecular and / or uveoscleral route. Trabeculectomy is a reference technique but depends on a filtration bubble and its complications requiring very rigorous and prolonged monitoring for life. The failure of this technique is almost always due to the healing of the conjunctiva and Tenon capsule [3]. In Ireland in 2020, in a study of trabeculectomy with the use of Mitomycin C, IOP was 10.8 ± 4.8 mm Hg representing a 47% reduction in IOP from baseline [4]. In the Democratic Republic of Congo in 2017, after trabeculectomy associated with anti-VGEF in the management of neovascular glaucoma, the mean IOP of 38 mm Hg preoperatively, increased to 15 mm Hg postoperatively [5]. In Togo in 2017, Maneh et al [6] reported in a study of trabeculectomy outcomes in childhood glaucoma,

Summary

Purpose: To assess the pressural outcomes of primary open-angle trabeculectomy surgery for primary open-angle glaucoma.

Materials and Methods: This was a six-month prospective observational study. Patients operated by the trabeculectomy technique and followed during the study period were included. Not included were those who had combined surgery. Recruitment was comprehensive. Our variables were epidemiological, clinical, para-clinical and therapeutic. Epi info version 7.4.0 was used for data analysis.

Results: Of 2401 patients, 47 were received, of which 79 eyes were successful, i.e. 1.95%. Postoperative intraocular pressure at D30 was between 10 mm Hg and 21 mm Hg in 91.1% of cases. Indications for surgery were dominated by poor therapeutic compliance, i.e. 31.9%. Mean age 41.88 ± 24.98 years and sex ratio 1.61. Decline in visual acuity was the common reason in 36 cases, or 76.6%. Both eyes were operated at the same time in majority, 64 cases or 81.0%. Visual acuity from afar without correction $\geq 3/10$ was dominant, i.e. 48.6%. The preoperative intraocular pressure was >21 mm Hg in 64.6%; the visual field achieved in 70 patients was altered to -12 decibels in the majority, i.e. 47.1%; Optical coherence tomography is performed in 72% of patients, showed a thinning of the neuro-retinal fibers to 88 μ m in 74%, with severe damage to the optic disc in 61.4%.

Conclusion: Glaucoma remains a public health problem in Kankan. Trabeculectomy concluded an overall success in lowering post-operative intraocular pressure with almost no complications. Given these results, it would be better to undertake it in 1st intention.

Keywords: Glaucoma; Trabeculectomy; Guinea

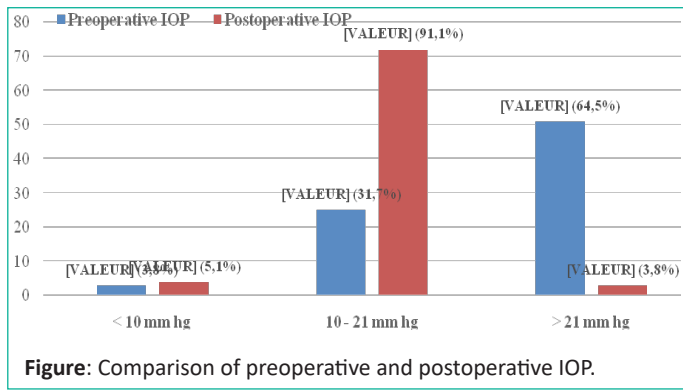


Figure: Comparison of preoperative and postoperative IOP.

that the mean preoperative IOP was 20.08 mm Hg increasing to 12.86 mm Hg, 6 months later with 62.86% success. In the Republic of Guinea, Sovogui MD et al. [7] in their study of Non-Perforating Deep Sclerectomy (NPPS), report that the mean preoperative IOP was 19±5.73 mm hg versus 11.6±1.86 mm hg on postoperative Day 30. However, it seemed interesting to us to evaluate the functional results of Trabeculectomy at Kankan Regional Hospital.

Table 1: Operative indications.

Directions	Effective	Percentage
Poor therapeutic compliance	15	31,9
Financial difficulty	13	27,7
Worsening of the visual field	10	21,3
1 st line surgery	8	17,0
Therapeutic failure	1	2,1
Total	47	100

Table 2: Socio-demographic variables.

Variable	Effective	Percentage
Age in year		
0–20 ans	8	17,0
21–40	7	14,9
41–60 ans	17	36,2
≥60	15	31,9
Sex		
Male	29	61,7
Female	18	38,3

Table 3: Clinical variables.

Variable	Effective	Percentage
Reasons for consultation (47)		
Decreased visual acuity	36	76,6
Eye pain	32	68,1
Headache	27	57,5
Tearing	24	51,1
Visual blur	17	36,2
Photophobia	13	27,7
Megalocornea	5	10,6
Buphthalmos	3	6,4
Corneal opacity	2	4,3
Histry (N=47)		
Ophthalmological myopia	2	4,3
Medical		
High blood pressure	23	48,9
Diabetes	17	36,2
Family history of glaucoma	4	8,5
No history	16	34,0
Laterality (N=79)		
Right/left eye	64	81,0
Left eye	9	11,4
Right eye	6	7,6

Table 4: Visual acuity from afar without preoperative correction (N=47).

Visual acuity	Right eye		Left eye	
	Effective	Percentage	Effective	Percentage
<1/10	10	21,3	12	25,5
1/10-2/10	9	19,1	10	21,3
≥3/10	23	48,9	21	44,7
Visual acuity not done	5	10,7	4	8,5
Total	47	100	47	100

Table 5: Paraclinical variables.

Variable	Effective	Percentage
Fiber thickness at OCT-RNFL (N = 94)		
<88µm	42	44,7
88-153µm	21	22,3
Non réaliser	31	33,0
OCT-DDLS (N = 94)		
01–04 (Normal)	3	3,2
05–06 (Moderate impairment)	19	20,2
07–10 (severe impairment)	41	43,6
Not realized	31	33,0
Mean Defect (N=94)		
MD <-6 dB	10	10,6
MD <-12 dB	22	23,4
>-12 dB	31	33,0
Not realized	31	33,0

Materials and Methods

This was a six-month prospective observational study from 01 March 2022 to 31 August 2022. It took place in the ophthalmology department of Kankan Regional Hospital and the Nabaya Yelen application center in Kankan. Due to their administrative positions and equipment, they are the largest ophthalmology departments in the Kankan administrative region. Patients operated by the trabeculectomy technique and followed during the study period were included in this study. Not included were those who received combined surgery (cataract-glaucoma). The recruitment was exhaustive according to our selection criteria. Our variables were epidemiological, clinical, paraclinical and therapeutic. Epi info version 7.4.0 was used for data analysis; Word and Excel software from the Office 2016 pack were used for text and table entry; Zotero version 5.0.96.2 was used for bibliographic references. The confidentiality and anonymity of interviewees were respected in accordance with the principles of ethics and medical deontology.

Results

In all, 2401 patients including 47 patients were received in whom 79 eyes were operated for glaucoma by the technique of Trabeculectomy, a frequency of 1.95%. The figure below shows the considerable normalization of IOP postoperatively, compared to preoperative IOP. Table I shows that poor compliance with treatment was the most frequent operative indication. Table II shows that the 41-60 age group is more represented with a male predominance. Average age 41.88±24.98 extreme years 1 month and 76 years; Sex ratio 1.61. Table III on clinical variables shows that decreased visual acuity was the most common reason, high blood pressure (hypertension) was the most dominant antecedent. Both eyes were more affected at the same time. In Table IV, visual acuity by far without carried correction (AVLSC) ≥3/10 was the most dominant. According to Table V shows that, the optical fiber thickness at OCT-RNFL was < 88µm plus severe optical disc damage in the majority of cases. On the CV, the Mean Defect was > -12 dB in almost half of the cases. The only complication found postoperatively in this study was hyphema, encountered in only one patient.

Discussions

This study allowed us to demonstrate the effectiveness of Trabeculectomy by a considerable standardization of postoperative IOP in this series of studies, compared to preoperative IOP. It indicates that poor compliance with treatment as well as financial difficulties related to the purchase of anti-glaucomatous drugs were the main surgical indications. It has the advantages of being prospective and having a single surgeon with

mastery of the technique used, who has operated on all patients. However, the main limitation was the non-performance of paraclinical examinations by some patients, due to lack of financial means and lack of support from a mutual health insurance company. The success of this technique is confirmed by Kabesha TB et al [5], who report that the average IOP increased from 38 mm Hg preoperatively to 15 mm Hg postoperatively. The frequency of glaucomatous patients who have benefited from the Trabeculectomy technique in the Ophthalmology Department and the Nabaya Yelen Application Center in Kankan, is 1.95% with a male predominance and an average age of 41.88 ± 24.98 years. Sovogui MD et al [7] in their study at the Bartimaus Ophthalmological Clinic in Conakry, Guinea report similar results, an average age of 45.20 ± 14 years with a sex ratio of 1.21. Table III on clinical variables shows that decreased visual acuity was the most common reason, hypertension was the most dominant antecedent followed by diabetes, and both eyes were more affected at the same time. Kabesha TB et al. [5] report identical results from history, as well as Sovogui MD et al [7] in relation to the reasons for consultations. According to the Swiss Society of Ophthalmology, the first sign of glaucoma is the loss of peripheral vision and CV damage which is noticed only at an advanced stage of the disease when central vision is affected [8]. This explains the results in relation to visual acuity from afar without correction of the patients in this series. As for Table V, the thickness of optical fibers at OCT-RNFL was $< 88 \mu\text{m}$ mostly associated with severe damage to the optical disc. On the CV, the Mean Defect was > -12 dB in almost half of the cases. These results are explained by the insidious nature of the disease, manifested by a progressive loss of retinal ganglion cells, morphological changes in the head of the optic nerve and typical visual field involvement [9].

Conclusion

Glaucoma remains a public health problem in Kankan. Trabeculectomy concluded an overall success in lowering intraocular pressure after a one-month setback with almost no complications. Given the effectiveness of this technique, it would be better to undertake it in first intention among Kankan populations.

Author Statements

Conflicts of Interest

The authors do not declare any conflicts of interest in relation to this work.

Author's Contributions

Authors contributed to one or more levels of manuscript writing since protocol, data collection, and writing. All have read and approved the manuscript.

References

1. Institut national d'excellence en santé et en services sociaux (INESSS). The XEN45 gel implant for micro-invasive glaucoma surgery (MIMC). Review by Luc Cloutier, Rania Saidi, François Désy. Québec, Qc: INESSS. 2020; 46.
2. Bertaud S, Aragno V, Baudouin C, Labbé A. Primary open-angle glaucoma. *Rev Med Interne*. 2019; 40: 445-52.
3. Hamard P. Surgical treatment of open-angle glaucoma. *JFO*. 2016; 13: 44437-5.
4. Sharpe R, Pham G, Chang P. Comparison of ab interno XEN gelatin stent vs trabeculectomy with Mitomycin C: A retrospective study. *J Curr Glaucoma Pract*. 2020; 14: 87-92.
5. Kabesha TB, Kabesha D, Maloba V, Mwamba C, Chenge B, Mukalay A. Results of trabeculectomy associated with anti-VEGF in the treatment of neovascular glaucoma complicating retinal vein occlusions (about 21 cases, followed at the eye clinic of Bukavu from 1 January to 31 December 2015). *J Fr Ophtalmol*. 2017; 40: 17-21.
6. Maneh N, Vonor K, Diatewa BM, Batomaguela NSK, Amedomé KM, Nagbe YE, et al. Results of trabeculectomy in infantile glaucoma at the CHU campus of Lomé (Togo). *Eur Sci J ESJ*. 2017; 13: 119.
7. Sovogui MD, Baldé R, Zoumanigui C, Grovogui MM, Vonor K, Mermoud. Surgery for chronic glaucoma by the technique of non-perforating deep sclerectomy at the Bartimée ophthalmological clinic: about 50 cases. *Acta Sci Sci*. 2022; 6: 27-31.
8. Swiss Society of Ophthalmology. Glaucoma [cited Jun 11, 2023]. Available from: <https://www.sog-ssso.ch/fr/pour-patientes/glaucome.html>.
9. Classification and terminology. In: European glaucoma society terminology and guidelines for glaucoma. 4th ed. Genova: Publi-Comm. 2014; 79.