

Case Report

Subthreshold Yellow Wavelength Micropulse Laser Photostimulation Treatment in a Patient with Suspected Polypoidal Choroidal Vasculopathy

Işık MU^{1*}, Değirmenci MFK² and Sağlık A¹¹Department of Ophthalmology, Faculty of Medicine, Kastamonu University, Turkey²Department of Ophthalmology, Çankırı State Hospital, Turkey***Corresponding author:** Mehmed Uğur Işık, Department of Ophthalmology, Faculty of Medicine, Kastamonu University, Turkey**Received:** June 21, 2021; **Accepted:** July 09, 2021;**Published:** July 16, 2021**Abstract****Purpose:** The aim is to discuss the efficacy of micropulse laser treatment in a patient suspected of polypoidal choroidal vasculopathy.**Case Presentation:** A 61-year-old male patient presented with decreased vision in his left eye. He had a dome-shaped lesion below the macula and macular swelling in the fundus examination. Optical Coherence Tomography (OCT) showed neurosensory serous detachment of the macula and polypoid appearance in the region consistent with the dome-shaped lesion. The patient was recommended Fluorescein Angiography (FA), indocyanine green angiography (ICGA), but for economic reasons he refused to perform ICGA. After that, only FA was performed. As a result of the examinations, it was evaluated as central serous chorioretinopathy by a retina specialist. Three months later, because of subretinal fluid persistence, micropulse laser treatment including polyp-like lesion was applied.**Results:** At the 6th month follow-up, it was found that the fluid completely regressed and the Pigment Epithelial Detachment (PED) appearance occurred in place of the polypoidal appearance in OCT. In the 22nd month, subretinal fluid disappeared completely and PED appearance was observed.**Conclusions:** Although the characteristics of OCT of this case is similar to the OCT appearance in PCV, it would be more reasonable to consider this case as CSC in the light of current information, as this case responded to MPL treatment. Therefore, prospective studies with large groups are needed.**Keywords:** Polypoidal choroidal vasculopathy; Micropulse laser therapy; Central serous chorioretinopathy**Introduction**

Idiopathic Polypoidal Choroidal Vasculopathy (PCV) is a clinical term described by Yannuzzi et al. [1]. Clinically, it appears as nodular orange-red vascular lesions that rise from the choroid to the subretinal space in the macular, peripapillary, or peripheral fundus. Although a typical case of PCV occurs with recurrent acute submacular bleeding or serous Pigment Epithelial Detachments (PED); many are now known to have similar properties to exudative Age-Related Macular Degeneration (AMD), serous PED, fibrovascular PED, and subretinal fluid collection [2]. Some occur with serous retinal detachment that is clinically indistinguishable from Central Serous Chorioretinopathy (CSC) [3]. Fluorescent angiography shows classic and occult CNV models. Fluorescein angiogram can reveal the presence of the vascular network of small caliber vessels terminating in polyp-like structures [4]. Abnormal vascular structure of the choroid is best seen by Indocyanine Green (ICG) angiography. Polypoidal lesions appear as localized hyperfluorescence spots associated with branching networks of dilated vascular channels [5].

Case Presentation

A 61-year-old male patient presented with decreased vision

(BCVA: 0.2 Snellen line) in his left eye. The fundus examination of the patient revealed a dome-shaped lesion below the macula and macular swelling. OCT showed neurosensory serous detachment of the macula (subretinal fluid height: 216µm) and polypoid appearance in the region consistent with the dome-shaped lesion at the bottom (Figure 1). The patient was recommended Fluorescein Angiography (FA) and Indocyanine Green Angiography (ICGA), but for economic reasons he refused to perform ICGA. After that, only FA was performed.

FFA showed increased hyperfluorescence in the region compatible with the lesion (spot hyperfluorescence) and hyperfluorescence that might be compatible with a leakage or occult CNV below (Figure 1). The case had considered as central serous chorioretinopathy. Micropulse laser treatment (160µm, 200ms, 5% duty cycle, 450mW) including dome-shaped lesion was applied. At 3 months follow-up, the fluid was persistent and there was an increase in polyp size (BCVA: 0.2 Snellen line, subretinal fluid height: 253µm), (Figure 1). Then, one more session of MPL was applied. At the 6th month follow-up, it was found that the fluid completely regressed and the PED appearance occurred in place of the polypoidal appearance (BCVA: 0.8 Snellen line) (Figure 1). At the 15th month control, minimal

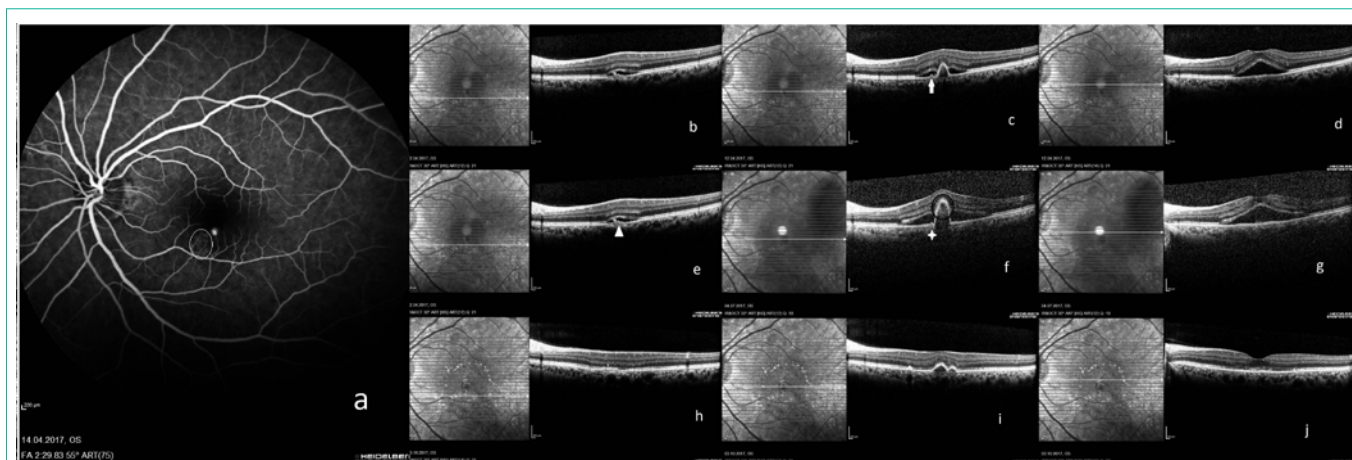


Figure 1: a) Spot hyperfluorescence and hyperfluorescence due to leakage (white circle); b) Double layer sign (black arrowhead) corresponding leakage area before first session of MPL; c) PED notch (White arrow) and sharp PED peak (black arrow) before first session of MPL; d) Neurosensorial macular detachment before first session of MPL; e) Double layer sign (white arrowhead) corresponding leakage area before second session of MPL; f) PED notch (asterisk) and a hyporeflective lumen within hyperreflective lesion (black circle) before second session of MPL; g) Neurosensorial macular detachment before second session of MPL; h) The region corresponding the double layer sign after 3 months of MPL; i) The region corresponding polypoidal lesion after 3 months of MPL; j) The macula after 3 months of MPL.

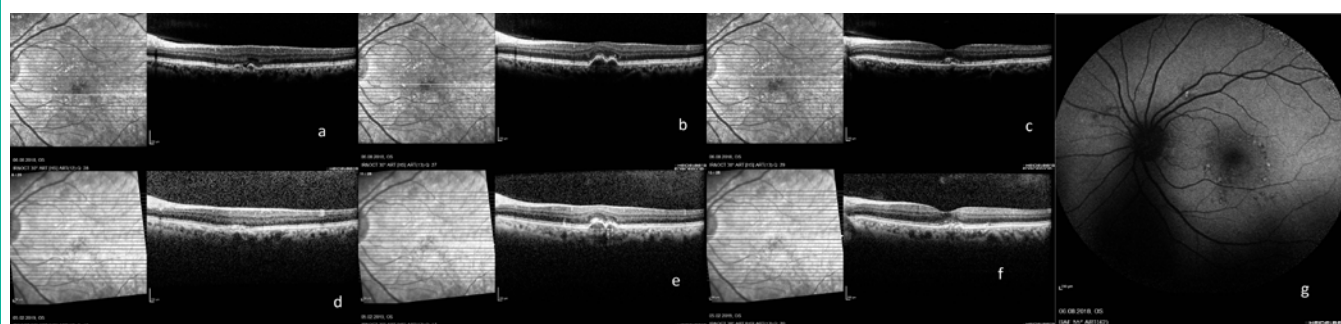


Figure 2: a, b, c) OCT images after 12 months of second session of MPL; d, e, f) OCT images after 18 months of second session of MPL; g) Fundus autofluorescence after 12 months of second session of MPL.

subretinal fluid and PED appearance were observed in the same way (BCVA: 0.6 Snellen line) (Figure 2). In the 22nd month, subretinal fluid disappeared completely and PED appearance was observed (BCVA: 0.7 Snellen line).

Discussion

Polypoidal choroidal vasculopathy and CSC are both falling within a spectrum of pachychoroid-related disorders [6]. The factors underlying the development of pachychoroid features and the mechanisms that link these features in PCV are not known [7]. Pathogenesis of CSC is not known clearly, however it has been hypothesized that choroidal vascular alterations in CSC and extravasation may be caused by choriocapillaris [8]. Focal laser therapy, photodynamic therapy and anti-VEGF therapy, or combination of these, are the treatment options used in PCV [6]. Although these treatments can be applied in CSC, Micropulse Laser Therapy (MPL) is an alternative and effective treatment option [9]. Albeit it is the gold standard diagnostic method to show the polyp with ICGA in PCV, OCT findings in this case suggest that PCV is highly likely. According to our knowledge, there is no any report that effectiveness of the MPL treatment in PCV. Although the characteristics of OCT of this case is similar to the OCT appearance in PCV, it would be more reasonable

to consider this case as CSC in the light of current information, as this case responded to MPL treatment. Therefore, prospective studies with large groups are needed.

Compliance with Ethics Guidelines

Informed consent was obtained from the patient for reporting this case.

All procedures performed in studies involving human participants were in accordance with the ethical standards of the institutional and/or national research committee and with the 1964 Helsinki Declaration and its later amendments or comparable ethical standards.

References

1. Yannuzzi LA, Sorenson J, Spaide RF, et al. Idiopathic polypoidal choroidal vasculopathy (IPCVC). *Retina*. 1990; 10: 1-8.
2. Lim TH, Laude A, Tan CS. Polypoidal choroidal vasculopathy: an angiographic discussion. *Eye (Lond)*. 2010; 24: 483-490.
3. Yannuzzi LA, Freund KB, Goldbaum M, et al. Polypoidal choroidal vasculopathy masquerading as central serous chorioretinopathy. *Ophthalmology*. 2000; 107: 767-777.
4. Ciardella AP, Donsoff IM, Huang SJ, et al. Polypoidal choroidal vasculopathy.

- Surv Ophthalmol. 2004; 49: 25-37.
5. Tso MOM, Suarez MJ, Eberhart CG. Pathologic study of early manifestations of polypoidal choroidal vasculopathy and pathogenesis of choroidal neovascularization. *Am J Ophthalmol Case Rep.* 2018; 11: 176-180.
 6. Cheung CMG, Lai TYY, Ruamviboonsuk P, et al. Polypoidal Choroidal Vasculopathy: Definition, Pathogenesis, Diagnosis, and Management. *Ophthalmology.* 2018; 125: 708-724.
 7. Cheung CMG, Lee WK, Koizumi H, et al. Pachychoroid disease. *Eye (Lond).* 2019; 33: 14-33.
 8. Nicholson B, Noble J, Forooghian F, et al. Central serous chorioretinopathy: update on pathophysiology and treatment. *Surv Ophthalmol.* 2013; 58: 103-126.
 9. Sartini F, Figus M, Nardi M, et al. Non-resolving, recurrent and chronic central serous chorioretinopathy: available treatment options. *Eye (Lond).* 2019; 33: 1035-1043.