

## Research Article

# Dig and Chop Modified Nuclear Disassembly Technique for Hard Cataract

**Elmazar HM\***

Department of Ophthalmology, Meoufia Faculty of Medicine, Egypt

**\*Corresponding author:** Hesham M. Elmazar, Department of Ophthalmology, Menoufia Faculty of Medicine, Shebin El Kom, Menoufia, Egypt**Received:** May 14, 2018; **Accepted:** June 19, 2018;**Published:** June 26, 2018**Abstract**

**Introduction:** Phacoemulsification (phaco) in hard cataracts remains a challenge and many modified techniques have been described to facilitate nuclear disassembly in these cases. This study was conducted to describe and evaluate the modified dig and chop technique for nuclear disassembly in hard cataract.

**Patients and Methods:** A prospective non-randomized case series study was conducted in the period from April 2016 till June 2017 at Ophthalmology Department, Menoufia University Hospitals, Egypt. The study included 30 patients suffering from hard cataracts. All cases underwent phaco cataract surgery with dig and chop modified technique for nuclear disassembly.

**Results:** The mean effective phaco time was  $12.98 \pm 1.53$  seconds (range 8.55 to 14.18 seconds) without significant difference in effective phaco time as regard to degree of nuclear hardness ( $P=0.537$ ), which ensure the effectiveness of the technique. Post operative assessment of visual acuity at 1, 7 and 30 days revealed that eyes with uncorrected visual acuity 0.5 or better accounted for 73.3%, 80.0% and 86.7% from all case respectively.

**Conclusion:** Dig and Chop modified nuclear disassembly technique for of hard cataract was found to be effective, controllable, and easy to perform technique that minimize effective phaco time and allow safe nucleus disassembly for hard cataracts.

**Keywords:** Phacoemulsification; Hard cataract; Nuclear disassembly

## Introduction

Phacoemulsification remains a challenge in hard cataracts because of the difficulty in nuclear management with possible complications [1].

For hard cataracts phaco chop is one of the best strategies [2]. The ability to fixate the nucleus remains a very crucial step in any chopping technique [3].

Many modified techniques have been described to separate endonuclear core from epinucleus [4]. As, drilling the central part of the nucleolus to facilitate its disassembly [5,6].

The ideal technique for nuclear disassembly should be easy to perform, controllable with minimal phaco power consumption to reduce the risk on corneal endothelium and for this reason this study was conducted to describe and evaluate dig and chop modified technique for nuclear disassembly in hard cataract.

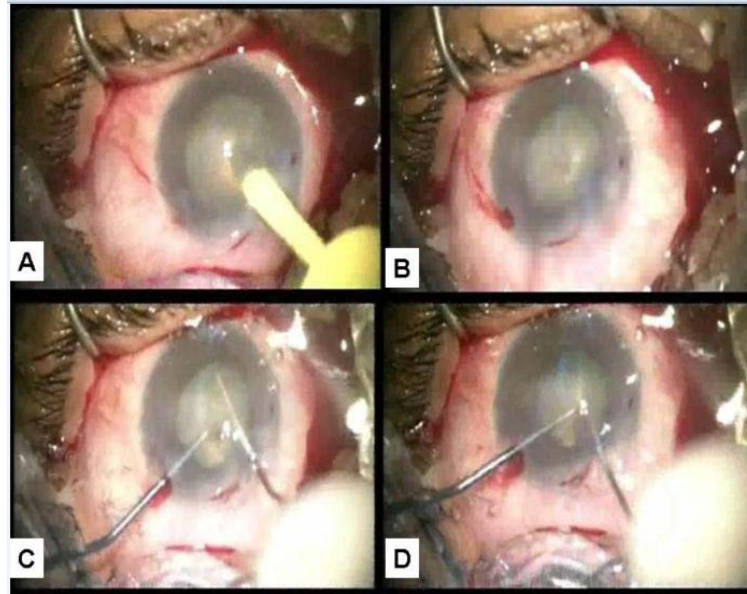
## Patients and Methods

A prospective non-randomized case series study was conducted in the period from April 2016 till June 2017 at Ophthalmology Department, Menoufia University Hospitals, Egypt. The study included 30 patients suffering from hard cataracts with grades 3-4 (grade 4 being the hardest). Approval from Faculty Ethics Committee was fulfilled and a written consent was obtained from all patients after detailed discussion about the risk and benefits of the operation. All

steps were in accordance with the tenets of the declaration of Helsinki. Cases included in the study were subjected to careful history taking, clinical and ophthalmologic examination including visual acuity, slit lamp, IOP, fund us, and a detailed lens examination with grading cataract type and severity. Also, necessary investigations including A & B ultrasonography were obtained after patient's approval.

## Surgical technique

Surgeries were done under complete aseptic conditions by the author (Elmazar HM). After sterilizing and draping the patients, sub-tenon anesthesia in the form of 3.5ml mepivacaine 2% was injected in the inferior part of medial canthus with sub-tenon cannula) to anesthetize the eye. Corneal incision was constructed with a keratome and two side ports were fashioned with curved MVR knife. Capsulorhexis (rhesis) was initiated with a cystotome and completed with rhesis forceps. Hydro dissection and nuclear rotation were done and a Megatrone S3, Geuder, Germany Phaco machine was set to power 80%, vacuum 10% mmHg, and bottle height 85cc then phaco probe was introduced with bevel down and directed to the center of the nucleus to make a central dig (Dig) about 2.5mm depth, then the phaco probe was withdrawn and the anterior chamber filled with viscoelastic substance. A blunt nuclear manipulator was introduced from side port to be engaged in the central dig and a sharp chopper introduced from main wound was engaged in the peripheral part of the nucleus under the edge of the rhesis and pulled toward the center (Chop), then both instruments were pushed aside as they come very



**Figure 1:** (A) Phaco tip digging the central part of nucleus, (B) The dig formed, (C) Blunt nuclear manipulator impacted in the central dig and sharp chopper engaged in the periphery of the nucleus (similar to splitting a piece of meat with fork and knife), (D) Chopping with the sharp chopper pulled toward the center and the blunt manipulator counteracting it.

close so that disassembly was done in a manner similar to splitting a piece of meat with a fork and knife (Figure 1). Chopping was repeated after rotating the nucleus to ensure nuclear disassembly in more than one meridian. Phaco probe was then introduced with power 60%, vacuum 350mmHg, and bottle high 100cc to complete nuclear aspiration with the assistant of blunt nuclear manipulator from side port. Finally irrigation aspiration and lens implantation were done followed by hydration of the wound and sub-conjunctival injection of 0.5ml gentamicin 20mg and 0.5ml dexamethason 0.5mg. Follow up was scheduled next day, after one week and after one month.

### Statistical analysis

Collected data were analyzed using SPSS statistical package version 17 under Microsoft Windows 7 platform. Continuous data were expressed in the form of mean±Standard Deviation (SD). P value less than 0.05 was considered statistically significant. Categorical data were expressed in the form of count and percent. P value less than 0.05 was considered statistically significant.

### Results

The mean effective phaco time was 12.98±1.53 seconds (range 8.55 to 14.18 seconds) without significant difference in effective phaco time as regard to degree of nuclear hardness ( $P=0.537$ ), which ensure the effectiveness of the technique in all cases. Preoperative recorded visual acuity assessment revealed counting fingers (44%), hand motion (40%), and light perception (16%) Post operative assessment of visual acuity at 1, 7 and 30 days revealed that eyes with uncorrected visual acuity 0.5 or better were 73.3%, 80.0% and 86.7% from all case respectively. A part from 3 cases with posterior capsule rupture and 4 cases who suffered moderate postoperative corneal edema that improved within the first week with topical steroid therapy there were no serious intra-operative or post-operative complications.

### Discussion

Nuclear disassembly in hard cataract was obtained in this study via initiating a central dig in the nucleus with phaco tip then performing radial chopping with sharp chopper from main wound and a blunt nuclear manipulator impacted in the central dig from side port to counter the effect of the sharp chopper and stabilize the nucleus, an idea that although seems to be very simple (similar to splitting a piece of meat with a fork and knife) was found to be very effective and controllable.

Other investigators as Hwang HS et al. 2010 described a nuclear disassembly for hard nucleus (drill-and-crack technique) in which they were able to crack the nucleus with a prechopper after drilling its central part with the phaco tip [5].

In this study a small dig about 2mm was made in the center of the nucleus and then a bimanual technique was applied to radial chop the nucleus without the need for a prechopper to crack the nucleus, this techniques was able to utilize less phaco power and allow more control on the nucleus with ability to rotate the nucleus and perform chopping in more than meridian, also, the technique is suitable for right hand or left hand surgeons with the ability to keep the sharp chopper in the dominant hand and the nuclear manipulator in non-dominant hand from any side port. It is, also, preferable to describe the technique with dig rather than drill as there is no complete hole in the nucleus and the action of phaco probe is closer to digging than drilling.

On the other hand, Kim DY, and Jang JH, 2010 described another drilling technique for hard cataract surgery (Drill and chop technique) where they first drill a hole into the endonucleus and then rotate the phaco tip clockwise to engage it firmly in the central nucleus before performing vertical chopping [6].

In this study there was no need to engage the bulky phaco tip which is more distracting besides applying more stress on lens zonules that are expected to be weak in these cases and nuclear stability was achieved instead with the help of blunt nuclear rotator introduce from side port and impacted in the center of the nucleus to counter the effect of the sharp chopper. Also, in this study horizontal chopping was applied which seems to be more controllable rather than vertical chopping specially in hard cataracts.

In the current study the aim was to attack the nucleus in the center and to reduce the phaco power needed to fracture the nucleus as possible by performing chopping technique, an idea that was favored by many other investigators [7-10]. Also, the use of a sharp chopper to perform radial chopping is similar to that described by Simanjuntak GW, et al, 2010 who utilized modified double extra sharp choppers for removal of hard cataracts [11]. But, in this study only one single regular sharp chopper was used to radial chop the nucleus while fixating the nucleus with a blunt nuclear manipulator to reduce the risk of using two extra sharp choppers simultaneously.

The dig and chop technique described in this study was able to achieve average effective phaco time comparable to that mentioned by Simanjuntak GW, et al, 2010. Although, Li SW, et al. 2007 described a peripheral radial chop technique with much less phaco time but this may be because of the difference in the phaco machine they used in their study [1].

In conclusion the dig and chop modified nuclear disassembly technique for hard cataract was found to be effective, controllable, and easy to perform technique that minimize phaco time and allow nucleus disassembly for hard cataracts and although in this study the technique was applied on hard cataracts only it seems to be also applicable in all types of cataracts as its value in soft cataracts will be to weaken the nuclear plate in order to allow easy phaco aspiration a point that may need further study on more cases with different cataract types and severity.

## References

1. Li SW, Xie LX, Song ZH, Meng L, Jiang J. Peripheral radial chop technique for phacoemulsification of hard cataracts. *Chin Med J (Engl)*. 2007; 120: 284-286.
2. Kamoi K, Mochizuki M. Phaco forward-chop technique for managing posterior nuclear plate of hard cataract. *J Cataract Refract Surg*. 2010; 36: 9-12.
3. Kummelil MK, Das S, Srikanth DT, Nagappa S, Shetty R, Shetty BK. Lens fiber orientation during phaco chop: clinical sign to identify appropriate nucleus depth. *Cataract Refract Surg*. 2013; 39: 1457-1460.
4. Kim HK. Decrease and conquer: Phacoemulsification technique for hard nucleus cataracts. *J Cataract Refract Surg*. 2009; 35: 1665-1670.
5. Hwang HS, Kim EC, Kim MS. Drill-and-crack technique for nuclear disassembly of hard nucleus. *J Cataract Refract Surg*. 2010; 36: 1627-1630.
6. Kim DY, Jang JH. Drill and chop: modified vertical chop technique for hard cataract. *Ophthalmic Surg Lasers Imaging*. 2012; 43: 169-172.
7. Berger A, Contin IN, Nicoletti G, Baltar Pazos PF, Baltar Pazos HS, Gomes JÁ. Middle prechop: Fracturing the middle portion of the nucleus. *J Cataract Refract Surg*. 2012; 38: 564-567.
8. Cakir H, Utine CA. Lift and crack technique for risky cataract cases. *J Cataract Refract Surg*. 2010; 36: 539-541.
9. Aslan BS, Müftüoğlu O, Gayretli D. Crater-and-split technique for phacoemulsification: modification of the crater-and-chop technique. *J Cataract Refract Surg*. 2012; 38: 1526-1530.
10. Joo CK, Kim YH. Phacoemulsification with a bevel-down phaco tip: phaco-drill. *J Cataract Refract Surg*. 1997; 23: 1149-1152.
11. Simanjuntak GW, Tan JF, Mailangkay HH. Double extra sharp chopper increase efficacy of phacoemulsification for hard mature cataract surgery. *Semin Ophthalmol*. 2010; 25: 8-12.