

Research Article

Reliability of Low Frequency Contact B Scan in Assessment of Optic Nerve Head Cupping

Yousuf S^{1*}, Gandhi M¹, Aggarwal M², Dubey S¹, Kanta M² and Chauhan L³

¹Department of Glaucoma Services, Dr. Shroff 's Charity Eye Hospital, India

²Department of Vitreoretina Services, Dr. Shroff 's Charity Eye Hospital, India

³Statistician, Dr. Shroff 's Charity Eye Hospital, India

*Corresponding author: Snober Yousuf, Dr. Shroff 's Charity Eye Hospital , New Delhi , India

Received: April 24, 2018; Accepted: May 07, 2018;

Published: May 14, 2018

Abstract

Optic disc analysis is an important step for glaucoma diagnosis and management. Clear media is a pre requisite for visualization of optic disc. In circumstances where media opacities hamper clinical assessment, contact B Scan is a useful tool which helps to assess the status of optic nerve head.

A prospective, single blinded, cross sectional investigational study was designed. The study included patients posted for surgery in which the optic disc evaluation was not possible due to media opacity. Ultrasonography was performed by a single investigator, unaware of the clinical findings. B scan findings were documented as presence or absence of optic nerve head cupping and later on correlated with clinical findings. The sensitivity of B scan in predicting optic nerve head cupping was found to be 83% (95% CI 0.80-0.90) and specificity of 100% (95% CI 0.97-1).

Our data suggests that even by low resolution contact B scanner, we can detect glaucomatous optic disc cupping in patients with cup: disc ratio ≥ 0.8 : 1, with high sensitivity and specificity. It is a cost effective method, beneficial in patients with opaque media and can help in taking appropriate intervention and also explain guarded visual prognosis to patients.

Keywords: Glaucoma; Optic disc cupping; B Scan; Visual prognosis

Introduction

Glaucoma is known to affect 60.7 million people worldwide with the estimated prevalence in India being 11.9 million [1]. Diagnosis of glaucoma is made in presence of characteristic optic disc changes and corresponding visual field defects. Visual impairment related to glaucomatous damage can only be prevented if the disease process is identified and treated early in its course. Morphometric evaluation of the optic nerve head, perimetry and tonometry contribute to the final diagnosis of glaucoma. The analysis of the optic disc is the most important step in the diagnosis of glaucoma and therefore a careful clinical observation should be performed to separate glaucomatous changes from normal optic disc [2]. Optic disc is most commonly assessed using the 78 or 90 dioptre lens at the biomicroscope and an estimate of cup: disc ratio and neuroretinal rim is noted. Several methods have been developed to evaluate optic disc morphologically such as Heidelberg Retinal Tomography and Optical Coherence Tomography. These techniques require expensive equipment and clear media.

Media opacities hamper clinical evaluation of optic disc. An objective method of assessment that is independent of actual visualization of optic nerve head morphometry would be a useful addition to the current array of investigations.

Our study is aimed to evaluate the reliability of B scanner in detecting optic nerve head cupping and correlating it with clinical findings. Assessing the status of optic nerve head in glaucomatous subjects, where morphological disc changes are not visible, would help to devise an appropriate surgical plan and explain visual

prognosis to patient.

Material and Methods

Patients were selected from outpatient services of a tertiary eye hospital in North India. The study was approved by the Institutional review board and was carried out in accordance with the Declarations of Helsinki, following good clinical practice guidelines.

A total of 371 eyes of 371 patients were evaluated with B scan. The study included 213 patients posted for surgery in which the optic disc evaluation was not possible due to media opacity. Common media opacities in our patients were corneal scar and cataract (Figure 1). 158 patients with clear media and glaucomatous optic nerve head, where the disc could be clinically evaluated, were included to validate B scan findings.

Patients who were unwilling to take part, those with active ocular surface disease and where optic disc was not clearly visible post operatively were excluded. All the patients underwent complete ophthalmic examination that included visual acuity measurement, Goldmann applanation tonometry, slit lamp biomicroscopy, gonioscopy and stereoscopic examination of the optic disc, wherever possible.

Patients with clear media underwent dilated fundus with detailed stereoscopic optic disc evaluation with + 90D(magnification factor 1.33) by a single examiner. In patients with angle closure glaucoma, dilated fundus evaluation was done post laser peripheral iridotomy.

Glaucomatous patients with clear media, after clinically evaluating optic nerve head cupping were subjected to B-Scan ultrasonography.

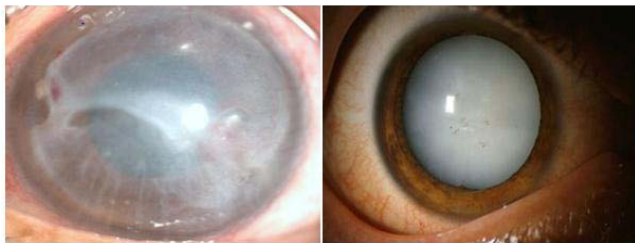


Figure 1: Patients with opaque media like corneal scar and mature cataract.

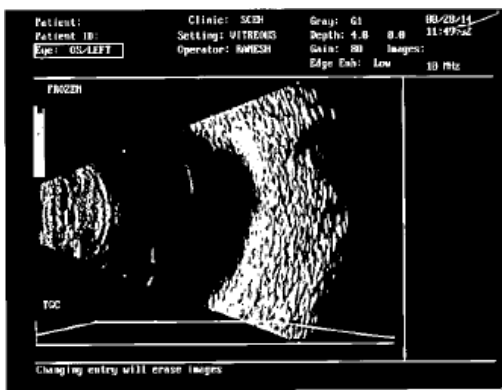


Figure 2A: Axial B Scan showing optic nerve head cupping.

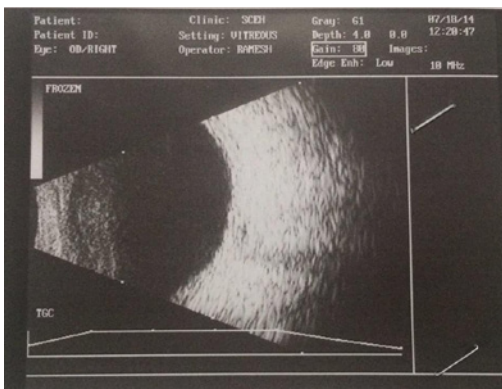


Figure 2B: Axial Scan showing normal optic nerve head.

In patients with opaque media and unknown cup: disc ratio, B-Scan and ONH cupping were documented and then compared to post-operative clinical findings.

Ultrasonography was performed by a single investigator unaware of the clinical findings. We used Ultra scan Imaging System from Alcon laboratories, a contact B scan with a frequency of 10 Mhz. Scanning was conducted with probe placed on closed eyelids [3]. Axial B scan showed optic cup as a posterior concavity to the acoustically clear area of the optic nerve. Best images were frozen and photographs were taken (Figures 2A and 2B).

Results

A total of 371 subjects participated in this study. The group comprised of 162 females and 209 males. The average age was 60 years with a range of 13-90 years. In 371 patients, clinical cupping

Table 1: Accuracy of B scans to predict optic nerve head cupping with regard to C: D ratio.

	C:D 0.3	C:D 0.4	C:D 0.5	C:D 0.6	C:D 0.7	C:D 0.8	C:D 0.9	TOTAL
ACCURATE	54	48	39	14	27	101	48	
NOT ACCURATE	0	0	0	27	13	0	0	
TOTAL	54	48	39	41	40	101	48	371

was present in 230 patients and B scan could predict it in 190 patients.

Sensitivity was calculated as the percentage of patients who were true positive (cup: disc ≥ 0.6) on B scan upon the number of patients who had cupping on clinical examination (true positive+ false negative) while as specificity was calculated as the percentage of patients who were true negative (cup: disc ≤ 0.5) on B scan upon the number of patients who did not have cupping on clinical examination (true negative + false positive). The sensitivity of B scan in predicting optic nerve head cupping was found to be 82.60% (95% CI 0.80-0.90) with specificity of 100% (95% CI 0.97-1).

In patients with a cup: disc ratio of $\geq 0.6:1$, B scan was able to predict cupping in 81.7% patients while in patients with a cup: disc ratio ≥ 0.8 , B scan accurately predicted optic head cupping in 100% patients. A decrease in cup: disc ratio 0.6 or less led to a decrease in sensitivity to 41.4% (Table 1).

Discussion

Optic disc evaluation is an important aspect for diagnosis of glaucoma. A distinctive feature of glaucoma is the cupping of the optic nerve head, which results from the posterior displacement and compression of the lamina cribrosa [4]. Ultrasonography can evaluate the optic disc cupping when media opacities hamper ophthalmoscopic evaluation of the optic disc. It is a cost effective method to evaluate the presence of optic nerve head cupping.

Our study aimed to assess the reliability of B scan to pick up optic disc cupping using low frequency B scanner. To our knowledge, this is the first study to calculate sensitivity and specificity of B scan for optic nerve head cupping.

Winder and Atta have shown a strong correlation between optical and ultrasonic cup diameters and concluded that optic disc cups of 0.5 mm or larger could be defined by B-scan echography [5].

Beatty et al evaluated optic disc with high resolution B scan and compared results with HRT. They found echo graphic measurements of two dimensional optic cup data to be reliable, with indices of reproducibility and test-retest variability comparable to those of scanning laser tomography [6].

Using low resolution B scan (10 MHz), we were able to predict optic nerve head cupping in 82.6% patients. A higher correlation between echographic descriptions of optic nerve head cup with increasing cup: disc ratio was found. It detected optic nerve head cupping in all patients with cup: disc ratio $\geq 0.8:1$. The sensitivity of the test to accurately predict optic nerve head cupping was found to be 83% with a specificity of 100%.

In our study, B scan was done to validate the findings in patients with clear media and significant optic nerve head cupping (cup: disc

ratio ≥ 0.6) and the investigator was blinded to the clinical features.

In patients with opaque media due to either mature cataract or corneal scars where optic nerve head visualization was not possible, underwent a B scan. In patients with corneal scars, raised intraocular pressure and optic nerve head cupping on B scan, glaucoma surgery either preceded or was done in combination with penetrating keratoplasty. In patients with mature cataract, signs of glaucoma were looked for in case of positive B scan findings and combined surgery was done where warranted. In cases where only cataract surgery was done, care was taken to preserve the conjunctiva so that glaucoma surgery can be undertaken in future if need arises.

The sensitivity of B scan to detect optic nerve head cupping in cup: disc ratio of 0.6 and 0.7 in our study was 51%. Previous investigations have shown that in glaucomatous patients the thickness of the retrobulbar optic nerve decreases with disease progression, a fact that would likely lead to a better correlation of the cup: disc ratio with ultrasonographic proportion [7,8]. It was reflected in our study also as the patients with advanced glaucomatous cupping (cup: disc ratio of 0.8:1 and 0.9:1), B scan detected optic nerve head cupping in all 100% cases.

Darnley - Fisch and co-workers showed that high-resolution contact B-scan could accurately categorise cups as small, medium or large [9]. They found echographic description of shallow, saucer-shaped cups less reliable. We did not categorise the cups as shallow or deep clinically, which was one of the limitations of our study.

The strengths of our study are sample size, single blinded study and the analysis of sensitivity and specificity of B scan to predict optic nerve head cupping.

Conclusion

Our study suggests that even by low resolution contact B scanner,

we can detect glaucomatous optic disc cupping in patients with cup: disc ratio $\geq 0.8:1$ with high sensitivity and specificity. It is a cost effective method beneficial in patients with opaque media and can help us in taking appropriate intervention. It can also explain guarded visual prognosis to patients.

References

- George R, Ve RS, Vijaya L. Glaucoma in India: Estimated burden of disease. *J Glaucoma* 2010; 19: 391-397.
- Barbosa CP, Angelini PF, Schor P, Paranhos Junior A. Simulated cup/disc ratio: a tool for ophthalmologists. *Arq Bras Oftalmol.* 2010; 73: 320-322.
- Cohen JS, Stone RD, Hetherington J, Bullock J. Glaucomatous optic cupping of the optic disc by ultrasonography. *Am J Ophthalmol.* 1976; 82: 24-26.
- Lambert WS, Clark AF, Wordinger RJ. Effect of exogenous neurotrophins On Trk receptor phosphorylation, cell proliferation, and neurotrophin secretion by cells isolated from the human lamina cribrosa. *Mol Vis.* 2004; 10: 289-296.
- Winder S, Atta HR. Ultrasonography of the optic disc cup in discs of various sizes. *Eye.* 1996; 10: 732-736.
- Beatty S, Good PA, McLaughlin J, E O'Neill. Echographic measurements of the retrobulbar optic nerve in normal and glaucomatous eyes. *Br J Ophthalmol.* 1998; 82: 43-47.
- Dichtl A, Jonas JB. Echographic measurement of optic nerve thickness correlated with neuroretinal rim area and visual field defect in glaucoma. *Am J Ophthalmol.* 1996; 122: 514-519.
- Lagrèze WA, Gaggi M, Weigel M, Schulte-Mönting J, Bühler A, Bach M, et al. Retrobulbar optic nerve diameter measured by high-speed magnetic resonance imaging as a biomarker for axonal loss in glaucomatous optic atrophy. *Invest Ophthalmol Vis Sci.* 2009; 50: 4223-4228.
- Darnley-Fisch DA, Byrne SF, Hughes JR, Parrish RK II, Feuer WJ. Contact B-scan echography in the assessment of optic nerve cupping. *Am J Ophthalmol* 1990; 109: 55-61.