

## Case Report

# Amniotic Membrane Transplantation for Paracentral Corneal Perforations

Guo P<sup>1#</sup>, Su JJ<sup>1#</sup>, Lin BT<sup>1</sup>, Zhang Y<sup>2\*</sup> and Zhu YT<sup>2\*</sup><sup>1</sup>Shenzhen Eye Hospital, Jinan University, Shenzhen Eye Institute, Shenzhen 518040, China<sup>2</sup>BioTissue (TissueTech, Inc.), 7235 Corporate Center, USA**\*Corresponding author: Yuan Zhang & Yingting Zhu**

Tissue Tech, Inc., 7235 Corporate Center Drive, Suite B, Miami, FL 33126, USA

**Received:** December 29, 2022; **Accepted:** February 08, 2023; **Published:** February 15, 2023

#The first two authors contribute equally to this work.

**Abstract****Objective:** To report the clinical efficacy of Amniotic Membrane Transplantation (AMT) for paracentral perforations caused by Blepharokeratoconjunctivitis (BKC).**Methods:** A retrospective review was performed on consecutive patients that had paracentral corneal perforations caused by BKC and were subsequently treated with AMT between October 2019 and September 2021. Visual acuity (BCVA), anterior chamber depth, angle opening, corneal thickness and number of Demodex mites were examined before and after the operation.**Results:** Eleven eyes of 11 patients (2 males, 9 females, aged 11-22 years old) with BKC were included in the analysis. Three months after AMT, BCVA significantly improved from  $1.14 \pm 0.8$  at baseline to  $0.35 \pm 0.2$  ( $p=0.004$ ) and the proportion of patients with mite infestation decreased from 7 cases (64%) to 2 cases (18%). OCT confirmed the corneal perforations healed with normal corneal thickness and formation of anterior chamber with normal angle opening. During the follow up duration of 6-17 months, no recurrence or complications were noted.**Conclusion:** This case series suggests AMT can restore vision and corneal thickness in patients with aseptic corneal perforations caused by BKC.**Keyword:** Blepharokeratoconjunctivitis; Corneal perforation; Amniotic membrane; Transplantation**Introduction**

Blepharokeratoconjunctivitis (BKC) is a type of chronic, inflammatory eyelid disease involving the conjunctival and corneal [1-4]. The early symptoms include photophobia tears, red eyes, blepharospasm and scaly deposition on margin with a history of recurrent chalazion. BKC can cause progressive conjunctivitis, keratitis and various corneal complications such as: corneal infiltration, corneal neovascularization, scarring and corneal ulcers [3,5]. Due to the lack of self-protection and the poor awareness of the diagnosis, the situation is more severe among young people than adults. BKC is often under diagnosed or misdiagnosed in clinical practice, which can often lead to corneal perforations and significant visual impairment in these patients.

Corneal perforations are an ophthalmic emergency regardless of the etiology. A few patients can be cured by timely intervention of keratoplasty. However, most patients lose their vision permanently due to formation of adhesive leukoplakia or enucleation due to treatment delay. For corneal perforations in younger patients, early and effective treatment is particularly important to preserve the eyeball and save vision. Amniotic membrane transplantation has been widely used in the treatment of various ocular surface diseases in recent years, such as ocular surface chemical injuries [6], corneal epithelial and nerve regeneration [7], wound healing by limbal stem cells [8], corneal perforations [9], corneal ulcers [10-12] and dry eyes [13]. This study retrospectively reviewed 11 cases of patients with paracentral central perforations caused by BKC treated by amniotic membrane transplantation in our hospital from October 2019 to September 2021.

## Materials and Methods

A retrospective review was performed on 11 eyes of 11 consecutive patients that had paracentral corneal perforations caused by BKC and were subsequently treated with AMT between October 2019 and September 2021. This study followed the tenets of the Helsinki Declaration on ethical principles for medical research involving human subjects and was approved by the Committee of Eye Research Institute Review Board, Shenzhen Eye Hospital, China. These patients failed to improve after bandaging for 2-5 days and subsequently underwent amniotic membrane packing and amniotic membrane transplantation treatment. Best Corrected Visual Acuity (BCVA) and number of eyelid mites were compared before and after operation. The changes of anterior chamber depth, angle opening and corneal thickness in the perforated area were also assessed using slit light and anterior segment OCT.

The BKC diagnostic criteria were as follows: (a) presence of blepharitis: 1. neovascularization and congestion of palpebral margin; 2. lash root scaly, cuff-like suede, eyelash loss or disorder; 3. eyelid margin scab or ulcer; 4. the lipid plug or blocking at the opening of the meibomian gland and the quality of the meibum changed. 5. eyelid edge is thickening and not smooth. Diagnosis was confirmed if they had presence of the first item along with any one item of 2 to 5 items. (b) History of recurrent conjunctivitis and keratopathy with blepharitis; (c) and had one of the following typical signs: 1. conjunctival hyperemia, papillary hyperplasia, follicular formation and vesicular conjunctivitis; 2. punctate keratitis, punctate erosion around the cornea, infiltration, ulcer formation or even perforations, or shallow neovascularization, formed with varying degrees of corneal opacity. (d) After the treatment of blepharitis was improved, the keratoconjunctival lesions were obviously improved, and the corneal neovascularization could quickly subside. Bacterial and fungal culture were performed routinely on the ulcerated edge of corneal perforations by scraping before surgical operation.

### Detection of Mites [14,15]

Eyelid mites were assessed by optical microscope (Olympus) before surgery and after 3 months. Three eyelashes were taken from the upper and lower eyes of the patient (eyelashes with lipid-like cuff secretions or trichiasis with lipid-like cuff secretions were obtained from the inner, middle and outer edges of the eyelid), hence 12 lashes were taken from both eyes. The eyelashes were placed on a slide in parallel with cedar drops under a covered glass. The number and morphology of demodex mites were then counted. Positive presence of mites was defined as having a Demodex count of 3/3 eyelashes in any of the 4 eyelids. Less than the above criteria were suspected positive, combined with clinical manifestations, if necessary, reviewed and confirmed.

### Amniotic Membrane Transplantation

**Preparation of the amniotic materials [16,17]:** The amniotic membrane was derived from placental tissue of healthy cesarean section women without vaginal infection. Conventional serological tests for syphilis antibody, human immunodeficiency virus antibody, Hepatitis B surface antigen and Hepatitis C antibody were all negative. Follow the references from Dr. Scheffer Tseng to prepare and preserve amniotic membrane: the amniotic membrane was separated from the choroid after cleaning the placental blood clot and cut into 3cm×4cm grafts. The treated

amniotic membrane was stored in a sterile vial of glycerol and DMEM medium (V/V=1:1) at -80°C. The amniotic membrane was taken out before operation, and the amniotic membrane was immersed in 1:2000 tobramycin physiological saline on an aseptic table and rehydrated for 20 minutes for clinical use.

**Surgical methods:** After routine disinfection, 0.5% Proparacaine Hydrochloride Eye Drops (Alcon) was administered every 5 minutes and 3-4 times for topical anesthesia to begin operation. After eyelid opening, 5% povidone iodine solution was used to flush the conjunctival sac (avoiding corneal perforations). After that, the rehydrated amniotic membrane was folded in 2-4 layers, packed into the corneal perforation defect, and sutured with 10-0 nylon thread (10-0 Nylon 698001, Alcon) on the adjacent relatively normal corneal tissue with 2-3 stitches. Another layer of fresh amniotic tissue was covered on the amniotic membrane surface at the tamping site, with a range slightly larger than 1-2mm in the lesion area. The second layer of amniotic membrane was sutured and fixed on the normal corneal tissue around the perforation margin with 10-0 nylon thread. After the operation, a therapeutic bandage lens and TobraDex dexamethasone eye ointment (TobraDex, Alcon) was applied, the bandage was pressurized, and opened for examination 24 hours later.

**Postoperative treatment:** After 24 hours of eye bandaging, the eye was opened locally. TobraDex Eye Drop (Alcon) was administered 4 times a day, and 0.5% Levofloxacin Eye Drops (Santen) was given 4 times a day, and TobraDex Ointment (Alcon) was applied once a night for 2 weeks. After that, 0.02% Fluorometholone Eye Drops (Santen) was used 4 times a day, Pranoprofen Eye Drops (Senju Pharmaceutical Co, Ltd.) was applied 4 times a day for 2 weeks, 0.02% Fluorometholone Eye Drops (Santen) was applied 3 times a day, and 0.3% Sodium Hyaluronate Eye Drops (Santen) 4 times a day, for 1 to 2 months.

**Postoperative follow-up:** After one week, two weeks, one month, three months and six months, visual acuity testing, slit lamp examination and Anterior segment OCT (Moptim, OSE-1200) were performed to observe the visual function, depth of anterior chamber, healing of corneal perforations and changes in corneal thickness. The therapeutic bandage lens was removed 2 weeks after surgery, and the surface of the corneal suture was removed from the cornea. The deep corneal suture lines were removed 1 to 2 weeks later.

**Statistical methods:** SPSS 25.0 software was used for statistical analysis. ANOVA and T test were used to verify the results of preoperative and postoperative BCVA. BCVA was converted to the LogMAR for statistical analysis.

## Results

A total of 11 eyes of 11 consecutive patients were included in the analysis including 2 males (2 eyes, 18%), 9 females (9 eyes, 82%), aged 11 to 22 years old, with BKC onset between 14 months and 8 years. All patients presented with paracentral corneal perforations between 0.5 – 1mm that affected the surrounding 2-3mm corneal area. All affected areas were negative for microbial growth. All patients underwent AMT without complication within one week of hospital admission.

At 3 months after AMT, BCVA significantly improved from  $1.14 \pm 0.8$  at baseline to  $0.35 \pm 0.2$  ( $p=0.004$ ) (Table 1).

The anterior chamber was also formed and the tissue in the corneal perforation area healed with normal corneal thickness

as determined by OCT. The proportion of patients with Demodex mites decreased from 7 out of 11 patients at baseline to 2 out of 11 patients at 3 months. Throughout the follow up duration of 6-17 months, the eyelid inflammation was stable with no recurrence of keratopathy, no secondary infection, and no other complication (Table 2, Figure 1 and Figure 2).

### Case Report

In case 11, the patient was a young woman with an acute episode of chronic disease. she was admitted to the hospital on September 22, 2020, complained 'repeated redness and photophobia in the right eye for 8 years, aggravated by 2 days of vision loss. Physical examination revealed Vod 0.3 (corrected helpless) Vos 1.0, intraocular pressure (IOP): Tod T-1 Tos 12mmHg, visible secretions were attached to the roots of the right eyelashes, the mouth of meibomian gland were occluded with a large amount of fat plugs, and presence of conjunctival hyperemia. In the center of the cornea, there was a circular grayish-white turbidity and thinning area, with seidel test (+). The surrounding cornea was gray and turbid, the anterior chamber disappeared (Figure

3A), the reaction to light disappeared, Lens transparency. Auxiliary examination showed that the mite detection was negative, Anterior segment OCT (Casia tomye ss-1000) examination demonstrated that the central cornea of the right cornea became thinner, the surrounding cornea was turbid, and the anterior chamber disappeared (Figure 3B). The diagnosis was: corneal perforations (od), corneal macula (od), blepharitis (ou), and Meibomian Gland Dysfunction (ou).

On September 25, 2020, amniotic tamponade and amniotic membrane transplantation was performed. After surgery, the postoperative eye was treated with TobraDex Eye Drops (Alcon) 4 times a day, Levofloxacin Eye Drops (Santen) 4 times a day, and TobraDex (Alcon) eyes were applied at night with wearing bandage lens for 2 weeks. The routine review showed a good recovery. Three months later, the anterior chamber formed stable, and keratosis formed (Figure 3C). The anterior segment OCT (Figure 3D) showed that the angle of the anterior chamber had been opened and the thinnest thickness of the central corneal was 269  $\mu\text{m}$ .

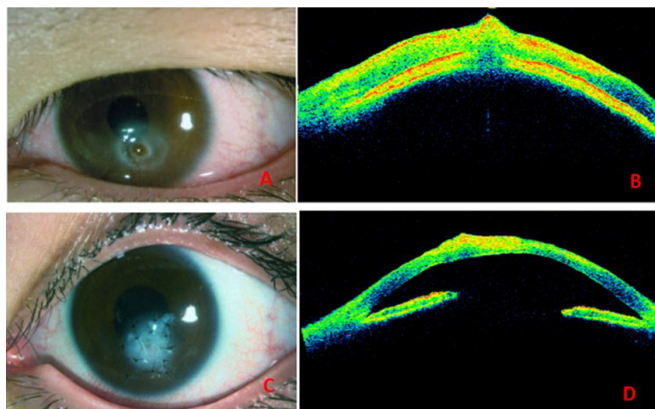
**Table 1:** Basic information of the case.

	Sex	Age	Years	Mite detection before	Surgery	Vision before Surgery	Vision after Surgery	Mite detection
Case 1	F	20	5	(+)	AM Transplantation	0.3	0.6	(-)
Case 2	F	22	3	(-)		0.2	0.4	(-)
Case 3	F	16	4	(-)		0.01	0.16	(-)
Case 4	F	12	1.5	(+)		0.1	0.7	(+)
Case 5	F	11	2	(+)		HM/ anterior segment	0.4	(-)
Case 6	F	15	2	(-)		0.16	0.5	(-)
Case 7	F	16	4	(+)		0.2	0.6	(-)
Case 8	F	12	3	(+)		0.05	0.3	(-)
Case 9	M	16	1.2	(+)		0.05	0.6	(+)
Case 10	M	19	2	(+)		0.2	0.5	(-)
Case 11	F	20	8	(-)		0.3	0.4	(-)

Remarks: Vision is the best corrected visual acuity at the time of follow-up in March, and postoperative mite testing is conducted 3 months after surgery.

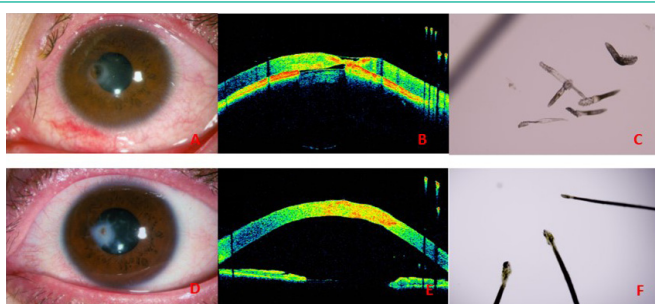
**Table 2:** Demographic and Clinical Outcomes of Each Case

Case Number	Gender	Age	Onset time (month)	Pre-operation		Post-operation (3 months)	
				BCVA (LogMAR)	Mite detection	BCVA (LogMAR)	Mite detection
1	F	20	60	0.5	(+)	0.2	(-)
2	F	22	36	0.7	(-)	0.4	(-)
3	F	16	48	2.0	(-)	0.8	(-)
4	F	12	18	1.0	(+)	0.15	(+)
5	F	11	24	3.0	(+)	0.4	(-)
6	F	15	24	0.8	(-)	0.3	(-)
7	F	16	48	0.7	(+)	0.2	(-)
8	F	12	36	1.3	(+)	0.5	(-)
9	M	16	14	1.3	(+)	0.2	(+)
10	M	19	24	0.7	(+)	0.3	(-)
11	F	20	96	0.5	(-)	0.4	(-)



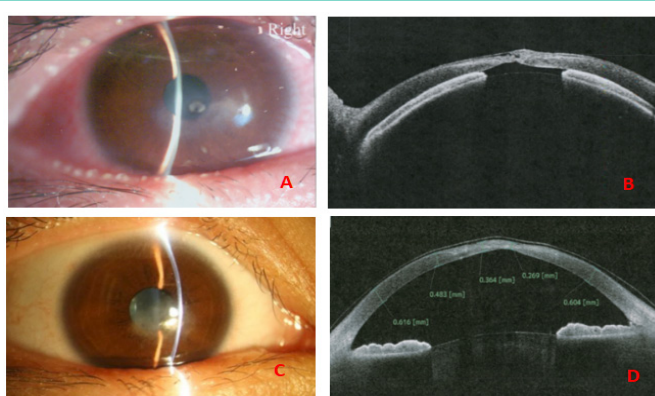
**Figure 1:** The report of number case 4.

The anterior chamber disappeared and the iris was incarcerated before surgery (A,B). After treatment, the anterior chamber was well formed, and the perforations were closed (C,D).



**Figure 2:** Preoperative corneal changes

Case 7. Preoperative corneal perforations, disappearance of anterior chamber, positive test of eyelid mites (A,B,C). Four months after the operation, the anterior chamber was well formed, the corneal thickness became normal, and the eyelid mites were negative (D,E,F).



**Figure 3:** Morphological changes of the eye after surgery.

Case 11. The opening of meibomian gland was blocked before surgery, the cornea perforated, and the anterior chamber disappeared (A, B). Three months after the operation, the anterior chamber was stabilized and the corneal thinnest thickness was about 269  $\mu\text{m}$  (C, D).

## Discussion

BKC is a chronic inflammatory disease of the ocular surface and has a high incidence in children and young people up to 32 years old. According to reports, the incidence of BKC in children is 15%, and is common in Asian populations [18]. Corneal damage caused by BKC is associated with repeated chronic infection of the eye, physical stimulation of the eyelids margin, immune response and heredity. Due to the unevenness, bulge, and hy-

peremia of the eyelid margin in BKC patients, the upper and lower eyelids routinely come in contact with the cornea and cause mechanical friction. This occurred at the position of 2,4,8 and 10 of the cornea to form the paracentral corneal ulcer and perforations [19]. Unfortunately, there is often a delay in diagnosis in younger patients and a longer onset of morbidity without proper effective treatment. Compared with similar studies in developed countries, the collected BKC patients with corneal perforations are older and generally have a longer onset time, which is also one of the important factors for corneal perforation in BKC patients.

Common surgical treatments for corneal ulcer perforations include keratoplasty, conjunctival flap occlusion, and direct corneal suture. Conjunctival flaps covering the cornea often leads to neovascularization, fibrosis and proliferation of abnormal epithelial cells of the cornea, which destroys the transparency of the cornea. Inflammation of the conjunctival tissue and neovascularization of the cornea are often risk factors for subsequent treatments such as keratoplasty or other ocular surface reconstructions [20]. Alternatively, corneal transplantation is the preferred surgical procedure for corneal perforations, which can repair the defective corneal tissue timely, but is limited by available corneal material. It is also difficult for direct corneal suture because the poor tissue conditions around the perforations cannot bear the force of suturing. If performed, not only is the wound difficult to heal, but also the corneal surface will obviously deform and cause serious astigmatism to affect the vision.

Amniotic membrane is the innermost layer of placental structure, without nerves, blood vessels, lymphatic vessels and other structures. Moreover, it has no immunogenicity and is rich in a variety of nutrients, anti-inflammatory and growth-promoting factors. After proper processing and preservation, amniotic membrane can be widely used in corneal and other ocular surface diseases because of its functions of reducing ocular surface inflammation, inhibiting ocular surface neovascularization, and promoting ocular surface tissue repair, such as the treatment of persistent epithelial defects [21], neurotrophic ulcers [22], keratoconjunctival damage caused by chemical injury [23], ocular surface reconstruction of pterygium surgery [24,25]. For the paracentral perforations with a diameter of 1-2mm, amniotic membrane tissue can replace the defective corneal tissue to a certain degree and promote healing of the corneal tissue. This healing has a relatively small effect on corneal curvature, which may lead to a better correction vision and avoid the risk of rejection after transplantation. Compared with corneal donor material, amniotic membrane material has many advantages such as easy access, low cost and no need for long-term follow-up after surgery. Therefore, amniotic membrane transplantation is undoubtedly better than keratoplasty in terms of vision prognosis and safety for small corneal perforations caused by BKC in developing adolescents with poor compliance. The thickness of transplantation area is relatively thin early after amniotic membrane transplantation, but the tissue gradually recovers to a safe thickness over time.

The visual prognosis depends on the size of the corneal lesion, the location of implant, postoperative astigmatism, patients' compliance, and many other factors including Demodex mites. Demodex infections are more common in the elderly, while children are less likely to develop but still can [26-29]. The keratoconjunctivitis induced by mite infection has been reported in domestic and foreign literatures [30-33], mainly based on

the following reasons: eyelid mites may carry many pathogenic microorganisms, mainly bacteria, causing secondary bacterial infections in the eyelid margin. Secondly, the activity and reproduction of them may directly destroy and physically damage the structure of eyelash hair follicles and meibomian glands, causing abnormal eyelashes and the obstacle of formation and excretion of meibum. Thirdly, as foreign body antigens, their excrement and bacteria will induce local immune response and cause a series of immune-related inflammation. Recent studies have shown that mite infection is closely related to the incidence of meibomian gland dysfunction and keratitis in children (23). In this study, among the 11 patients diagnosed as BKC with corneal perforations, 7(64%) were positive for eyelid mites. This incidence was higher than that in the same age group (not yet published). After perioperative eye cleaning and postoperative anti-inflammatory and anti-infective drug treatment, eye surface immunogenic and bacterial infection-related inflammation was effectively controlled, and only 2(18%) of the patients were positive for eyelid mites, suggesting that eyelid mite infection may be closely related to the occurrence of corneal inflammation. Some cases show mites disappearance after surgery, we believe that it is probably because after perioperative eye cleaning and postoperative anti-infective drug treatment, the mites have disappeared. Hence, it is necessary to give appropriate treatment to patients infected with mites such as local anti-inflammatory and anti-infection drugs. Further clinical studies are needed to confirm about the cause of disease and subduction of mites.

### Funding

This work is supported by the Science, Technology and Innovation Commission of Shenzhen Municipality (Grant Number: GJHZ 20190821113607205).

### Conflicts of Interest

All authors have no potential conflicts of interest to declare.

### References

- Saldanha IJ, Lindsley KB, Lum F, Dickersin K, Li T. Reliability of the Evidence Addressing Treatment of Corneal Diseases: A Summary of Systematic Reviews. *JAMA Ophthalmol.* 2019; 137: 775-85.
- Medsing A, Gajdosova E, Moore W, Nischal KK. Management of inflammatory corneal melt leading to central perforation in children: a retrospective study and review of literature. *Eye (Lond).* 2016; 30: 593-601.
- Pant OP, Hao JL, Zhou DD, Lu CW. Tectonic keratoplasty using femtosecond laser lenticule in pediatric patients with corneal perforation secondary to blepharokeratoconjunctivitis: a case report and literature review. *J Int Med Res.* 2019; 47: 2312-20.
- Trief D, Marquezan MC, Rapuano CJ, Prescott CR. Pediatric corneal transplants. *Curr Opin Ophthalmol.* 2017; 28: 477-84.
- Rodriguez-Garcia A, Gonzalez-Godinez S, Lopez-Rubio S. Blepharokeratoconjunctivitis in childhood: corneal involvement and visual outcome. *Eye (Lond).* 2016; 30: 438-46.
- Eslani M, Baradaran-Rafii A, Cheung AY, Djalilian AR, Holland EJ. Amniotic Membrane Transplantation in Acute Severe Ocular Chemical Injury: A Randomized Clinical Trial. *Am J Ophthalmol.* 2019; 205: 203.
- Wan LQ, Zhang YY, Wang HF, Chen C, Li H, Zhang Y, et al. Efficacy of rhNGF-loaded amniotic membrane transplantation for rabbit corneal epithelial and nerve regeneration. *Int J Ophthalmol.* 2021; 14: 1653-9.
- Messmer EM. Wound healing following amniotic membrane, limbal stem cell and corneal transplantation]. *Ophthalmologie.* 2020; 117: 1163-70.
- Ke L, Shen D, Wang H, Qiao C, Zeng Q. Lamellar Keratoplasty Combined with Amniotic Membrane Transplantation for the Treatment of Corneal Perforations: A Clinical and In Vivo Confocal Microscopy Study. *Biomed Res Int.* 2020; 2020: 7403842.
- Lacorzana J, Campos A, Brocal-Sanchez M, Marin-Nieto J, Duran-Carrasco O, Fernandez-Nunez EC, et al. Visual Acuity and Number of Amniotic Membrane Layers as Indicators of Efficacy in Amniotic Membrane Transplantation for Corneal Ulcers: A Multicenter Study. *J Clin Med.* 2021; 10: 3234.
- Schuerch K, Baeriswyl A, Frueh BE, Tappeiner C. Efficacy of Amniotic Membrane Transplantation for the Treatment of Corneal Ulcers. *Cornea.* 2020; 39: 479-83.
- Liu J, Li L, Li X. Effectiveness of Cryopreserved Amniotic Membrane Transplantation in Corneal Ulceration: A Meta-Analysis. *Cornea.* 2019; 38: 454-62.
- Elbaz U, Ong Tone S, Fung SSM, Mireskandari K, Ali A. Evaluation of dry eye disease in children with blepharokeratoconjunctivitis. *Can J Ophthalmol.* 2022; 57: 98-104.
- Gao YY, Di Pascuale MA, Li W, Liu DT, Baradaran-Rafii A, Elizondo A, et al. High prevalence of Demodex in eyelashes with cylindrical dandruff. *Investigative ophthalmology & visual science.* 2005; 46: 3089-94.
- Kheirikhah A, Casas V, Li W, Raju VK, Tseng SC. Corneal manifestations of ocular demodex infestation. *Am J Ophthalmol.* 2007; 143: 743-9.
- Kim JC, Tseng SC. Transplantation of preserved human amniotic membrane for surface reconstruction in severely damaged rabbit corneas. *Cornea.* 1995; 14: 473-84.
- Lee SH, Tseng SC. Amniotic membrane transplantation for persistent epithelial defects with ulceration. *Am J Ophthalmol.* 1997; 123: 303-12.
- Gupta N, Dhawan A, Beri S, D'Souza P. Clinical spectrum of pediatric blepharokeratoconjunctivitis. *Journal of AAPOS: the official publication of the American Association for Pediatric Ophthalmology and Strabismus/American Association for Pediatric Ophthalmology and Strabismus.* 2010; 14: 527-9.
- Liu T, Zhai H, Xu Y, Dong Y, Sun Y, Zang X, et al. Amniotic membrane traps and induces apoptosis of inflammatory cells in ocular surface chemical burn. *MolVis.* 2012; 18: 2137-46.
- Hanada K, Shimazaki J, Shimmura S, Tsubota K. Multilayered amniotic membrane transplantation for severe ulceration of the cornea and sclera. *Am J Ophthalmol.* 2001; 131: 324-31.
- Foerster CG, Langenbacher A, Cursiefen C, Kruse FE, Seitz B. Delayed epithelial healing after keratoplasty for lattice corneal dystrophy. *Cornea.* 2007; 26: 1182-3.
- Semeraro F, Forbice E, Romano V, Angi M, Romano MR, Filippelli ME, et al. Neurotrophic keratitis. *Ophthalmologica.* 2014; 231: 191-7.
- Meller D, Pires RTF, Mack RJS, Figueiredo F, Heiligenhaus A, Park WC, et al. Amniotic membrane transplantation for acute chemical or thermal burns. *Ophthalmology.* 2000; 107: 980-90.
- Jirsova K, Jones GLA. Amniotic membrane in ophthalmology: properties, preparation, storage and indications for grafting-a review. *Cell Tissue Bank.* 2017; 18: 193-204.
- Feng Y, Borrelli M, Reichl S, Schrader S, Geerling G. Review of alternative carrier materials for ocular surface reconstruction.

- Current eye research. 2014; 39: 541-52.
26. POST CF, JUHLIN E. Demodex folliculorum and blepharitis. Archives of dermatology. 1963; 88: 298-302.
  27. Coston TO. Demodex folliculorum blepharitis. Trans Am Ophthalmol Soc. 1967; 65: 361-92.
  28. Liang L, Ding X, Tseng SC. High prevalence of demodex brevis infestation in chalazia. Am J Ophthalmol. 2014; 157: 342-8.
  29. Moon J, Lee J, Kim MK, Hyon JY, Jeon HS, Oh JY. Clinical Characteristics and Therapeutic Outcomes of Pediatric Blepharokeratoconjunctivitis. Cornea. 2022.
  30. Suzuki T. Meibomitis-related keratoconjunctivitis: implications and clinical significance of meibomian gland inflammation. Cornea. 2012; 31: S41-S4.
  31. Suzuki T, Mitsuishi Y, Sano Y, Yokoi N, Kinoshita S. Phlyctenular keratitis associated with meibomitis in young patients. AmJ Ophthalmol. 2005; 140: 77-82.
  32. Liang L, Liu Y, Ding X, Ke H, Chen C, Tseng SCG. Significant correlation between meibomian gland dysfunction and keratitis in young patients with Demodex brevis infestation. Br J Ophthalmol. 2018; 102: 1098-102.
  33. Patel NV, Mathur U, Gandhi A, Singh M. Demodex blepharokeratoconjunctivitis affecting young patients: A case series. Indian J Ophthalmol. 2020; 68: 745-9.