

Case Report

Case Report: Fuchs Dystrophy after Corneal Transplantation

Leite J*, Neves MM, Gomes M and Oliveira L

Department of Ophthalmology, Centro Hospitalar Universitário do Porto (CHUPorto), Portugal

*Corresponding author: João Leite

Department of Ophthalmology, Centro Hospitalar Universitário do Porto (CHUPorto), Largo do Prof. Abel Salazar, Oporto, 4099-001 Oporto, Portugal

Received: December 19, 2022; **Accepted:** January 24, 2023; **Published:** January 31, 2023

Abstract

Fuchs Endothelial Corneal Dystrophy (FECD) consists of a progressive loss of corneal endothelial cells, with subsequent development of subepithelial connective tissue objectively leading to severely impaired vision. Generally, the time interval between the asymptomatic stage, with only the presence of guttates on biomicroscopy, to the most advanced stage, associated with chronic edema that causes corneal opacity and scarring, can vary between 20 to 30 years of evolution. Eye bank donor cornea selection includes FECD screening based on macroscopic and specular microscopy findings. However, this screening may not be sensible enough to detect the disease in its earlier stages. We report 2 cases of FECD in corneal grafts in which the donor corneas eye bank screening was negative for FECD. These two cases highlight the importance of a meticulous evaluation of donor corneas candidates for corneal transplant. Traditional evaluation was not sensible enough to detect early phases of FECD. Additional screening methods, such as genetic testing, would improve the accuracy to detect FECD and other diseases present in donor corneas used in corneal transplants.

Keywords: Fuchs Dystrophy; Corneal Transplant; Penetrating Keratoplasty; Descemet Stripping Automated Endothelial Keratoplasty; Eye Bank

Abbreviations: FECD: Fuchs Endothelial Corneal Dystrophy; IC3D: International Classification of Corneal Dystrophies; LE: Left Eye; PK: Penetrating Keratoplasty; BCVA: Best Corrected Visual Acuity; DSAEK: Descemet Stripping Automated Endothelial Keratoplasty; EK: Endothelial Keratoplasty; DMEK: Descemet Membrane Endothelial Keratoplasty; hCECs: Human Corneal Endothelial Cells

Introduction

Fuchs Endothelial Corneal Dystrophy (FECD) is an age-related disorder that affect especially women [1], first described in 1910 by Ernst Fuchs as “corneal epithelial dystrophy” [2]. However, it was quickly discovered that the endothelium was the cause of this dystrophy with morphological and functional abnormalities [2,3]. According to the International Classification of Corneal Dystrophies (IC3D), FECD is categorized into 2 forms [2,4,5]: a rare, early-onset form and a more common late-onset form and both subtypes appear to have similar time to progression from disease onset to corneal decompensation [1,4]. Clinically FECD presents in four stages: in the first stage of the disease, the

patient is asymptomatic but with central irregularly scattered guttae; in second stage, blurred vision, glare, and colored halos develop around the lights as stromal and epithelial edema develops. The patient may notice an improvement in symptoms over the course of the day due to increased tear evaporation, resulting in increased tear osmolality; the third stage is characterized by the development of subepithelial connective tissue objectively and although the patient is less complaining due to the reduction in edema, there is a decrease in visual acuity; the fourth stage is characterized by chronic edema that causes corneal opacity and scarring, leading to severely impaired vision and pain [2,3,6].

This article presents 2 cases of FECD that occur in eyes previously submitted to corneal transplantation.

Case Report 1

We report the case of an 82-year-old woman, pseudophakic, with a history of Left Eye (LE) Penetrating Keratoplasty (PK) due to FECD in 2007. In 2017, a new PK was performed due to graft failure (diffuse corneal opacification). Two years after the second PK, in 2019, the Best Corrected Visual Acuity (BCVA) was 20/40. In 2021, the patient started complains of slightly reduced vision in her LE (20/50), with episodic vision fluctuations and glare. Slit-lamp examination revealed changes

in endothelial specular reflection, with small dark spots and a “beaten metal” pattern (Figure 1). Specular microscopy (Figure 2a) confirmed the diagnosis of FECD, with the presence of typical endothelial guttate, irregular warts and cells varying in size and shape. The preoperative evaluation of the donor cornea (50 years old; endothelial cell count: 2463 cells/mm²) used in the 2017 corneal transplant (Figure 2b) showed a normal slit lamp examination and specular microscopy evaluation revealed only a few small black spots, interpreted as artifacts as they didn’t seem to be guttatas. Overall, there were not clear signs suggesting pathological endothelial changes contraindicating the use of that cornea in a transplant.

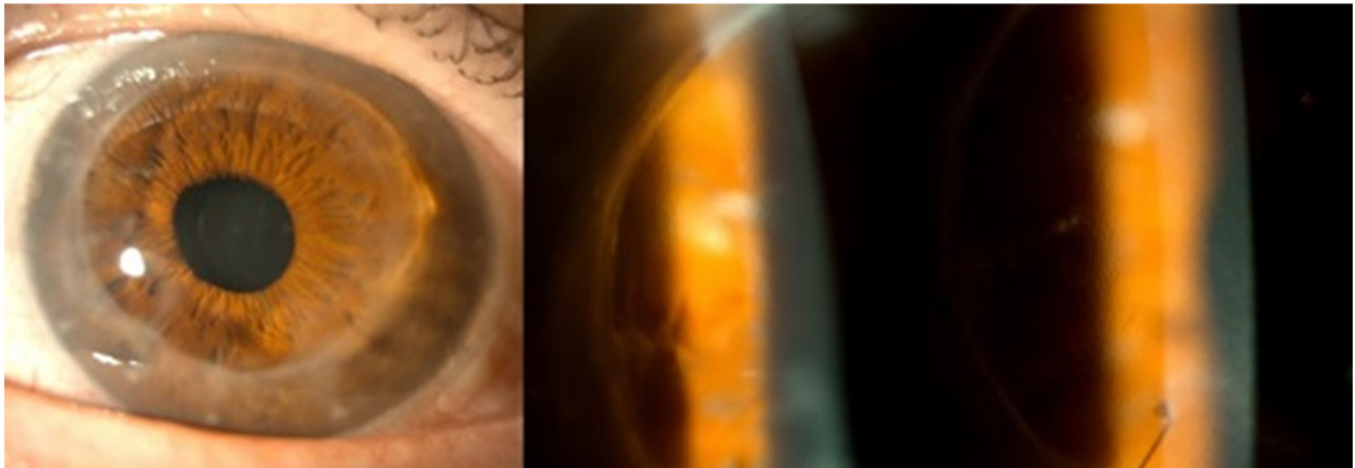


Figure 1: Slit lamp examination with “beaten metal” pattern (case 1).

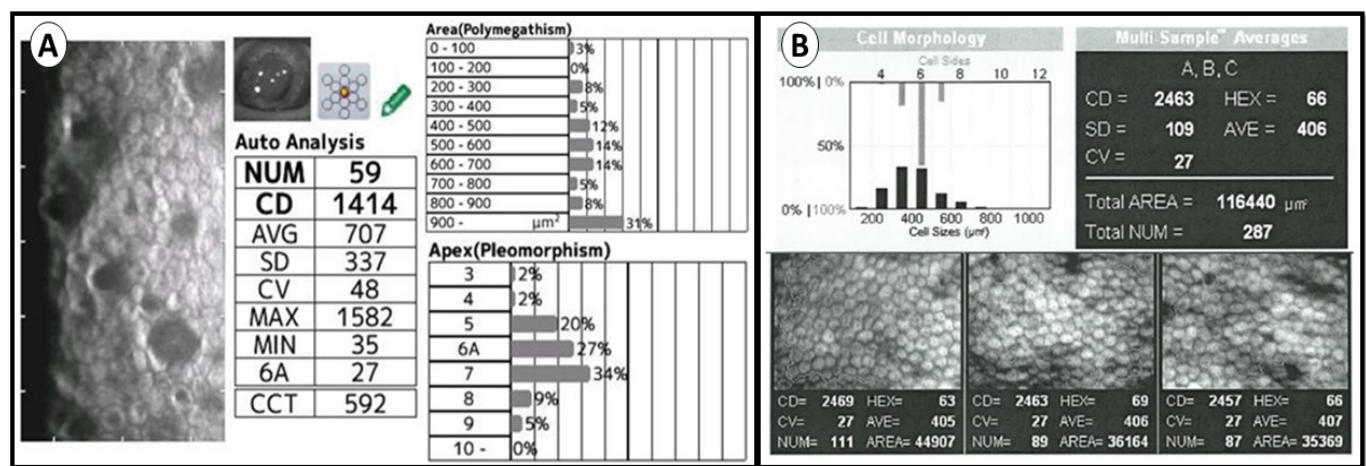


Figure 2: Specular microscopy (case 1): a: Cellular pleomorphism and typical endothelial guttate; b: Donor cornea prior to 2017 corneal transplantation.

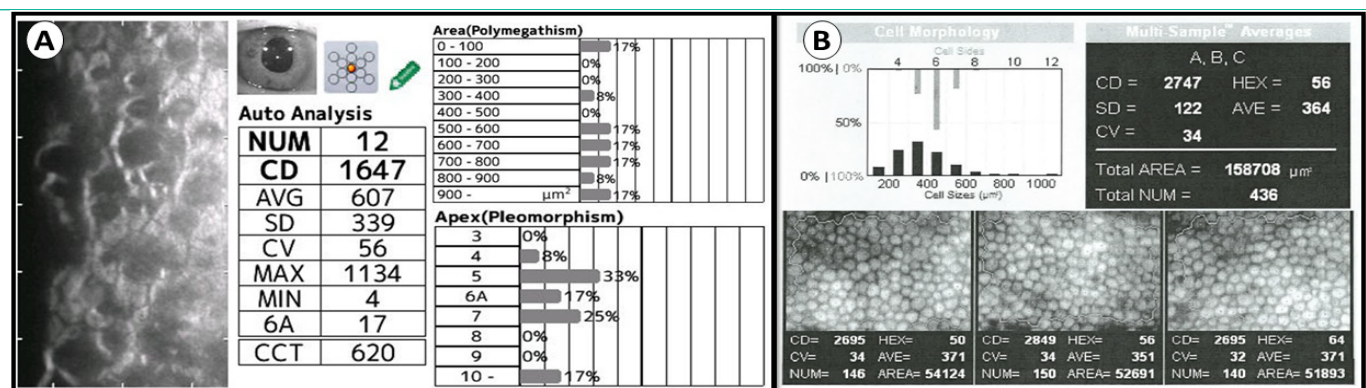


Figure 3: Specular microscopy (case 2): a: Cellular pleomorphism and typical endothelial guttate; b: Donor cornea prior to 2017 corneal transplantation.

Case Report 2

We report the case of an 83-year-old woman, pseudophakic, with a history of Descemet Stripping Automated Endothelial Keratoplasty (DSAEK) in the Right Eye (RE) due to FECD in 2017. Six months after surgery, BCVA was 20/40. In 2022, five years after DSAEK, the patient had a decrease in BCVA, with visual acuity decreasing to 20/80. Slit lamp examination revealed changes in endothelial specular reflection, with small dark spots and a "beaten metal" pattern. Specular microscopy (Figure 3a) confirmed the diagnosis of FECD, with the presence of typical endothelial guttates and cells varying in size and shape. The preoperative evaluation of the donor cornea (40 years old; endothelial cell count of 2747 cells/mm²) used in the 2017 (Figure 3b) showed a normal specular microscopy evaluation. Therefore, this donor cornea did not show any alterations suggestive of endothelial disease that would contraindicate the use of this cornea in a transplant.

Discussion/Conclusion

FECD is a bilateral disease of corneal endothelium characterized by subendothelial accumulation of extracellular matrix and accelerated loss of corneal endothelial cells [7].

The primary treatment of FECD is a medical treatment, with the aim of treating the early symptoms of illness, such as blurry vision in the morning, increasing the external osmolarity (using hypertonic sodium chloride drops or ointment can be given to extract water from the cornea) [6].

Corneal transplant is the definitive treatment of FECD. PK has been the mainstay of surgical treatment for many years. However, alternative procedures based on Endothelial Keratoplasty (EK) - DSAEK and Descemet Membrane Endothelial Keratoplasty (DMEK) [10,11]- have surpassed PK in the last fifteen years: namely lower rate of graft rejection, minimal wound related complications, minimal induced astigmatism and faster visual recovery, when compared to PK. Currently, DSAEK is the most commonly performed EK in U.S.A. [12]. Future prospects for new treatments have been developed, such as injection of cultured Human Corneal Endothelial Cells (hCECs) for the treatment of various endothelial failure conditions [13].

In case 1, this patient was initially treated with PK, as in 2007 there were no DSAEK or DMEK available in the setting in which the patient was evaluated, and these techniques are just beginning to spread around the world. In 2017, a new PK was performed, due to diffuse opacification of the graft. In these situations, endothelial transplantation is not indicated, so a new PK was performed.

In case 2, given the wide dissemination and experience of corneal transplant centers in EK, DSAEK was the treatment of choice for FECD.

We report two examples of patients who had previously undergone corneal transplantation (PK in the first case and EK in the second one) that developed FECD 4 and 5 years after this surgical procedure, respectively. These cases demonstrate the possibility of FECD development in grafts after corneal transplantation, either PK or EK. From our point of view, these intriguing findings may result from one of the following etiological mechanisms:

1) FECD was present in the donor cornea: the retrospective analysis of the donor cornea used in case 1 reveals that, at the time of transplantation, it already presented slight endothe-

lial morphological alterations, however these changes did not appear to be clear signs of endothelial changes suggestive of FECD, with the small black dots being interpreted as artifacts and, therefore, the cornea was used for transplantation. Retrospective analysis of the donor cornea used in case 2 patient did not show any suspicious signs of FECD. However, given the small area examined by specular microscopy, these numbers may underestimate the real prevalence of postoperative guttae in both cases [14]. Some studies found isolated guttae (4-25.6%) and grouped guttae (1.6-4.8%) in donor corneas for corneal transplantation [14,15].

2) Donor cornea developed disease after transplantation: guttate may have passed unnoticed in the eye bank, or become evident soon after transplantation, possibly as a result of surgical stress and/or interaction with the new recipient environment, not it being possible to exclude an accelerated structural and functional deterioration of these grafts after the surgical procedure [14]. This hypothesis arises based on the age of the donor corneas at the time of transplantation (40 and 50 years respectively in cases 1 and 2) with an apparent absence of endothelial alterations suggestive of FECD.

3) The receptor cornea determined the onset of the disease in the donor cornea: currently there is no scientific evidence that the recipient cornea is responsible for the development of disease in the donor cornea, in the case of FECD. This etiological mechanism is currently accepted and known, for example, in keratoconus, in which the recipient cornea changes the donor cornea at the level of keratocytes, the host epithelium and at the level of chronic epithelial-stromal interactions, inducing changes in the layer Bowman and, consequently, recurrence of the pathology in the grafted cornea [13]. However, there is still no evidence demonstrating this etiological mechanism as being a possible cause of FECD in a graft.

As far as we know, no information was found in medical information search engines (such as PubMed) reporting a case of FECD in a corneal graft. Some studies show that eyes with post-keratoplasty guttae have outcomes similar to those of eyes without guttae [14]. However, we report 2 cases of eyes that developed FECD 4 and 5 years after corneal transplantation.

These two cases highlight the importance of a meticulous evaluation of donor corneas candidates for corneal transplant. Slit lamp examination and specular microscopy may not be sensible enough to detect early phases of FECD, especially in corneas of younger donors, where the disease may not be clearly manifest already. Newer screening examinations like genetic testing may increase the accuracy in detecting pathologies like FECD in donor corneas used in corneal transplantation.

Statement of Ethics

Ethical approval is not required for this study in accordance with local or national guidelines. Written informed consent was obtained from the patient for publication of this case report and any accompanying images. The patient's informed consent was obtained during the assessment visits.

Conflict of Interest Statement

Miguel Mesquita Neves is consultant of Alcon Portugal – Produtos e Equipamentos,Lda.

The others authors have no conflicts of interest to declare.

Author Contributions

João Leite combined the data, analysis, manuscript drafting and finalized the manuscript. Miguel Mesquita Neves combined data, analysis, manuscript drafting, finalized the manuscript, performed the surgical treatment and conducted the follow-up of the patient. Miguel Gomes conducted data analysis and manuscript critical review. Luis Oliveira conducted data analysis and critically reviewed the manuscript. All authors approved the final version of the manuscript and are accountable for all aspects of the work. All authors attest that they meet the current ICMJE criteria for authorship.

Data Availability Statement

The clinical data that support the findings of this clinical case are available in the electronic hospital register of CHUPorto. All data generated or analyzed during this study are included in this article. Further enquiries can be directed to the corresponding author.

References

- Nanda GG, Alone DP. REVIEW: Current understanding of the pathogenesis of Fuchs' endothelial corneal dystrophy. *Mol Vis*. 2019; 25: 295–310.
- Hamill CE, Schmedt T, Jurkunas U. Fuchs endothelial cornea dystrophy: A review of the genetics behind disease development. *Semin Ophthalmol*. 2013; 28: 281–6.
- Wilson SE, Bourne WM. Fuchs' dystrophy. *Cornea*. 1988; 7: 2–18.
- Vedana G, Villarreal G, Jun AS. Fuchs endothelial corneal dystrophy: Current perspectives. *Clin Ophthalmol*. 2016; 10: 321–30.
- Ong Tone S, Kocaba V, Böhm M, Wylegala A, White TL, Jurkunas UV. Fuchs endothelial corneal dystrophy: The vicious cycle of Fuchs pathogenesis. *Prog Retin Eye Res*. 2021; 80: 100863.
- Eghrari AO, Riazuddin SA, Gottsch JD. Fuchs Corneal Dystrophy. *Prog Mol Biol Transl Sci*. 2015; 134: 79–97.
- Matthaei M, Hribek A, Clahsen T, Bachmann B, Cursiefen C, Jun AS. Fuchs Endothelial Corneal Dystrophy: Clinical, Genetic, Pathophysiologic, and Therapeutic Aspects. *Annu Rev Vis Sci*. 2019; 5: 151–75.
- Hribek A, Mestanoglu M, Clahsen T, Reinking N, Frentzen F, Howaldt A, et al. Scheimpflug Backscatter Imaging of the Fibrillar Layer in Fuchs Endothelial Corneal Dystrophy. *Am J Ophthalmol*. 2022; 235: 63–70.
- Hammersmith KM. The IC3D classification of the corneal dystrophies. *Yearb Ophthalmol*. 2009; 2009: 112–3.
- Alnabulsi R, Showail M, Sorkin N, Einan-Lifshitz A, Rootman D. Fuchs' endothelial dystrophy masquerading as keratoconus. *Can J Ophthalmol*. 2019; 54: e176–80.
- Rocha-De-Lossada C, Rachwani-Anil R, Borroni D, Sánchez-González JM, Esteves-Marques R, et al. New Horizons in the Treatment of Corneal Endothelial Dysfunction. *J Ophthalmol*. 2021; 2021: 6644114.
- Numa K, Imai K, Ueno M, Kitazawa K, Tanaka H, Bush JD, et al. Five-Year Follow-up of First 11 Patients Undergoing Injection of Cultured Corneal Endothelial Cells for Corneal Endothelial Failure. *Ophthalmology*. 2021; 128: 504–14.
- Raecker ME, Erie JC, Patel SV, Bourne WM. Long-term keratometric changes after penetrating keratoplasty for keratoconus and Fuchs endothelial dystrophy. *Trans Am Ophthalmol Soc*. 2008; 106: 187–93.
- Nahum Y, Canton V, Ponzin D, Busin M. Prevalence of guttae in the graft following corneal transplantation. *Br J Ophthalmol*. 2015; 99: 1660–3.
- Borderie VM, Sabolic V, Touzeau O, Scheer S, Carvajal-gonzalez S, Laroche L, et al. Screening human donor corneas during organ culture for the presence of guttae. 2001; 85: 272–6.