

## Case Report

# New Evidence on BEST1 Genetic Variant Identified in a Patient with Best Vitelliform Macular Dystrophy Phenotype

Falah R<sup>1\*</sup>, Distefano LN<sup>1</sup>, Abuli-Vidal A<sup>2</sup>, Garcia Arumi J<sup>1</sup> and Boixadera A<sup>1</sup>

<sup>1</sup>Retinal Department, Vall d'Hebron University Hospital, Barcelona, Spain

<sup>2</sup>Genetic Department, Vall d'Hebron University Hospital, Barcelona, Spain

\*Corresponding author: Falah R, Retinal Department, Vall d'Hebron University Hospital, Passeig de la Vall D'Hebron, 119, 08035, Barcelona, Spain

We acknowledge Rachel Boixadera's help in the English Editing of the case report.

Received: July 22, 2021; Accepted: August 13, 2021;

Published: August 20, 2021

## Abstract

Best Disease (BD), also known as Best Vitelliform Macular Dystrophy (BVMD), represents an inherited autosomal dominant macular dystrophy with a juvenile age of onset [1].

It is a phenotypically heterogeneous, bilateral condition that affects the retina and Retinal Pigment Epithelium (RPE) caused by pathogenic variants in the BEST1 gene located on chromosome 11q12-13 [2,3].

Typical fundus findings in BD are egg yolk-like, round or oval, lesions seen in the macula, and affected eyes may demonstrate various clinical stages, ranging from the previtelliform stage to Choroidal Neovascularization (CNV) [4]. The macular appearance in all stages is deceptive, as most patients maintain relatively good visual acuity throughout the course of the disease.

Patients commonly experience visual compromise in early adulthood, although the age of onset can range from childhood to late adulthood [3] and most patients with BD maintain good vision in at least one eye. The presence of subretinal fluid or CNV has been associated with a poorer visual prognosis [4].

In this case report, we describe a patient with clinical features suggestive of Best disease. We discuss the differential diagnosis and we present the multimodal imaging of the retina used for both the diagnosis and follow up. We also report a genetic study that demonstrates more evidence on a novel genetic variant in the BEST1 gene. The same genetic mutation has been recently reported as a novel variant in a single patient with BVMD [5].

**Keywords:** Best vitelliform macular dystrophy; Maculopathy; Retina; Genetic variant

## Case Presentation

A 25-year-old woman originally from Uruguay was referred to our retinal department with the diagnosis of bilateral Central Serous Choriorretinopathy (CSC). The onset of the symptoms was subacute: the patient had noticed mild blurring of her vision in both eyes with difficulty in focusing but without metamorphopsia, during the previous year.

Her ocular history was insignificant. However, both her father and brother had macular problems of unknown origin.

On examination, best-corrected visual acuities at distance were 20/30 in the right eye and 20/50 in the left eye. Intraocular pressures by Goldmann tonometer were normal.

Anterior segment examination was unremarkable in both eyes. Funduscopic examination demonstrated normal-appearing optic disks and retinal vasculature. In the posterior pole of both eyes (Figure 1), subretinal fibrosis was observed in the central macula with shallow serous retinal detachment that extended inferiorly. There was an orange-yellowish lipofuscin deposit temporal to the macula. The peripheral retina had a hammered metal appearance. There was no

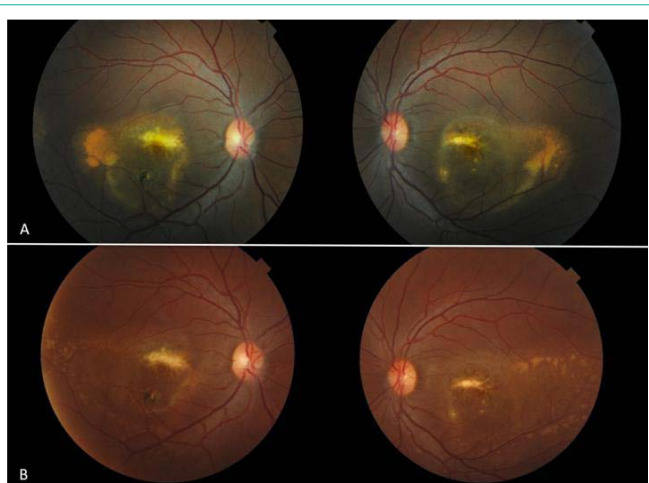
evidence of hemorrhage.

Fundus Autofluorescence (FAF) imaging (Figure 2) showed central mild hypoautofluorescence surrounded by a ring of bright hyperautofluorescent spots. The temporal lipofuscin deposits were hyperautofluorescent.

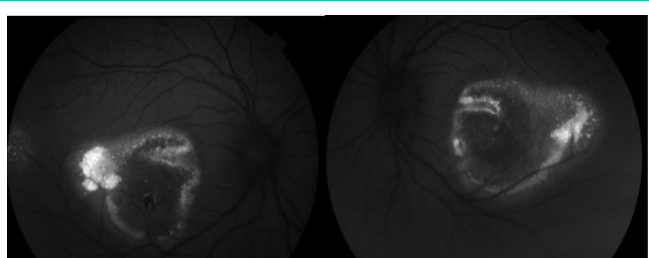
Fluorescein angiography (Figure 3) demonstrated intense staining of the subretinal fibrosis with no evidence of pooling, hot spots or signs of choroidal neovascularization

Optical Coherence Tomography (OCT) imaging (Figure 4) confirmed the presence of subretinal fibrosis with serous retinal detachment as well as a bilateral Pigment Epithelial Detachment (PED) in the central macula.

Based on the progressive onset of symptoms, the family history of the patient and the lack of the typical signs of CSC on multimodal imaging of the retina, the patient underwent electrophysiological testing and the results were consistent with the diagnosis of Best disease. The Electrooculogram (EOG) showed reduced Arden ratios in both eyes (125% in the right eye and 114% in left eye) and the full-field electroretinogram was normal.



**Figure 1:** A) Retinographies at diagnosis: yellowish lipofuscin deposition temporal to the macula with subretinal fibrosis. Shallow serous retinal detachment extending inferiorly. B) Retinographies at 5 years follow up, noticeable decrease in the lipofuscin deposition temporal to the macular with no changes in the subretinal fibrosis not in the serous retinal detachment.



**Figure 2:** FAF at diagnosis: central mild hypoautofluorescence surrounded by a ring of brightly hyperautofluorescent spots. Hyperautofluorescent temporal lipofuscin depositions.

To confirm the suspected diagnosis of BD, molecular genetic testing was performed and the results showed that the patient was heterozygous for (c.324C>G) a likely pathogenic variant in the BEST1 gene.

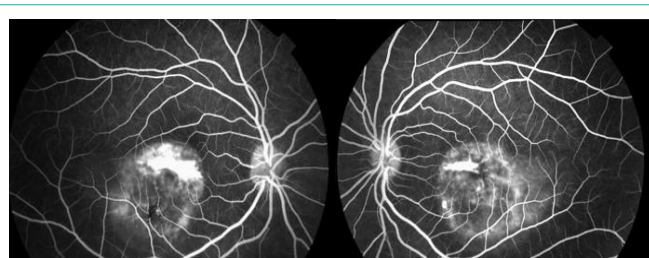It was not possible to extend ophthalmic examination and genetic analysis to members of the patient’s family since they live in another country.

Our patient undergoes periodic visits and after 5 years of follow-up, no substantial changes in morphological and functional data have been observed (Figure 1 and 4).

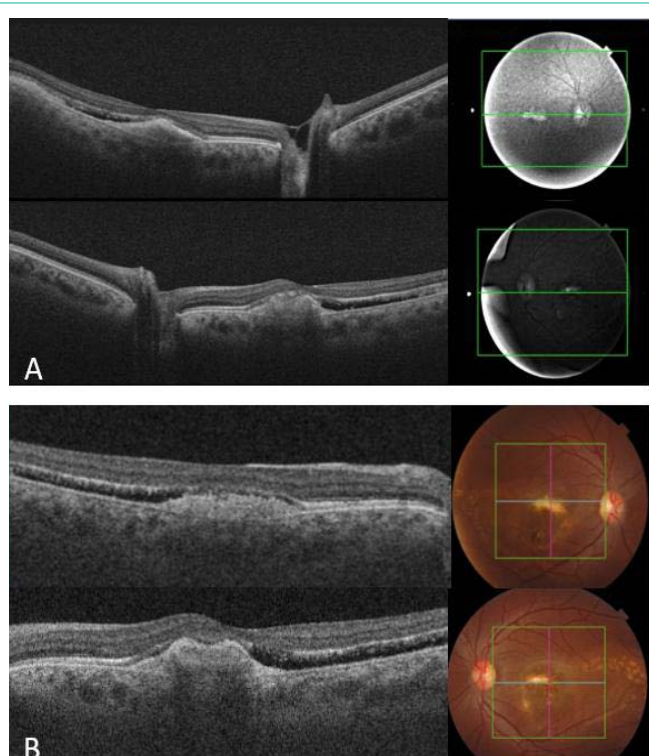
**Discussion**

BD (or Vitelliform macular dystrophy) was first described by Freidrich Best in 1905 [6].

It is a rare autosomal dominant disorder caused by a mutation in the VMD2 or BEST1 gene at chromosome 11q12-q13 [2,7]. The product of this gene is a transmembrane protein called Bestrophin 1, located at the basolateral membrane of the RPE that functions both as a pentameric anion channel and a regulator of intracellular Ca2+ signaling [8]. The ionic balance of the RPE is an important factor that determines the adhesion between the retina and the RPE. The pathophysiology of the disease is thought to be secondary



**Figure 3:** Angiography at diagnosis: intense staining of the subretinal fibrosis.



**Figure 4:** A) OCT at diagnosis: Subretinal fibrosis with a serous retinal detachment and a bilateral Pigment Epithelial Detachment (PED) in the central macula. B) OCT at 5 years follow up: similar subretinal fibrosis with bilateral serous retinal detachment.

to a disruption in fluid and ion transport caused by the faulty bestrophin-1 calcium-sensitive chloride channel [3]. Without a normally functioning chloride channel, the homeostasis of the RPE is disrupted, leading to an accumulation of fluid between the photoreceptors and the RPE, thus rendering both less effective.

The effect of the mutation on this protein is not completely understood but it is associated with toxic photoreceptor outer segment byproducts accumulation, which may cause photoreceptor loss, RPE atrophy, and subsequent visual impairment [3].

BD is usually a bilateral condition, but some cases with unilateral disease have been reported [9].

The presentation is highly variable, but typically presents during the first or second decade, with worsening of visual acuity [10].

BD can be completely asymptomatic and discovered as an incidental finding on ophthalmological examination. A slow decline

in visual acuity may occur over several years [11].

Best's disease may be difficult to recognize clinically. There are three main stages that characterize the disease: the vitelliform stage, the pseudohypopyon stage, and the vitelliruptive stage [10].

In the pseudohypopyon stage, a horizontal level of the yellowish vitelliform material is seen in the inferior part of the lesion in the subretinal space. Above this level of vitelliform material, the lesion contains relatively transparent fluid [3]. The cause of these egg yolk-like yellowish deposits is unknown, but it may be due to unphagocytosed outer segments that accumulate because of the lack of apposition of the outer membrane segments to the RPE [12]. These deposits, that are so characteristic of BD, are not exclusive. Spaide et al. [13] after examining the autofluorescence and Optical Coherence Tomography (OCT) findings in patients with CSC suggested that these patients had OCT evidence of accumulating autofluorescent material on the outer surface of the retina in areas of retinal detachment, and this material became increasingly thick and autofluorescent with the duration of disease [13].

As for the subretinal fluid, the differential diagnosis is broad, but most common etiologies include central serous chorioretinopathy, neovascular age-related macular degeneration, and polypoidal choroidal vasculopathy [14]. Given the age of our patient and the lack of evidence of neovascular membrane in the multimodal imaging, age-related macular degeneration and polypoidal choroidal vasculopathy were excluded. Therefore, chronic CSC was the main differential diagnosis.

Although the basic defect in BD, as we mentioned, is related to an abnormal channel in the RPE and thus may differ from the underlying etiologic cause of Central Serous Chorioretinopathy (CSC), the presence of subretinal fluid in BD may be the reason why some patients with Best disease are misdiagnosed of chronic CSC [12,14]. Before the establishment of a correct diagnosis, some patients have undergone unsuccessful treatments, including photodynamic therapy and antiangiogenic intravitreal injections [12,14].

In our case, the patient hadn't received any previous treatment. She had been initially diagnosed by her general ophthalmologist of chronic CSC based on the retinal fundus examination. In her first visit in our retina department, the presence of macular subretinal fluid was confirmed in both eyes on OCT. However, the presence of typical vitelliform macular dystrophy findings, aside from subretinal fluid, in her examination and in the multimodal imaging of the retina made us question the diagnosis of CSC. Moreover, she had family history of undetermined macular disease.

Chung and Spaide [15] observed two patterns of autofluorescence in BD, including a spokelike/fractal pattern and a diffuse hyperautofluorescent pattern. Shortly after, Spaide et al. [16] described the FAF in more advanced lesions of BD as a loss of autofluorescence centrally with an increased amount of autofluorescence at the outer border of the ovoid lesion, which was usually asymmetrically distributed around the center of the macula. We observed a similar FAF in our patient since it showed central hypoautofluorescence surrounded by a ring of bright hyperautofluorescent spots.

In cases of CSC, as the disease, state progresses both hyperautofluorescence or hypoautofluorescence can be seen in FAF,

but it is uncommon to find an overall decrease in autofluorescence in the center with an increase in autofluorescence at the border of the serous retinal detachment [12]. Von Rückmann et al. [17], described the autofluorescence in chronic CSC to be very irregular, with regions with greater levels of autofluorescence than the background levels of fluorescence and others with less.

In the fluorescein angiography of our case, intense staining of the subretinal fibrosis was demonstrated with no evidence of leaks at the level of the RPE; such leaks are normally seen in acute cases of CSC [18]. In chronic forms of CSC, diffuse RPE defects give place to multifocal leakage points that are visible in the mid- and late phases as patchy, granular hyperfluorescence [19].

Optical Coherence Tomography (OCT) imaging in our patient confirmed the presence of subretinal deposit and serous retinal detachment as well as a bilateral Pigment Epithelial Detachment (PED) in the central macula.

Some eyes with Best disease may show serous macular detachment in the absence of CNV in both early and late lesions [16]. The subretinal fluid may elevate the retina away from the RPE, making phagocytosis of the outer segments less likely to occur, in a process analogous to that seen in CSC [16].

As for the vitelliform material, its exact location-whether below, above or inside the RPE has not yet been determined [20].

The most typical optical coherence tomography features include vitelliform material, disruption and atrophy of the outer retinal layers, and fibrotic nodules under the RPE [21]. Nevertheless, no study has had sufficient number of patients to try to determine the OCT findings systematically according to the specific stage of BVMD.

The phenotype and the electrophysiology tests of our patient were consistent with bilateral Best disease. Accordingly, the results of the genetic study performed 3 years after our patient's first visit showed that she was heterozygous for c.324CG (p. Ser 108Arg), a likely pathogenic variant in the BEST1 gene. This variant has been previously reported in a single patient of 26 years old with Best's vitelliform macular dystrophy [5]. The ocular phenotype description and the images provided of this patient [5] are similar to ours and are both consistent with bilateral BVMD since the authors also found upon examination a yellowish bilateral dome-shaped lesion in the inferior perifoveal area surrounded by diffuse RPE abnormalities [5].

Furthermore, it should be noted that a more recent family study has classified this variant as likely pathogenic, since it has been identified in an affected family, although without data on family segregation or functional studies to support this classification [22]. Therefore, together with our patient, there are reported three unrelated probands from different families with BVMD phenotype that harbor this BEST1 variant. In addition, the fact that the variant is in the N-terminal domain, where most pathogenic variants are found, further supports its pathogenicity.

Traditionally, the diagnosis of Best vitelliform macular disease was based on the presence of abnormalities at the EOG and the appearance of the vitelliform lesions in childhood or adolescence. However, there have been occasional reports of 'normal' EOG responses in individuals with BD [23,24] and there is also variability

in the age of disease presentation, with some BD patients being diagnosed in adulthood [3]. For this reason, it has been recently proposed that individuals with macular vitelliform lesions carrying mutations in BEST1 should be classified as affected by BD [8].

We present this case report with the conviction that these findings will contribute to add new evidence supporting the pathogenicity of this variant and expand the mutation spectrum of BEST1 in order to improve genetic counselling.

## References

- Petrukhin K, Koisti MJ, Bakall B, et al. Identification of the gene responsible for best macular dystrophy. *Nat Genet.* 1998; 19: 241-247.
- Stone EM, Nichols BE, Streb LM, Kimura AE, Sheffield VC. Genetic linkage of vitelliform macular degeneration (Best's disease) to chromosome 11q13. *Nat Genet.* 1992; 1: 246-250.
- Boon CJ, Klevering BJ, Leroy BP, Hoyng CB, Keunen JE, den Hollander AI. The spectrum of ocular phenotypes caused by mutations in the BEST1 gene. *Prog Retin Eye Res.* 2009; 28: 187-205.
- Kaden TR, Tan AC, Feiner L, Freund KB. Unilateral Best Disease: A Case Report. *Retin Cases Brief Rep.* 2017; 11: S191-S196.
- Frezer V, Iarossi G, Salvetti AP, Maltese PE, Delledonne G, Oldani M, et al. Pathogenicity of new BEST1 variants identified in Italian patients with best vitelliform macular dystrophy assessed by computational structural biology. *Journal of Translational Medicine.* 2019; 17.
- Best F. Ueber eine hereditäre Maculaaffektion: beiträge zur Vererbungslehre. *Z Augenheilkd.* 1905; 13: 199-212.
- Lin Y, Li T, Ma C, et al. Genetic variations in Bestrophin 1 and associated clinical findings in two Chinese patients with juvenile onset and adult onset best vitelliform macular dystrophy. *Mol Med Rep.* 2018; 17: 225-233.
- Johnson AA, Guziewicz KE, Lee CJ, Kalathur RC, Pulido JS, Marmorstein LY, et al. Bestrophin 1 and retinal disease. *Prog Retin Eye Res.* 2017; 58: 45-69.
- Arora R, Khan K, Kasilian ML, Strauss RW, Holder GE, Robson AG, et al. Unilateral BEST1-Associated Retinopathy. *Am J Ophthalmol.* 2016; 169: 24-32.
- Altschwager P, Ambrosio L, Swanson EA, Moskowitz A, Fulton AB. Juvenile Macular Degenerations. *Semin Pediatr Neurol.* 2017; 24: 104-109.
- Booij JC, Boon CJ, van Schooneveld MJ, ten Brink JB, Bakker A, de Jong PT, et al. Course of visual decline in relation to the Best1 genotype in vitelliform macular dystrophy. *Ophthalmology.* 2010; 117: 1415-1422.
- Lee YS, Kim ES, Kim M, Kim YG, Kwak HW, Yu SY. Atypical vitelliform macular dystrophy misdiagnosed as chronic central serous chorioretinopathy: case reports. *BMC Ophthalmol.* 2012; 12: 25.
- Spaide RF, Klancnik JM Jr. Fundus autofluorescence and central serous chorioretinopathy. *Ophthalmology.* 2005; 112: 825-833.
- Lin CF, Sarraf D. Best disease presenting as a giant serous pigment epithelial detachment. *Retin Cases Brief Rep.* 2014; 8: 247-250.
- Chung JE, Spaide RF. Fundus autofluorescence and vitelliform macular dystrophy. *Arch Ophthalmol.* 2004; 122: 1078-1079.
- Spaide RF, Noble K, Morgan A, Freund KB. Vitelliform macular dystrophy. *Ophthalmology.* 2006; 113: 1392-1400.
- von Rückmann A, Fitzke FW, Fan J, Halfyard A, Bird AC. Abnormalities of fundus autofluorescence in central serous retinopathy. *Am J Ophthalmol.* 2002; 133: 780-786.
- Burumcek E, Mudun A, Karacorlu S, Arslan MO. Laser photocoagulation for persistent central serous retinopathy: results of long-term follow-up. *Ophthalmology.* 1997; 104: 616-622.
- Yannuzzi LA, Shakin JL, Fisher YL, Altomonte MA. Peripheral retinal detachments and retinal pigment epithelial atrophic tracts secondary to central serous pigment epitheliopathy. *Ophthalmology.* 1984; 91: 1554-1572.
- Querques G, Regenbogen M, Quijano C, Delphin N, Soubrane G, Souied EH. High-definition optical coherence tomography features in vitelliform macular dystrophy. *Am J Ophthalmol.* 2008; 146: 501-507.
- Battaglia Parodi M, Iacono P, Romano F, Bandello F. Spectral domain optical coherence tomography features in different stages of Best Vitelliform Macular Dystrophy. *Retina.* 2018; 38: 1041-1046.
- Sharon D, Ben-Yosef T, Goldenberg-Cohen N, Pras E, Gradstein L, Soudry S, et al. A nationwide genetic analysis of inherited retinal diseases in Israel as assessed by the Israeli inherited retinal disease consortium (IIRDC). *Hum Mutat.* 2020; 41: 140-149.
- Caldwell GM, Kakuk LE, Griesinger IB, et al. Bestrophingene mutations in patients with Best vitelliform macular dystrophy. *Genomics.* 1999; 58: 98-101.
- Testa F, Rossi S, Passerini I, et al. A normal electro-oculography in a family affected by best disease with a novel spontaneous mutation of the BEST1 gene. *Br J Ophthalmol.* 2008; 92: 1467-1470.