

Case Report

Renal Lymphoma Revealed by Colic Nephritis

Baldé S^{1*}, Sow ML¹, Elm'hadi C¹, Bellahammou K¹, Amine S², Ettahri H¹, Abdellatif K², Ghissassi BE¹, Boutayeb S¹, Rabti HM¹ and Errihani H¹

¹Department of Medical Oncology, National Institute of Oncology-Rabat, Morocco

²Department of Urology B, Hospital IBN Sina-Rabat, Morocco

***Corresponding author:** Salif Baldé, Department of Medical Oncology, National Institute of Oncology-Rabat, Morocco

Received: October 13, 2017; **Accepted:** December 06, 2017; **Published:** December 13, 2017

Case Presentation

Lymphomas are malignant proliferation of cells derived from lymphoid tissue: lymphocytes, histocytes and precursors. The kidney is the second extra-ganglionic localization of lymphomas after the lung. The median age of onset is 6th decade. We report the case of a primary non-Hodgkin's lymphoma of the kidney revealed by a renal biopsy in a 48-year-old patient.

Observation

Mrs. D. F. is a 48-year-old man, had Hypertension under diet alone and consulted for a nephritic colic evolving during 2 months of duration associated with alteration of general health. The clinical examination found a sensitivity of the left flank. Renal ultrasound showed a large left kidney 18x7.5 cm heterogeneous hypo-echogenic: Infectious process? Tumor process?

The biological check up: hemoglobin at 10.4g/dl, white blood cells at 6330cells/mm³, platelets at 256000, urea at 0.42g/l, serum creatinine at 9.9mg/l, uric acid at 69mg/l, LDH at 875. Uro-scan showed a voluminous tumor process of the left kidney very extensive locally having intimate contact with the vascular structures (aorta++) and associated with Locoregional lymphadenopathy (Figures 1-3). A histopathological and immuno-histochemical profile showed a large cell diffuse lymphoma of non-germinal center type with CD20+, CD5-, CD10-, Cytokeratins -, Bcl2+, MUM1+ and Ki67 at 90% (Figures 4-6).

The extension check-up was negative

CT cervico-thoraco-abdomino-pelvic showed left renal process of 105x132x185 mm with extension in casting, absence of suspicious lesion on diaphragmatic. Osteo medullary biopsy: Marrow is reactionary-type and free from lymphomatous infiltrate.

Conclusion

This is a non-Hodgkin's malignant lymphoma of large cells non-germinal type, grade IE renal of the Ann Arbor classification. The therapeutic strategy was to treat with R-CHOP type of chemotherapy. After 04 cycles a PET-CT at 18 FDG revealed the persistence of pathological carbohydrate hyper-metabolism in the left peri-renal residual mass, having significantly decreased in size compared

Abstract

Lymphomas are malignant proliferation of cells derived from lymphoid tissue: lymphocytes, histocytes and precursors. The kidney is the second extra-ganglionic localization of lymphomas after the lung.

We report the case of a primary non-Hodgkin's lymphoma of the kidney revealed by a renal biopsy in a 48-year-old patient.

Keywords: Lymphocytes; Radiotherapy; Chemotherapy

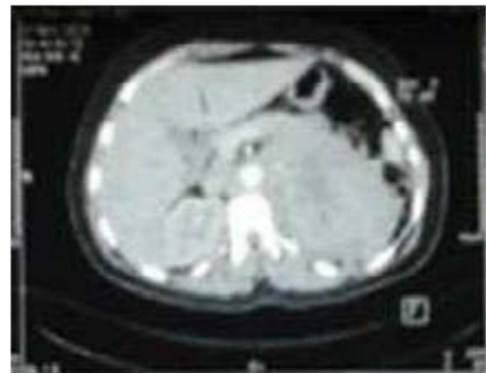


Figure 1:

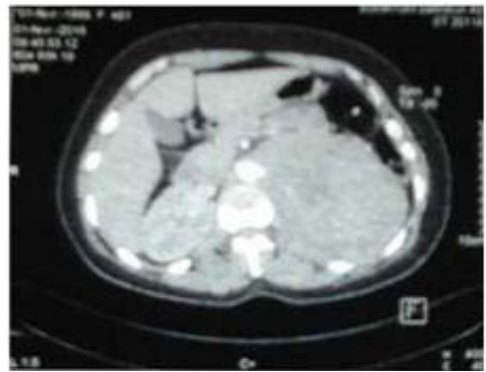

Figure 2:

with earlier CT images. Absence of a suspected lesion otherwise, identifiable to date. The patient received another 02 cycles with an excellent response by the Pet-scan and the patient was lost.

Discussion

Lymphomatous involvement of the kidney is uncommon. It is often secondary by direct extension from retroperitoneal lymph nodes or haematogenous by pathway [5]. Primary renal lymphoma (free kidney drainage lymph nodes and negative extension) is rare; only about thirty cases have been reported to date [2,3,10,14]. Some

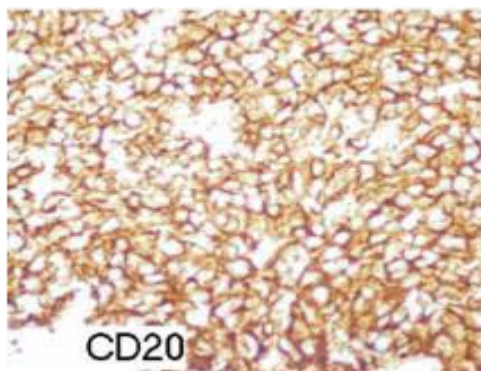


Figure 3:

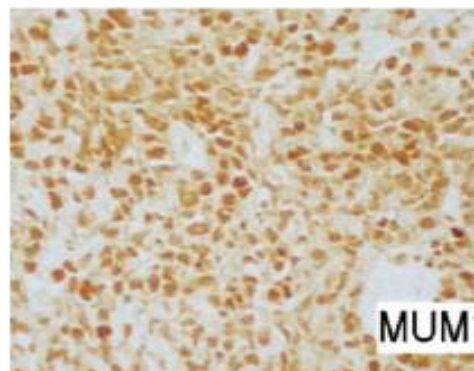


Figure 5:

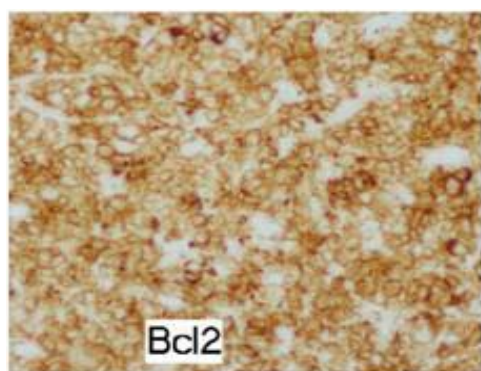


Figure 4:

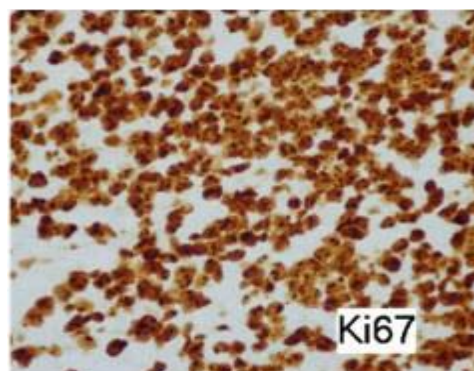


Figure 6:

authors [8], however, question this primitive localization because normally the kidney is devoid of its own lymphoid structure. Some hypotheses have been put forward to explain such localization: The first hypothesis evoked is that which supposes the formation of lymphoid follicles from a renal parenchymatous inflammatory process [9]. The authors of this theory make a similarity with the gastric lymphomas of the type MALT (Mucosa Associated Lymphoma T) occurring on chronic gastritis with helicobacter pylori [10]. The second hypothesis invokes parenchymal invasion from the renal capsule rich in lymphatic vessels [2]. The clinical symptomatology is not specific and corresponds to that of a usual renal tumor [1,4,10]. On the radiological level, the tomodensitometric aspect is sometimes evocative. Classically the lymphoma appears as a solid mass of tissue density, the mass increases slightly after injection of the contrast agent contrary to the adenocarcinoma [11]. Other aspects may be encountered, multiple nodules, renal infiltration and peri-renal infiltration of contiguity from retroperitoneal lymph nodes in secondary renal lymphoma [5]. In fact, no radiological examination makes it possible to differentiate renal lymphoma from an adenocarcinoma, only the anatomopathological examination will provide diagnostic certainty. Diagnosis of primary renal non-Hodgkin's malignant lymphoma can be one of the few indications of ultrasound or CT- scan guided renal biopsy diagnosis [7,12]. In addition to the diagnostic approach, the biopsy puncture may conditioning the subsequent therapeutic conduct: primary chemotherapy or surgical resection with complementary radio-chemotherapy [7,8]. In case of negative puncture, an extemporaneous

biopsy can be discussed. Histologically, there are several classifications of malignant non-Hodgkin's lymphomas; the most used is the classification of kiel [15] which takes into account the degree of malignancy of lymphoma [15]. The majority of renal lymphomas are large B-cells phenotypes of high grade malignancies or intermediate malignancies [6]. The treatment of primary renal lymphoma is based on surgical resection, chemotherapy and/or radiotherapy [1,7,10,13]. The surgery will consist of an enlarged total nephrectomy associated with lymph node dissection. Chemotherapy improves patient survival and reduces the frequency of the recurrences. It also makes it possible to reduce the indications of the surgical resection in the case of preoperative diagnosis of the lymphoma by puncture biopsy of the tumor under ultrasound or CT scan guidance [8,11]. Most commonly used protocol is CHOP (cyclophosphamide, doxorubicin, vincristine, and prednisone). Radiotherapy is proposed by some authors in addition to surgery and/or chemotherapy on residual tumor remnants and in case of recurrence [7,11]. Regarding indications, there is no standard therapeutic strategy because of the small number of cases of primitive renal lymphomas listed. Nevertheless, according to the literature, a therapeutic regimen can be proposed: While the treatment of secondary lymphomas is based on polychemotherapy, the attitude towards primary renal lymphoma depends on the Circumstances of the diagnosis, malignancy and evolutivity of lymphoma; If the lymphoma is a preoperative discovery by a percutaneous or per-operative biopsy by an extemporaneous examination, polychemotherapy is the treatment of choice. In the absence of preoperative diagnosis, loco regional treatment by

enlarged total nephrectomy with dissection becomes predominant. The indication of adjuvant chemotherapy and/or radiotherapy will be dictated by the degree of malignancy of the lymphoma and the quality of the initial excision. The prognosis of the primary renal lymphomas is conditioned by age, stage, tumor grade, tumor volume and histological type. Complete and prolonged responses have been obtained by the combination of surgery and chemotherapy with survival of more than 10 years for some cases [8,9].

Conclusion

Primary renal lymphoma is a rare tumor. The preoperative diagnosis remains difficult because the radiological and clinical criteria are not specific. Chemotherapy represents the treatment of choice especially in the forms of high grade malignancy.

References

1. Benchekroun, Belahnech Z, Benslimane I, Farih my h. Les lymphomes du rein. *Prog. Urol.* 1991; 1: 593-599.
2. Betta PG, Bottero G, Cosimi MF, Musante F. Primary renal lymphoma. *Eur. Urol.* 1986; 12: 352-354.
3. Dimopoulos MA, Mouloupoulos LA, constantinides C, Deliveliolis C, Pantazopoulos D, Dimopoulos C, et al. Primary renal lymphoma: a clinical and radiological study *J. Urol.* 1996; 155: 1865-1867.
4. Dufau JP, patte JH, Ceccaldi B, Fagot T, Sylvestre A, Vagueresse R. Lymphome non hodgkinien simulant un carcinome rénal à propos d'un cas de lymphome folliculaire. *Ann. Pathol.* 2000; 20: 253-257.
5. Eble J. Tumors of the Kidney. *Semin. Diagn. Pathol.* 1998; 15: 1-82.
6. Falconieri G, Melato M. Malignant lymphoma presenting as an isolated renal mass. *Histopathology.* 1988; 12: 217-219.
7. Gellrich J, Hakenberg OW, Naumann R, Wirth MP: Primary renal non Hodgkins lymphoma: a difficult differential diagnosis. *Onkologie.* 2002; 25: 273-277.
8. Harris GJ, Lager DJ. Primary renal lymphoma. *J. Surg. Oncol.* 1991; 46: 273-277.
9. Kandel LB, McCullogh DL, Harrison LH, Woodruff RD, Ahl ET, Munitz HA, et al. Primary renal lymphoma: does it exist ? *Cancer.* 1987; 60: 386-391.
10. Okuno SH, Hoyer ID, Ristow K, Witzig E. Primary renal non hodgkin's lymphoma: an unusual extranodal site. *Cancer.* 1995; 75: 2258-2261.
11. Osborne BM, brenner M, Weitzner S, Butler JJ. Malignant lymphoma presenting as a renal mass: four cases. *Am. J. Surg. Pathol.* 1987; 11: 375-382.
12. Pervez H, Shaikh m, Potti A, Mehdi SA. Uncommon presentations of non-hodgkin's lymphoma: case 3, primary renal lymphoma. *J. Clin-Oncol.* 2000; 21: 567-569.
13. Poullos C. Primary renal non-hodgkin lymphoma. *Scand. J. Urol. Nephrol.* 1990; 24: 227-230.
14. Stallone G. Primary renal lymphoma does exist: case report and review of the literature. *J. Nephrol.* 2000; 13: 367-372.
15. Stansfeld AG, Diebold J, kapanci y. Updated Kiel calssification for lymphomas. *Lancet.* 1988; 1: 292-294.