

Special Article – Metastatic Lung Cancer

Complete Remission and Extended Survival in a Patient with Recurrent and Metastatic Non-Small Cell Lung Cancer-A Case Report

Manje Gowda A^{1*}, Kaur S², Bansal R¹ and Maroules M²

¹Department of Internal Medicine, New York Medical College at St. Joseph's Regional Medical Center, New Jersey, USA

²Department of Hematology Oncology, St. Joseph's Regional Medical Center, New Jersey, USA

*Corresponding author: Anusha Manje Gowda, Department of Internal Medicine, New York Medical College at St. Joseph's Regional Medical Center, New Jersey, USA

Received: September 26, 2017; Accepted: October 17, 2017; Published: October 24, 2017

Abstract

Non-small cell cancer of the lung is an aggressive malignancy with a poor prognosis when it presents at an advanced stage. We report the case of a 51-year-old Hispanic female who was initially diagnosed with stage 2 adenocarcinoma of the right lung for which she underwent curative treatment with lobectomy and post-operative chemotherapy. However, the course of the disease was complicated by recurrence of the primary tumor and progression with development of multiple, recurrent brain and spinal metastases, despite receiving different lines of chemotherapy. The tumor was positive for epidermal growth factor receptor and she was started on erlotinib, an epidermal growth factor receptor-tyrosine kinase inhibitor. She achieved complete remission and has been free of the disease for the past 3 years with a prolonged survival of nearly 8 years since the initial diagnosis, which is the longest reported so far known to us.

Keywords: Recurrent non-small cell lung cancer; Metastatic lung adenocarcinoma; Brain metastases, Epidermal growth factor receptor-tyrosine kinase inhibitors

Abbreviations

NSCLC: Non-Small Cell Lung Cancer; EGFR-TKIs: Epidermal Growth Factor Receptor- Tyrosine Kinase Inhibitors; PFS: Progression Free Survival; OS: Overall Survival

Case Presentation

A 51-year-old Hispanic female who was a non-smoker and with no past medical history was diagnosed with stage 2 adenocarcinoma of the right upper lobe in May 2009. Her initial Computed Tomography (CT) of the chest showed a lobulated 3 cm lesion in right upper lobe (Figure 1). She subsequently underwent right upper lobectomy and was treated with carboplatin and paclitaxel chemotherapy post-operatively. Eight months later, brain metastases were detected in the left frontal lobe (Figure 2), for which she underwent resection of the lesion along with gamma knife radiation. She was then started on erlotinib due to EGFR positive status of the tumor which had to be discontinued after a short duration due to severe diarrhea from erlotinib. The subsequent course of her disease was complicated by multiple recurrences. She had a relapse with a T5 spinal lesion in 2011 for which she underwent radiation to the spine. She was also found to have recurrent brain metastases with a new lesion in the right occipital lobe that was treated with whole-brain irradiation. In August 2013, she had another recurrence in the right upper lobe for which she underwent 5 cycles of palliative chemotherapy with gemcitabine. However, PET (Positron Emission Tomography) scan done in December 2013, showed a new tumor in the left upper lobe. Around the same time, MRI of the brain revealed the progression of her frontal lobe metastatic lesion. Due to the progression of her disease, she received vinorelbine from December 2013 to July 2014. She was

then restarted on erlotinib at a lower dose, which she tolerated well. Serial PET scans since March 2015 has shown no recurrence of her disease. The patient is regularly following up in our oncology clinic and her disease has not recurred for nearly 3 years. She is currently free of symptoms and erlotinib was stopped in February 2017.

Discussion

Non-Small Cell Cancer (NSCLC) of the lung is an aggressive malignancy with a poor prognosis when diagnosed at an advanced stage [1,2]. Most patients who develop metastatic disease die within a year of diagnosis [2]. We report a case of advanced non-small lung cancer with multiple recurrences despite receiving different lines of chemotherapy, who eventually achieved complete remission, which is a very rare phenomenon.

The median overall survival in metastatic NSCLC with chemotherapy is 8 to 12 months and a median Progression-Free Survival (PFS) is 5 to 6 months [1,2]. With the advent of targeted therapies such as EGFR-Tyrosine Kinase Inhibitors (EGFR-TKIs), the median PFS has been prolonged to an average of 10 to 14 months, and an overall survival of 20 to 30 months [2-6].

Complete regression of cancer has been reported in certain malignancies, when accompanied by infection, fever, radiation, trauma or surgery which may play a role in triggering an immune response [7-10]. This phenomenon has led to an understanding of the immunity against cancer cells; mechanisms such as apoptosis, immunological modulation through the release of cytokines such as interleukin-2, angiogenesis inhibition, telomerase inhibition and antitumor antibodies can play a role in regression of cancer [11-13].

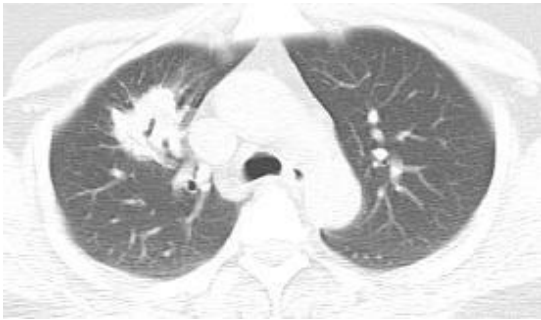


Figure 1: Initial CT of the chest with contrast showing a lobulated lesion in right upper lobe measuring approximately 3 cm in the greatest diameter.

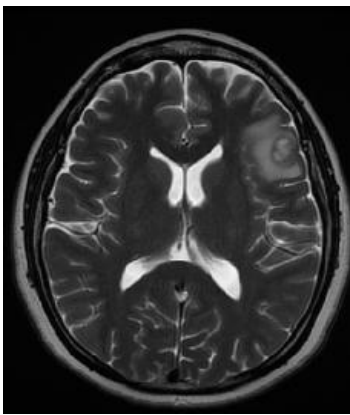


Figure 2: MRI of the brain with contrast enhancement showed an enhancing lesion in the left frontal lobe at the gray-white junction with mild perilesional edema measuring 1.3 x 1.5 x 1.1 cm suggestive of metastatic disease.

The advent of EGFR-TKIs has changed the course of the treatment of lung cancer. Erlotinib inhibits tyrosine phosphorylation by blocking the intracellular ATP (Adenosine Tri Phosphate) binding site of epidermal growth factor receptor [14]. It has been studied to be more effective with a better PFS and OS in NSCLC patients who have previously received platinum chemotherapy [15]. It has also been shown to be remarkably effective as a second or third-line treatment in combination with docetaxel and pemetrexed chemotherapy [16]. When used as a second or third-line treatment, erlotinib resulted in minimum side effects, such as dysentery and minor skin irritations [17]. EGFR-TKIs have the ability to cross the blood-brain barrier due to their chemical structure and low molecular weight and hence they are efficacious in the treatment of brain metastasis [18]. A prolonged 5-year survival with EGFR-TKIs has been associated with presence of exon 19 deletions, absence of extra thoracic or brain metastasis, good performance status and in non-smokers [19].

We found two other reported cases of complete regression of the tumor and a prolonged survival after treatment with multiple lines of chemotherapy, similar to our case. Suzuki E *et al.* [20] reported a case of a 53-year-old woman with EGFR positive left lung adenocarcinoma with bone metastases to the skull and thoracic vertebrae. She received carboplatin plus paclitaxel and bevacizumab therapy and radiation to the thoracic vertebrae. Repeat imaging showed a good response to chemotherapy and she was started on EGFR tyrosine kinase inhibitor. The patient reportedly survived 52 months from the initial diagnosis.

Chonan M *et al.* [21] described two patients with brain metastasis from EGFR positive non-small cell lung cancer, who achieved a complete regression of metastasis with the administration of gefitinib. One was a 70-year-old Japanese female who was treated with gefitinib for one month after which the primary lesion and brain metastasis completely resolved. The other case was a 58-year-old Japanese female with a metastatic lesion in the left cerebellar hemisphere and meningeal dissemination. She was treated with gefitinib for 3 weeks after which her disease completely resolved. In both these cases, the complete resolution occurred within a short period [21]. Our patient has survived nearly 8 years since the time of initial diagnosis and has been disease-free for nearly 3 years.

Conclusion

Most cases reported describe either spontaneous regression or regression in patients with a single recurrence of the disease. Very few cases of complete regression of recurrent and metastatic lung cancer have been reported. Our patient had multiple recurrences of the primary lung lesion and developed brain metastases on multiple lines of chemotherapy, but showed an excellent response to EGFR-TKI, achieving a complete radiological remission with a prolonged survival of nearly 8 years since initial diagnosis, which is the longest reported so far known to us.

References

- Schiller JH, Harrington D, Belani CP, Langer C, Sandler A, Krook J, *et al.* Comparison of four chemotherapy regimens for advanced non-small-cell lung cancer. *N Engl J Med.* 2002; 346: 92-98.
- Lin JJ, Cardarella S, Lydon CA, Dahlberg SE, Jackman DM, Jänne PA, *et al.* Five-Year Survival in EGFR-Mutant Metastatic Lung Adenocarcinoma Treated with EGFR-TKIs. *J Thorac Oncol.* 2016; 11: 556-565.
- Mok TS, Wu YL, Thongprasert S, Yang CH, Chu DT, Saijo N, *et al.* Gefitinib or carboplatin-paclitaxel in pulmonary adenocarcinoma. *N Engl J Med.* 2009; 361: 947-957.
- Rosell R, Carcereny E, Gervais R, Vergnenegre A, Massuti B, Felip E, *et al.* Erlotinib versus standard chemotherapy as first-line treatment for European patients with advanced EGFR mutation-positive non-small-cell lung cancer (EURTAC): a multicenter, open-label, randomised phase 3 trial. *Lancet Oncol.* 2012; 13: 239-246.
- Zhou C, Wu Y-L, Chen G, Feng J, Liu XQ, Wang C, *et al.* Erlotinib versus chemotherapy as first-line treatment for patients with advanced EGFR mutation-positive non-small-cell lung cancer (OPTIMAL, CTONG-0802): a multicentre, open label, randomized, phase 3 study. *Lancet Oncol.* 2011; 12: 735-742.
- Mitsudomi T, Morita S, Yatabe Y, Negoro S, Okamoto I, Tsurutani J, *et al.* Gefitinib versus cisplatin plus docetaxel in patients with non-small-cell lung cancer harbouring mutations of the epidermal growth factor receptor (WJTOG3405): an open label, randomised phase 3 trial. *Lancet Oncol.* 2010; 11: 121-128.
- Wiernik PH. Spontaneous regression of hematologic cancers. *Natl Canc Inst Monogr.* 1976; 44: 35-38.
- Kumar T, Patel N, Talwar A. Spontaneous regression of thoracic malignancies. *Respir Med.* 2010; 104: 1543-1550.
- Leo F, Nicholson AG, Hansell DM, Corrin B, Pastorino U. Spontaneous regression of large-cell carcinoma of the lung--a rare observation in clinical practice. *Thorac Cardiovasc Surg.* 1999; 47: 5-55.
- Cafferata MA, Chiamondia M, Monetti F, Ardizzone A. Complete spontaneous remission of non-small-cell lung cancer: a case report. *Lung Cancer.* 2004; 45: 263-266.
- Iwakami S, Fujii M, Ishiwata T, Iwakami N, Hara M, Ihara H, *et al.* Small-cell

- lung cancer exhibiting spontaneous regression. *Intern Med.* 2013; 52: 2249-2252.
12. Isobe M, Eikawa S, Uenaka A, Nakamura Y, Kanda T, Kohno S, *et al.* Correlation of high and decreased NY-ESO-1 immunity to spontaneous regression and subsequent recurrence in a lung cancer patient. *Cancer Immun.* 2009.
 13. Chung C, Park DI, Kim SY, Kim JO, Jung SS, Park HS, *et al.* Spontaneous regression of non-small cell lung cancer that progressed after multiple chemotherapies: A case report. *Thorac Cancer.* 2015; 6: 805-807.
 14. Clark GM, Zborowski DM, Santabarbara P, Ding K, Whitehead M, Seymour L, *et al.* Smoking history and epidermal growth factor receptor expression as predictors of survival benefit from erlotinib for patients with non-small-cell lung cancer in the National Cancer Institute of Canada Clinical Trials Group study BR.21. *Clin Lung Cancer.* 2006; 7: 389-394.
 15. Syrigos KN, Saif MW, Karapanagiotou EM, Oikonomopoulos G, De Marinis F. The need for third-line treatment in non-small cell lung cancer: an overview of new options. *Anticancer Res.* 2011; 31: 649-659.
 16. Ng R, Loreto M, Lee R, Leighl NB. Brief report: retrospective review of efficacy of erlotinib or gefitinib compared to docetaxel as subsequent line therapy in advanced non-small cell lung cancer (NSCLC) following failure of platinum-based chemotherapy. *Lung Cancer.* 2008; 61: 262-265.
 17. Shepherd FA, Rodrigues PJ, Ciuleanu T, Tan EH, Hirsh V, Thongprasert S, *et al.* Erlotinib in previously treated non-small-cell lung cancer. *N Engl J Med.* 2005; 353: 123-132.
 18. Cappuzzo F, Ardizzoni A, Soto-Parra H, Gridelli C, Maione P, Tiseo M, *et al.* Epidermal growth factor receptor targeted therapy by ZD 1839 (Iressa) in patients with brain metastases from non-small cell lung cancer (NSCLC). *Lung Cancer.* 2003; 41: 227-231.
 19. Lin JJ, Cardarella S, Lydon CA, Dahlberg SE, Jackman DM, Janne PA, *et al.* Five-Year Survival in EGFR-Mutant Metastatic Lung Adenocarcinoma Treated with EGFR-TKIs. *J Thorac Oncol.* 2016; 11: 556-565.
 20. Suzuki E, Tanahashi M, Yukiue H, Yoshii N, Shitara M, Fujino T, *et al.* A Patient with Lung Adenocarcinoma, Lymphangitis Carcinomatosa, and Multiple Bone Metastases Who Achieved Long-Term Survival after Successful Treatment with Carboplatin, Paclitaxel, and Bevacizumab. *Gan To Kagaku Ryoho.* 2016; 43: 617-620.
 21. Chonan M, Narita N, Tominaga T. Total regression of brain metastases in non-small cell lung cancer patients harboring EGFR mutations treated with gefitinib without radiotherapy: two case reports. *BMC Res Notes.* 2016; 9: 2.