

Case Report

An Endodermal Sinus Tumor of the Ovary Diagnosed in Pregnancy

Chauhan A*

Gobal Hospital, A Division of Gobal Longlife Hospital & Research Pvt. Ltd, India

***Corresponding author:** Anjana Chauhan, Gobal Hospital, A Division of Gobal Longlife Hospital & Research Pvt. Ltd, Ahmedabad, Gujarat, India**Received:** June 29, 2017; **Accepted:** September 25, 2017; **Published:** October 02, 2017**Abstract**

A successful outcome of a woman presenting with five months of pregnancy & endodermal sinus tumor of ovary, managed by fertility preserving surgery & BEP-chemotherapy.

A 24 year primipara woman presented with five months of pregnancy and pelvic mass in January 2008. Patient was diagnosed to have endodermal sinus tumor of the ovary. After informed consent, regarding risk to pregnancy, she was planned for staging laparotomy. Intraoperative there was 15x20cm solid to cystic tumour arising from the left ovary. She underwent removal of ovarian tumor, infracolic omentectomy and left side ipsilateral retroperitoneal pelvic lymphadenectomy. She had no residual disease. Uterus was enlarged about five months of pregnancy. The opposite right ovary was normal. The uterus and opposite ovary was preserved.

Final Histopathology was endodermal sinus tumor of the ovary. FIGO stage was Ic.

Postoperatively three cycles of BEP (Bleomycin, Etoposide, Cisplatin) chemotherapy was given with intra uterine pregnancy as adjuvant treatment. Chemotherapy was given with consent and explanation of all the consequences and the risk to the pregnancy.

Results: Caesarean-section was done at-term; full-term-IUGR (Intra Uterine Growth Retardation) female child of 1.5kg was delivered. The child showed normal laboratory, pediatric, and neurologic parameters. In 2013 she again conceived and delivered a healthy child. Till date (9 year), the mother and her both child are normal. Her first child is 8 years old, healthy and has all normal parameters.

Conclusion: A rare case of pregnant woman with endodermal sinus tumor of ovary treated successfully with surgery & chemotherapy and delivered a normal baby at-term.

Keywords: Endodermal sinus tumor of the ovary; Pregnancy; BEP chemotherapy

Introduction

Cancer in pregnancy is rare occurrence. An estimated frequency reported is of 0.07-0.1%. The most commonly diagnosed cancers in pregnancy; in descending order of frequency are breast cancer, cervical cancer, melanoma, ovarian cancer, thyroid cancer, leukemia, hodgkin's lymphoma, and colorectal cancer [1].

An increase in the incidence of adnexal masses diagnosed during pregnancy has occurred because of wide use of prenatal ultrasonography during pregnancy. Ovarian tumors occur in 2.4-5.7% of pregnancies. The most common ovarian neoplasms are luteomas of pregnancy and dermoid cyst.

Malignant ovarian tumors are a rare occurrence in pregnancy. Ovarian cancer occurs in one in 15,000 to one in 32,000 pregnancies. Most common are germ cell tumors of ovary, because they are more common in young women, especially in reproductive period. Although dysgerminoma of the ovary represents about 20% of cases

during pregnancy, endodermal Sinus tumor with pregnancy is extremely rare and only few cases reported in the literature [2,3].

This is a case report a successful outcome of a woman presenting with five months of pregnancy & endodermal sinus tumor of ovary, managed by fertility preserving surgery & BEP-chemotherapy.

Case Report

A 24 year primipara woman presented with five months of pregnancy and pelvic mass in January 2008. Her LMP (Last Menstrual Period) was in July 2007 and estimated EDD (Expected Date of Delivery) was in April 2008. FNAC was done from the ovarian mass which reported endodermal sinus tumor of the ovary. On examination her *vital* data was normal but she was anemic. On abdominal examination she had twenty weeks size pregnant uterus with palpable mass over the fundus of the uterus. The mass had restricted mobility. She had no significant findings on per vaginal and per rectal examination. Routine investigations, tumor markers

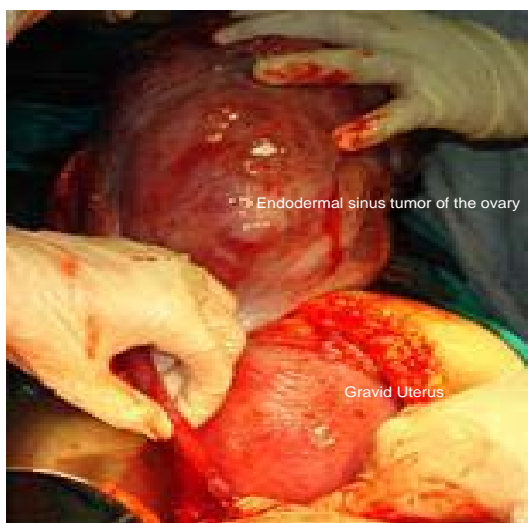


Figure 1: The tumor was about 15X20cm in size, solid to cystic in nature, mobile and situated above the uterus.

and sonography (USG) were done. Her Hemoglobin was 8.5gm%. Tumor markers α -FP (alpha-Fetoprotein) was 10,296ng/ml, CA 125 was 793U/L and LDH was 1092U/L. Her USG showed five months of live intrauterine pregnancy and 12X12 cm solid to cystic complex ovarian mass lesion above the uterus. She was transfused two units of Blood. After informed consent regarding risk to pregnancy, she was planned for staging laparotomy. She was explained the option of fertility preservation, continuation of pregnancy and followed by chemotherapy thereafter.

She underwent staging laparotomy. On exploration the uterus was about five month (22 weeks of gestation) size of pregnancy with tumor arising from the left ovary. The tumor was about 15X20cm in size, solid to cystic in nature, vascular, mobile and situated above the uterus (Figure 1). The opposite right ovary was normal. Rest of the abdominal structures-paraortic region, liver, kidneys, mesentery, small and large bowels etc. were normal. She underwent removal of left ovarian mass, infracolic omentectomy and left side epsilateral retroperitoneal pelvic lymphadenectomy. She had no residual disease. Intraoperative and postoperative she was given tocolytics agents for maintenance of her pregnancy, as advised by Obstetrician. Her postoperative period was uneventful.

Final Histopathology was malignant pure endodermal sinus tumor of ovary. It measured 24cm in greatest diameter and had capsular infiltration of the ovary. The omentum and pelvic nodes were negative for malignancy. According to FIGO staging, it was stages Ic.

After surgery, postoperatively, chemotherapy BEP regimen was planned as an adjuvant treatment. The chemotherapy was given with informed consent and lethal toxic effect on the fetus. Three cycle of BEP chemotherapy was given. The BEP regimen was: Injection Bleomycin 30 unit IV weekly, Injection Etoposide 100mgm/m² IV day 1-5 every three weekly, Injection Cisplatinum 20mgm/m² IV day 1-5 every three weekly. After the first course of chemotherapy, she developed skin rashes due to bleomycin toxicity. Hence in further courses of chemotherapy, bleomycin was omitted. She completed three courses of chemotherapy on March 2008.

Table 1: Adnexal Masses discovered during Pregnancy [8].

Benign	Corpus luteum
	Mature cystic teratomas
	Serous and mucinous cystadenomas
	Endometriomas
	Para ovarian cyst
Borderline	Leiomyomas
	Serous
	Mucinous
Malignant	Endometrioid
	Brenner
	Epithelial Ovarian Cancer (serous, mucinous, endometrioid, clear cell, Brenner)
	Germ Cell Tumors (dysgerminomas, endodermal sinus tumor, immature teratomas)
	Sex cord stromal tumors (granulosa cell, Sertoli-Leydig)

She presented with labour pain in April 2008 and had to undergo caesarean section for foetal distress. Full term IUGR female child of 1.5kg weight was delivered. The child showed normal pediatric and neurological parameters.

Follow-Up

Post delivery her tumor markers were normal. She has been on regular follow-up since then. Her baby was normal, having normal milestone and neurological parameters. In 2013, she again conceived and delivered a healthy child. Till date (9 year), the mother and her both child are normal. Her first child is 8 years old, healthy and has all normal function.

Discussion

The majority of ovarian neoplasms occurring during pregnancy are benign. The incidence reported is less than 10%. Only 2% to 6% of these tumors is malignant. Various types of adnexal masses seen during pregnancy are shown in (Table 1).

Tumor markers are of not must help in evaluating an adnexal mass during pregnancy, as many of them also rise in pregnancy. Such as Ca-125 rises in pregnancy. α -FP is elevated in first trimester of pregnancy and in neural tube defects of the fetus. β -HCG also rises in pregnancy. Hence tumor markers cannot be helpful in diagnosing the nature of the tumors in pregnancy. Commonest tumors, seen are the Dermoid, dysgerminomas and mucinous epithelial tumors [4].

Most of these adnexal masses seen in pregnancy will resolve without intervention, reflecting the physiologic nature of these masses. Ideally the ovarian masses diagnosed during the first trimester should be followed until 16-20 weeks of pregnancy. Presences of adnexal mass beyond 20 weeks of pregnancy are pathological and should be evaluated. With the wide spread use of routine prenatal ultrasound there is increase in incidence of diagnosing adnexal masses during pregnancy, when women are still asymptomatic [4,5]. E. Hassan *et al.* states that the sonographic features of the adnexal masses are very important for diagnosis of the type and consistency of the tumor [6]. If the features of the mass suggests multiloculated cyst, with septum, solid area, ascities, involvement of contralateral ovary, than malignancy should be suspected and the woman should be referred to an oncology center.

The commonest types of ovarian malignancies seen in pregnancy are dysgerminomas, borderline tumors and mucinous cystadenocarcinomas [4]. Management of such cases is difficult due

Table 2: Review of Endodermal Sinus Tumor of Ovary associated with pregnancy.

Reference	Gestational weeks at diagnosis	Stage	Therapy during pregnancy	Gestational weeks at delivery	Therapy after delivery	Outcome of mother	Outcome of fetus
Malone <i>et al.</i> , 1986	25	Ic	RSO PVB 3 courses	32	PVB 3 courses	12 months NED	Healthy
Metz <i>et al.</i> , 1989	13	I	LSO+CPA 5 courses	37	VLB+DXR+CPA 7 courses	12 months NED	Healthy
Rajendran <i>et al.</i> , 1999	19	Ia	RSO	31	BEP 4 courses	12 months NED	Healthy
Van der Zee <i>et al.</i> , 1991	18	I	LSO	33	BEP 4 courses	24 months NED	Healthy
Elit <i>et al.</i> , 1999	23	II	LSO BEP 3 courses	28	BEP 4 courses	16 months NED	Ventriculomegaly
X.Y. ZHAO <i>et al.</i> , 1999	36	I	LSO BEP	31		8 months NED	Healthy
Shimizo <i>et al.</i> ,2003	19	Ic	RSO	36	BEP 3 courses	27 months NED	Healthy
Aoki Y <i>et al.</i> ,2005	30	-	RSO	34 Recurrence	BEP 7 courses	39 months NED	Healthy
Chanu <i>et al.</i> , 2015	20	I	RSO	32	BEP 4 courses	18 NED	Healthy
Present Study 2017	22	Ic	LSO BEP 3 courses	37	nil	NED (9 years) till date	Healthy

to its rarity and complicated by additional consideration like the effect of chemotherapy on the fetus, difficulty in adequately staging the tumors, and the decreased reliability of monitoring disease progression using tumors markers. The surgical approach remains same as for non-pregnant women with ovarian malignancy. The complete staging laparotomy should be performed for early staged ovarian malignancy even in pregnancy. For germ cell malignancies of the ovary, the procedure remains the same. But the gravid uterus and the opposite ovary can be preserved. Rest of the steps of staging laparotomy, like multiple quadrant cytology, removal of the malignant mass, retroperitoneum pelvic node dissection, omentectomy should be done. The extent of surgery can be decided by the intraoperative findings and frozen section report. Usually difficulty is encountered during surgery as the gravid uterus may occupy the whole pelvis especially in second and third trimester of the pregnancy and there is increased vascularity due pregnancy.

Endodermal sinus tumors of ovary are the second most common germ cell tumors, accounting for 20% of all cases.

Usually seen in young girls and young women (the median age: 18 years). It may present with pure or a component of mixed germ cell tumor. It is always a unilateral solid or cystic in nature. Majority of endodermal sinus tumors of ovary produces high levels of α -FP, which is a very effective tumor marker for diagnosis and also to monitor the response of the treatment. Very few cases of pregnancy with endodermal sinus tumor of the ovary are reported [7]. There is no established method for treating pregnancy with endodermal sinus tumor of ovary due to its extreme rarity, so management must be individualized for each woman. Staging laprotomy should be performed whenever women present with such mass in early cases. The most favorable time to perform surgery during pregnancy is in the early second trimester. At this stage the uterus is not yet occupying the entire pelvis, leaving room for adequate exposure of the adnexal and the retroperitoneum. At the same time, the incidence of miscarriage from removal of the ovary containing the corpus luteum is much decreased compared to the first trimester [8].

Endodermal sinus tumors of the ovary are highly aggressive and fastest growing tumor and hence it requires immediate adjuvant chemotherapy after surgery, to prevent relapse. It responds well with

combination chemotherapy with overall all cure rate of more than 90% in early stage. Even Stage Ia, chemotherapy is mandatory.

The prognosis of endodermal sinus tumor of the ovary has improved markedly due to progress in combination chemotherapy, such as the concomitant use of bleomycin, etoposide, and cisplatin [8]. Hence chemotherapy should not be withheld in the pregnancy and should be given with potential and calculated risk. Review of the literature shows very few cases of endodermal sinus tumors of the ovary with pregnancy in the world, treated with surgery and chemotherapy (Table 2).

Chemotherapy during pregnancy requires consideration of the effects on the mother and the fetus. So far, no comparable data are available to determine the long-term effects on individuals who have been exposed to chemotherapy in utero. X.Y.Zhao *et al.* states that the use of chemotherapy during pregnancy should be avoided during the first trimester because most agents are potentially harmful to the fetus at this stage and high rates of abortion [8]. Chemotherapy has been administered during the second and third trimesters for ovarian germ cell malignancies without evidence of any increase in fetal congenital anomalies or other consequences [7]. Several authors have reported that women with malignant germ cell tumors of the ovary have received chemotherapy during pregnancy and delivered normal infants [1,3,7-10].

Conclusion

Hence to conclude, early diagnosis and appropriate treatment offers the best prognosis for the women with endodermal sinus tumor of the ovary during pregnancy. Potentially lifesaving chemotherapy should not be withheld from the pregnant women as these tumors are highly malignant, very aggressive and known to recur very fast. In first trimester of pregnancy, it is advisable to undergo abortion prior to surgery and chemotherapy. And in woman presenting in later weeks of pregnancy surgical debulking, preserving the pregnancy followed by combination chemotherapy if possible is indicated. Choosing of the most appropriate diagnostic and therapeutic strategy must be case dependent, and the couple must be kept fully informed [8]. Management of ovarian mass with pregnancy depends upon the type of tumor, stage, duration of pregnancy & patient's desire.

References

1. Elit L, Bocking A, Kenyon C, Natale R. An endodermal sinus tumor diagnosed in pregnancy: case report and review of literature. *Gynecol Oncol.* 1999; 72: 123-127.
2. Rajendran S, Hollingworth J, Scudamore I. Endodermal sinus tumour of the ovary in pregnancy. *Eur J Gynaecol Oncol.* 1999; 20: 272-274.
3. Shimizu Y, Komiyama S, Kobayashi T, Nakata K, Iida T. Successful management of endodermal sinus tumor of the ovary associated with pregnancy. *Gynecol Oncol.* 2003; 88: 447-450.
4. Ciliby B. The Adnexal Mass. *Clinical Obstetrics and Gynecology.* 2006; 49: 431-548.
5. Morrow CP, Curtin JP, Townsend DE. *Synopsis of Gynecology Oncology, IV Edition.* Churchill Livingstone. 1993.
6. Hassan E, Creatsas G, Deligerorolgo E, Mielfalas S. Ovarian tumor during childhood and adolescence. A clinicopathological study. *Eur J Gynaecol Oncol.* 1999; 20: 124-126.
7. Robova H, Rob L, Hrehorcak M, Zoban P, Prusa R. Endodermal sinus tumor diagnosed in pregnancy: a case report. *Int J Gynecol Cancer.* 2007; 17: 914-916.
8. Zhao XY, Haung HF, Lian LJ, Lang JH. Ovarian cancer in pregnancy: a clinicopathologic analysis of 22 cases and review of the literature. *Int J Gynecol Cancer.* 2006; 16: 8-15.
9. Aoki Y, Higashino M, Ishii S, Tanaka K. Yolk sac tumor of the ovary during pregnancy: a case report. *Gynecol Oncol.* 2005; 99: 497-499.
10. Chanu MM, Pradhan B, Teherse N, Meitei LT, Singh NN. Yolk Sac Tumor in Pregnancy: A Case Report. *IOSR Journal of Dental and Medical Sciences.* 2015; 14: 35-37.