

Case Report

The Management of Ovarian Cancer in Bangladesh: A Report of a Long-Term Survivor

Shahana Pervin¹, Farzana Islam¹, Tracilyn Hall^{2,3} and Annkathryn Goodman^{2,3*}

¹National Institute of Cancer Research Hospital, Department of Gynecology, Dhaka, Bangladesh

²Division of Gynecologic Oncology, Vincent Obstetrics and Gynecology, Massachusetts General Hospital, Boston, Massachusetts

³Department of Obstetrics and Gynecology Harvard School of Medicine, Boston, Massachusetts

*Corresponding author: Goodman A, Department of Obstetrics and Gynecology, Harvard Medical School, Massachusetts General Hospital, 55 Fruit Street, Boston, Massachusetts, Tel: (617) 724-5242; Fax: (617) 724-6898; Email: agoodman@mgh.harvard.org

Received: June 24, 2015; Accepted: August 17, 2015;

Published: August 18, 2015

Introduction

Ovarian cancer is a killer of women in high-income countries. It has the highest death to diagnosis ratio of all breast and gynecologic cancers combined. For instance in 2015 in the United States, a 66% death rate is predicted with an estimated 21,290 new cases of ovarian cancer and an anticipated 14,080 deaths [1]. Conversely, in low-income countries, breast and cervical cancer are the leading causes of cancer-related deaths of women [2]. This is due both to lack of screening for these preventable and curable cancers and a lack of access to cancer treatment centers. The 2010 statistics for Bangladesh on age standardized death rates per 100,000 show that cervical cancer and ovarian cancer rank 24th and 45th, respectively [3]. As the standard of living increases and resources for a medical infrastructure improve in Bangladesh, there will be an increased need to address less common but highly lethal cancers such as ovarian cancer. Glob can predicts a change in the reported incidence of ovarian cancer from 2912 in year 2012 to 3132 in 2015 [4]. This report describes a patient who was a long-term survivor of stage 4 ovarian cancer. The resources for a medical infrastructure to care for women with ovarian cancer are discussed and the literature on long-term survivors and the current experience with ovarian cancer in Bangladesh is reviewed.

Case Report

The patient was a 40-year-old Gravida 2 Para 2 woman who presented with abdominal pain and distension in October 2003. A CT scan showed a pelvic mass and liver metastases. Her CA 125 was 5000. She was diagnosed as a stage four ovarian cancer. She underwent an exploratory laparotomy, total abdominal hysterectomy with bilateral salpingo-oophorectomy. Histopathology showed a grade 3 serous cystadenocarcinoma (Figure 1). She then received adjuvant intravenous chemotherapy for 12 cycles: her first 6 cycles included paclitaxel 175 mg/m² and cisplatin at 75 mg/m² every 21 days followed by an additional six cycles with carboplatin at an AUC

Abstract

Recurrent high-grade epithelial ovarian cancer is usually associated with a short-term survival. There are few guidelines to surgically and medically treat long-term survivors with ovarian cancer. We report the case of a woman who presented at the age 40 years with an advanced epithelial cancer. With the interventions of multiple surgeries and multiple lines of chemotherapy, she survived for twelve years. We also comment on the feasibility of complex oncology care in a low-middle income country such as Bangladesh. Complex care is only available for patients who can afford the out of pocket expenses. The development of universal healthcare insurance must be part of the strategy for the development cancer care services in Bangladesh.

Keywords: Epithelial ovarian cancer; Long-term survivor; Secondary cytoreduction; Tertiary cytoreduction, hepatic resection; Bangladesh

of 6 and paclitaxel every 21 days. After a one-year remission, her cancer recurred in 2005 and she was given 2 cycles of docetaxel plus carboplatin with an AUC of 5. Her CA 125 cancer marker returned to normal. After 10 months, in 2006, her CA 125 level increased and she received 4 cycles of paclitaxel, gemcitabine and cisplatin. Her markers again came down to normal. In 2007 again after another recurrence, doxorubicin, etoposide, ifosfamide, and mesna were given for six cycles. She had a partial response and underwent a splenectomy for isolated and persistent disease in her spleen. She received oral letrozole along with an antioxidant called Oncoxin® for four months, but developed a rising CA 125 marker. In 2009, a laparoscopic cholecystectomy was performed for isolated tumor involvement of her gallbladder. Following this surgery, she continued on oral Oncoxin® and letrozole. In March 2010, she underwent an en bloc abdominal wall resection with partial resection of the right lobe of her liver for recurrent isolated disease. The histopathology report showed metastatic adenocarcinoma consistent with her ovarian primary. In May 2010, she received 4 fractions of 20 Gray of external beam radiation for chest wall metastasis. In 2011, a CT scan of the abdomen

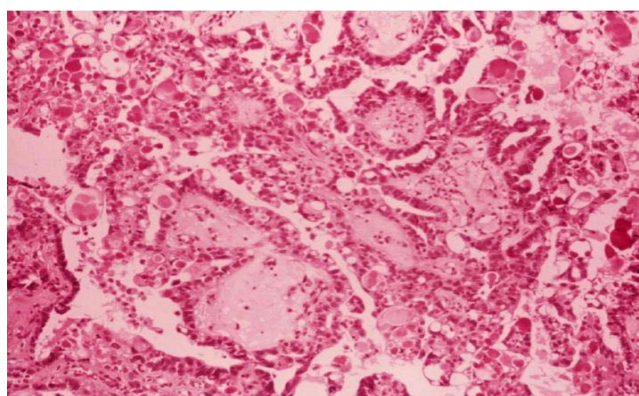


Figure 1: High-grade serous carcinoma of the ovary at diagnosis in 2003.

Table 1: Summary of the Clinical Course.

Year	Surgery	Chemotherapy or radiation	Number of cycles
2003	Hysterectomy, bilateral salpingo-oophorectomy	Cisplatin and paclitaxel	6
2004		Carboplatin and paclitaxel	6
2005		Carboplatin and Docetaxel	2
2006		Cisplatin, paclitaxel, gemcitabine	4
2007	splenectomy	Doxorubicin, etoposide, ifosfamide, and mesna	6
2008		Letrozole and oncoxin	12 months
2009	cholecystectomy		
2010	Abdominal wall resection and liver resection	External beam radiation to chest wall	200 gray for 4 fractions
2011	Enbloc colectomy and para-aortic node resection	Carboplatin, paclitaxel, topotecan and etoposide	3
2011-2012		erlotinib	18 months
2013		Pegylated liposomal doxorubicin	5
2014-2015		Letrozol and herbal medicine	24 months
June 2015			Died from disease

showed new left para-aortic lymphadenopathy with involvement of her colon and she underwent a partial transverse colectomy with para-aortic lymphadenectomy. She then received three cycles of paclitaxel, carboplatin, topotecan, and etoposide. This was followed by 18 months of erlotinib. By 2013, her CA-125 started rising and a Pet CT showed FDG activity consistent with widespread intra-abdominal recurrence. She received five cycles of pegylated liposomal doxorubicin without response. Since 2014, she was maintained on letrozole and herbal medicine. She died from widespread intra-abdominal disease in June of 2015. (Table 1) summarizes her clinical course.

Discussion

We report the case of a woman with advanced and high-grade epithelial ovarian cancer who survived for twelve years despite multiple recurrences. She received complex and highly sophisticated oncologic care in Bangladesh. While the mean five-year overall survival from advanced epithelial ovarian cancer is 20 percent, there is a subset of women who are long-term survivors [5]. In a review of 251 women with advanced stage ovarian cancer, univariate analysis revealed that FIGO stage III and IV, elevated serum CA125, and suboptimal debulking were significant factors in reducing duration of Progression Free Survival (PFS) and overall survival (OS). In multivariate analysis, advanced FIGO stage and suboptimal debulking significantly reduced PFS. However, OS was significantly reduced by advanced FIGO stage only [6]. Specifically, the five-year PFS and OS rates for FIGO stages I and II was 44.6% and 52.7% compared to 17.7 % and 30.8% for FIGO stages III and IV respectively. There are guidelines for the management of ovarian cancer recurrence within the first two years of diagnosis. The average time to recurrence is 18 to 24 months [7]. Fifty percent of recurrences occur more than 12 months out with 30% of recurrences occurring in the abdomen and 25% in the pelvis. Liver, spleen, retroperitoneal nodes all account for 6-7% of the sites of recurrent disease. Survival after recurrence is dependent on several important factors: time to recurrence, (<vs.> 6months), number of recurrence sites (single versus multiple), and the type of treatment given for recurrence [7]. A pooled analysis of three large studies reported a median overall survival of 36 to 39

months for patients with advanced stage ovarian cancer who had undergone cytoreductive surgery followed by platinum and paclitaxel based chemotherapy [8]. In a study from 2013 in a highly controlled setting of aggressive surgery followed by conventional carboplatin and paclitaxel, the median overall survival was reported as 62 months [9]. There are no clear guidelines for appropriate surgical interventions for long-term survivors. Retrospective reviews of secondary surgical cytoreduction suggest that the ideal patient for secondary surgical intervention has platinum sensitive disease and oligometastatic disease [10]. There is extremely limited guidance for tertiary cytoreductive surgery. Long-term survival is uncommon. One report describes three patients who were disease free 7, 12, and 13 years respectively after aggressive management of their recurrent disease using surgical resection, chemo radiation, and chemotherapy alone [11]. Complete surgical excision of solitary metastases improves survival [12]. Improved survival has also been documented for surgical resection of oligometastatic recurrence. One case report documented repeat surgical resection of bone metastases in a patient with chemotherapy resistant disease which allowed a ten-year survival [13]. A single institution retrospective review showed the feasibility of liver resection with improvement in survival with the resection of all gross disease [14]. There are also no clear recommendations for appropriate chemotherapy after two to three lines of therapy. Thirteen randomized trials evaluated various chemotherapy regimens in recurrent ovarian cancer. Drugs included pegylated doxorubicin, paclitaxel, epirubicin, carboplatin, cyclophosphamide, topotecan, and treosulfan. The only doublets, carboplatin with paclitaxel and carboplatin with gemcitabine, showed significantly improved responses over single agents [15]. The incidence of ovarian cancer varies by geographic regions and ethnic groups [16]. The incidence is rising in low and middle-income countries as women are surviving pregnancy-related and infectious disease-related mortality [17]. This case demonstrates that long-term survival is achievable in Bangladesh. Over a twelve-year period, our patient underwent five major surgeries, 10 lines of chemotherapy, and one short course of radiation therapy with no major complications (Table 1). Her clinical history demonstrated that safe and complex cancer care can be given in Bangladesh. If this patient had not received aggressive care she would have died quickly

but instead survived 12 years with a good quality of life. According to WHO, an estimated 8.1 million people died of cancers in 2012 [18]. The incidence of cancer is rising in Asia [7]. In Taiwan over a 30-year period, the age-specific incidence of ovarian cancer increased and the age of diagnosis decreased from 60 to 50 years [19]. Cancer is one of the leading causes of morbidity and mortality in Bangladesh. The estimated cancer load is 1.2 million with an incidence of 200,000, a prevalence of 800,000, and mortality at 150,000. Cancer incidence is expected to double in the next 20 years [20]. In a survey of 117 cancer patients in Dhaka, 8.1 % had ovarian cancer [21]. Of note, the peak of age of cancers in this study was in the 50-59 cohort. To date, publications on ovarian cancer in Bangladesh have been limited to case reports [22-24]. This paucity of national data may reflect the current lack of a nationwide tumor registry [20]. One of the challenges for cancer patients in Bangladesh is the tremendous cost of care. Women with ovarian cancer consume a large proportion of healthcare resources [25]. The mean cost of managing ovarian cancer in the United Kingdom in 2006 was 34-43 thousand pounds [26]. The last 60 days of life of a woman with ovarian cancer in the United States costs 60 thousand dollars [27]. Treatment expenses include laboratory tests, radiology, surgery, hospitalization and chemotherapy [28]. End of life care including admissions for symptom management adds to expenses. Bangladesh has developed a pluralistic health care system which includes government services, multiple NGOs, and a robust private sector [29]. However, the majority of Bangladesh citizens cannot afford healthcare and do not have access to the complex care our patient received [30]. Development of universal health care insurance must be part of the strategy in Bangladesh for complex care such as for ovarian cancer [17, 20].

References

- Siegel RL, Miller KD, Jemal A. Cancer statistics, CA Cancer J Clin. 2015; 65: 5-29.
- Ferlay J, Shin HR, Bray F, Forman D, Mathers C, Parkin DM. Estimates of worldwide burden of cancer in 2008: GLOBOCAN 2008. *Int J Cancer*. 2010; 127: 2893-2917.
- World Health Rankings, Bangladesh accessed June 20, 2015.
- Globocan 2015 Ovarian cancer in Bangladesh accessed June 20, 2015.
- Vergote I, De Wever I, Tjalma W, Van Gramberen M, Decloedt J, van Dam P. Neoadjuvant chemotherapy or primary debulking surgery in advanced ovarian carcinoma: a retrospective analysis of 285 patients. *Gynecol Oncol*. 1998; 71: 431-436.
- Fu Y, Wang X, Pan Z, Xie X. Clinical outcomes and prognostic factors of patients with epithelial ovarian cancer subjected to first-line treatment: a retrospective study of 251 cases. *Front Med*. 2014; 8: 91-95.
- Ushijima, K. Treatment for Recurrent Ovarian Cancer. *At First Relapse Journal of Oncology*. 2010; 20: 2015.
- Högberg T, Glimelius B, Nygren P; SBU-group Swedish Council of Technology Assessment in Health Care. A systematic overview of chemotherapy effects in ovarian cancer. *Acta Oncol*. 2001; 40: 340-360.
- Katsumata N, Yasuda M, Isonishi S, Takahashi F, Michimae H, Kimura E, et al. Long Term results of dose-dense paclitaxel and carboplatin versus conventional paclitaxel and carboplatin for treatment of advanced epithelial ovarian, fallopian tube, or primary peritoneal cancer (JGO 3016): a randomized, controlled, open-label trial. *Lancet Oncol*. 2013; 14: 1020-1026.
- Galaal K, Naik R, Bristow RE, Patel A, Bryant A, Dickinson HO. Cytoreductive surgery plus chemotherapy versus chemotherapy alone for recurrent epithelial ovarian cancer. *Cochrane Database Syst Rev*. 2010; CD007822.
- Chen CY, Chang HP, Ng KK, Wang CC, Lai CH, Chao A. Long-term disease-free survival in three ovarian cancer patients with a single relapse. *Eur J Gynaecol Oncol*. 2012; 33: 321-323.
- Tay EH, Grant PT, Gebiski V, Hacker NF. Secondary cytoreductive surgery for recurrent epithelial ovarian cancer. *Obstet Gynecol*. 2002; 99: 1008-1013.
- Akashi D, Todo Y, Okamoto K, Minobe S, Kato H. Achievement of 10-year survival: a case of pubic bone recurrence as the primary failure site of chemo-refractory ovarian clear cell carcinoma. *J Obstet Gynaecol Res*. 2013; 39: 1359-1362.
- Kolev V, Pereira EB, Schwartz M, Sarpel U, Roayaie S, Labow D, et al. The role of liver resection at the time of secondary cytoreduction in patients with recurrent ovarian cancer. *Int J Gynecol Cancer*. 2014; 24: 70-74.
- Fung-Kee-Fung M, Oliver T, Eliit L, Oza A, Hirte HW, Bryson P. Optimal chemotherapy treatment for women with recurrent ovarian cancer. *Current Oncology*. 2007; 14: 195-207.
- Bhoo-Pathy N, Hartman M, Yip CH, Saxena N, Taib NA, Lim SE, et al. Ethnic differences in survival after breast cancer in South East Asia. *PLoS One*. 2012; 7: e30995.
- Du XL, Sun CC, Milam MR, Bodurka DC, Fang S. Ethnic differences in socioeconomic status, diagnosis, treatment, and survival among older women with epithelial ovarian cancer. *Int J Gynecol Cancer*. 2008; 18: 660-669.
- World Health Organization. Cancer 2015 accessed June 21, 2015.
- Chiang YC, Chen CA, Chiang CJ, Hsu TH, Lin MC, You SL, et al. Trends in incidence and survival outcome of epithelial ovarian cancer: 30-year national population-based registry in Taiwan. *J Gynecol Oncol*. 2013; 24: 342-351.
- National Cancer control strategy and plan of action 2009-2015. Accessed June 21, 2015.
- Hasan AHMN, Uddin MdM, Rafiquzzaman Md, Chowdhury SS, Wahed TB. Distribution of types of cancer and patterns of cancer treatment among the patients at various hospitals in Dhaka division, Bangladesh. *Intl Res J Pharm*. 2012; 3: 219-222.
- Moniruzzaman M, Faruquzzaman, Mohiuddin T. Consequences of abdominal adenocarcinoma in post-menopausal woman in relation to surgical and non-surgical management. *Bratisl Lek Listy*. 2011; 112: 472-474.
- Akhter N, Habib A. Successful pregnancy outcome with coexisting primary epithelial ovarian carcinoma. *Mymensingh Med J*. 2013; 22: 599-602.
- Rashid MM, Ahmed M, Hossain D, Sarwar MG, Zaman Y, Nigar A, et al. Pulmonary metastases of a papillary adeno-carcinoma of ovary in a pregnant lady. *Mymensingh Med J*. 2012; 21: 175-178.
- Kim K, Hernlund E, Hernadi Z, Révész J, Pete I, Szánthó A, et al. Treatment patterns, health care utilization, and costs of ovarian cancer in Central and Eastern Europe using a Delphi panel based on a retrospective chart review. *Int J Gynecol Cancer*. 2013; 23: 823-832.
- Greving JP, Vernooij F, Heintz AP, van der Graaf Y, Buskens E. Is centralization of ovarian cancer care warranted? A cost-effectiveness analysis. *Gynecol Oncol*. 2009; 113: 68-74.
- Lewin SN, Buttin BM, Powell MA, Gibb RK, Rader JS, Mutch DG, et al. Resource utilization for ovarian cancer patients at the end of life: how much is too much? *Gynecol Oncol*. 2005; 99: 261-266.
- Chornokur G, Amankwah EK, Schildkraut JM, Phelan CM. Global ovarian cancer health disparities. *Gynecol Oncol*. 2013; 129: 258-264.
- Chowdhury AM, Bhuiya A, Chowdhury ME, Rasheed S, Hussain Z, Chen LC. Bangladesh: Innovation for universal health coverage I: the Bangladesh paradox: exceptional health achievement despite economic poverty. *Lancet*. 2013; 382:1734-1745.
- Hussain SM. Comprehensive update on cancer scenario of Bangladesh. *South Asian J Cancer*. 2013; 2: 279-284.