

## Special Article - Brachial Plexus Injury

# Technical Note: Spinal-Accessory to Suprascapular Nerve Transfer by Posterior Approach

Martínez F\*

Department of Neurosurgery, Hospital de Clínicas de Montevideo, Uruguay

\***Corresponding author:** Fernando Martínez, Servicio de Neurocirugía, Hospital de Clínicas, Avda Italia s/n Esquina Las Heras, Instituto de Neurología, Piso 2, CP 11.300, Montevideo, Uruguay

Received: April 15, 2017; Accepted: June 20, 2017;

Published: June 29, 2017

**Abstract**

In this technical note, the author describes the technique used in 20 spinal accessory nerve to suprascapular nerve transfers by posterior approach (XI to SSN transfer), based on previous cadaveric dissections.

Such technique might be used as an alternative to the anterior approach in patients in whom the supraclavicular plexus is not going to be exposed or in those who are referenced to surgery in a late time.

Few studies compare the functional outcome of the anterior and posterior approach, but evidence suggests there are better results in abduction and external rotation of the shoulder when the posterior approach is used.

In the technique presented, the XI and SSN are located 11cm and 7cm medial to the acromioclavicular joint, respectively. A skin incision is placed one centimeter above the scapular spine, covering the points where spinal-accessory and suprascapular nerves are located. Sharp dissection of the trapezius muscle is performed and the scapular notch is located by palpation. The transverse scapular ligament is cut and the SSN nerve freed. A non-tension suture without interposing graft can be achieved in more than 90% of cases.

The author concludes the posterior approach for XI to SSN transfer is a safe and effective technique, although it requires specific training and deep anatomical knowledge of the region to be operated.

**Keywords:** Brachial plexus injury; Supra scapular nerve; Spinal accessory nerve

**Abbreviations**

SSN: Supra Scapular Nerve; XI: Spinal accessory nerve

**Introduction**

In most of the brachial plexus injuries, it is necessary to recover the stability of the shoulder as well as its abduction and external rotation.

Although there are many techniques to achieve this goal, one of the most used techniques is the nerve transfer of fascicles of the accessory nerve (XI) to the Supra Scapular Nerve (SSN), which can be performed by an anterior or a posterior approach.

The anterior approach is simple and feasible for any surgeon used to access the brachial plexus by a supraclavicular route. Nevertheless, recent clinical series suggest better results in shoulder abduction and external rotation can be obtained when the XI-SSN neurotization is performed using a posterior approach [1-3].

The author purpose is to detail the technique he uses to perform the posterior approach XI-SSN transfer.

**Materials and Methods**

This report is a technical note.

Following previous works based on cadaveric anatomic dissection [4], the author correlated in 20 patients the anatomical landmarks

related to the technique being presented.

Informed consent was obtained in every case.

Authorization of the Ethics Committee was not obtained since the posterior XI-SSN is not a technique developed by the author.

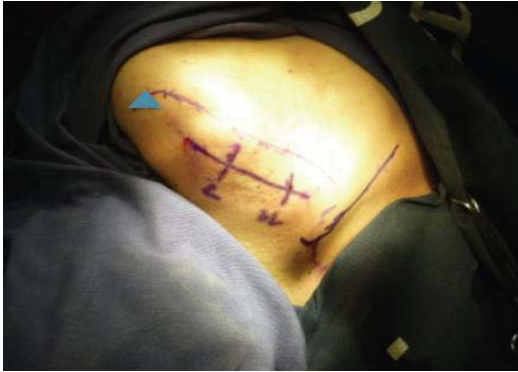**Description of the technique**

**Indications:** 1) Patients who do not have abduction and external rotation of the shoulder secondary to a brachial plexus lesion (brachial plexus with the following pattern: C5-C6, C5-C7, C5-T1), 2) Cases of late reference for surgery and 3) Patients in which the SSN is not found by the anterior approach.

**Position:** The ventral or lateral decubitus can be used. The author prefers ventral decubitus, especially in patients with a C5-C6 lesion since axillaries to triceps transfer can be done in the same position [1].

Anatomical landmarks (which should be identified by palpation): the Acromio-Clavicular Joint (ACJ), the spine of the scapula, the upper and inner angle of the scapula, the inner border of the scapula. In an anatomical study, we found that XI and SSN are located 11cm and 7cm medially to ACJ [4].

**Incision:** It is placed one centimeter above the spine of the scapula and should cover at least two points located 7cm and 11cm from the ACJ (topography of the suprascapular and accessory nerves,



**Figure 1:** Anatomical landmarks to spinal accessory to suprascapular nerve transfer by posterior approach. The supra scapular and spinal accessory nerves are located 7 and 11 centimeters medial to the acromioclavicular joint (triangle), respectively.

respectively) (Figure 1).

**Dissection:** After sectioning the skin, the trapezius muscle is located and its fibers are opened parallel to its direction, without cutting them apart. A self-static spreader is placed to keep the working channel open. Initially, the accessory nerve is found about 11 cm medially from the ACJ and its presence is confirmed with the use of a neurostimulator. A silicon band will protect and mark the position of the nerve.

The dissection continues by following the superior aspect of the supraspinatus muscle until the superior border of the scapula is located, and the dissection is directed to a point located 7 cm medially to the acromioclavicular joint. In this topography, on the upper edge of the scapula, palpation is sought for a somewhat softer area, corresponding to the transverse scapular ligament. It closes the scapular notch, where the suprascapular nerve is located. It is also possible to locate the notch medial to the base of the coracoid process. The ligament is carefully dissected and the suprascapular vein is identified and coagulated, as this facilitates the management of the nerve. An instrument (Crille, for example) is placed under the ligament and it is cut with a scalpel, leaving the suprascapular nerve and the accompanying artery free.

The dissection is continued towards the proximal SSN, with which one can gain 1-1.5 cm of nerve length.

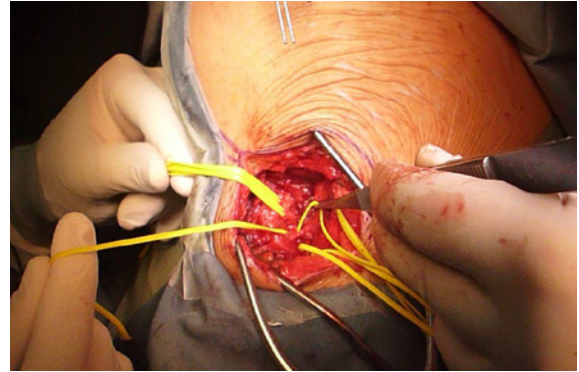
Since the transverse ligament is sometimes a point of injury of the SSN (double crush), the author makes sure there is a viable SSN before cutting the accessory nerve.

Distal dissection of the XI is performed until it gives of its first branches, to avoid the problems nerve suture would represent if two or three small branches are used instead of the nerve trunk. However, in some cases where the branching point is too proximal, it is advisable to continue dissection more distally and eventually suture the larger branch, attaching the smaller branch with biological glue.

A tension-free suture is achieved without an interposed a graft in more than 90% of cases.

## Discussion

Posterior approach to XI (spinal accessory nerve) to SSN (Supra



**Figure 2:** Surgical dissection of the nerves. The supra scapular (two headed arrow) and spinal accessory (arrow) nerves are marked with vessel loops.

Scapular Nerve) was first published by Bahm et al. in 2005 [5]. In 2006 Guan et al. [4] published a surgical series comparing the anterior vs. the posterior approach, showing better clinical results for the posterior approach (Figure 2).

The posterior approach for the nerve transfer of XI to SSN has both disadvantages and advantages if we compare it with the anterior approach.

Among the first ones we must emphasize: less familiar anatomy for the surgeon, longer surgical times (at least initially) and the necessity of a second surgical approach (for example, if an Oberlin technique will be performed).

Among the advantages are: exploration of a point of possible double lesion, cooptation of the nerve closer to the target muscles, less visible scar, shorter re-innervations times and better results for both external rotation and abduction of the shoulder [2-4,6].

This has led some authors to recommend the posterior approach as the route of choice in cases of delayed surgery [2].

In the indexed literature, there are few descriptions of the technique and the anatomical landmarks used.

For example, Colbert and Mackinnon [7] described that to identify the location of the distal XI, the dorsal midline and the acromion are marked. A point 40% of the distance from the dorsal midline to the acromion along the superior border of the scapula is marked and identifies the approximate location of the distal accessory nerve. To identify the location of the suprascapular nerve, the superior angle of the scapula and the acromion are marked. A point marked midway between these two points identifies the area of the suprascapular notch where the SSN is located. The skin incision is planned with a straight line between the marks identifying the two nerves.

In a cadaveric study, the author's group found the scapular notch to be located between 5.5 and 7 centimeters medial to the acromioclavicular joint, while the spinal nerve was 11 cm medial to the ACJ [4].

Although these landmarks may vary with the patient's position and the biotype, they are a reliable guide that the author's has used in 15 patients. The author believes the landmarks used by his group are easier to use when are compared with Colbert and Mackinnon's [7].

Although in the first cases it takes longer time than the anterior route, with the appropriate training, times are comparable.

This technique is especially indicated in patients who will also receive a triceps to axillar nerve transfer. If the brachial plexus is to be explored by a supraclavicular route, its use is debatable since it would require a second surgical approach which can be avoided by making the transfer by the anterior approach.

The author thinks the best indication for the posterior approach is in patients with a C5-C6 lesion in which a triceps to axillar nerve transfer will be performed, C5-C7 lesions in which no spinal nerve roots are available for neurotization, in total plexus injury or in any injury pattern that is of late reference to the surgeon (more than 6-8 months). It is obviously indicated in cases in which a double crush injury is highly suspected or patients in which the SSN cannot be found by the anterior approach.

In 2 cases the author did not find the SSN by the anterior nor the posterior approach.

## References

1. Guan SB, Hou CL, Chen DS, Gu YD. Restoration of shoulder abduction by transfer of the spinal accessory nerve to suprascapular nerve through dorsal approach: a clinical study. *Chinese Med J.* 2006; 119: 707-712.
2. Bhandari PS, Deb P. Dorsal approach in transfer of the distal spinal accessory nerve into the suprascapular nerve: histomorphometric analysis and clinical results in 14 cases of upper brachial plexus injuries. *J Hand Surg Am.* 2011; 36:1182-1190.
3. Souza FH, Bernardino SN, Filho HC, Gobbato PL, Martins RS, Martins HA, et al. Comparison between the anterior and posterior approach for transfer of the spinal accessory nerve to the suprascapular nerve in late traumatic brachial plexus injuries. *Acta Neurochir (Wien).* 2014; 156: 2345-2349.
4. Martínez F, Jaume A, Sienna C, Ruso A. Surgical anatomy of spinal for suprascapular nerve transfer by posterior approach. *Neurocirugía (FLANC).* 2017; 26: 5.
5. Bahm J, Noaman H, Becker M. The dorsal approach to the suprascapular nerve in neuromuscular reanimation for obstetric brachial plexus lesions. *Plast Reconstr Surg.* 2005; 115: 240-244.
6. Martinez F, Pinazzo S, Jaume A, Sienna C, Ruso C. Suprascapular nerve neurotization using fascicles of the spinal accessory nerve. Anterior vs. posterior approach. GERSAM Meeting. Wunzburg, Germany. 2015; 13-14.
7. Colbert SH, Mackinnon S. Posterior approach for double nerve Transfer for restoration of shoulder function in upper brachial plexus palsy *Hand.* 2006; 1: 71-77.