

Case Report

Successful Obliteration of an Arteriovenous Malformation an A Child After Low-Dose Hypofractionated Stereotactic Radiotherapy

Ślawomir Blamek*, Kornelia Ficek and Dawid Larysz

Department of Radiotherapy, Maria Skłodowska-Curie Memorial Cancer Center and Institute of Oncology, Poland

***Corresponding author:** Ślawomir Blamek, Department of Radiotherapy, Maria Skłodowska-Curie Memorial Cancer Center and Institute of Oncology, Gliwice Branch ul, Wybrzeże AK 1544-100 Gliwice, Poland

Received: March 05, 2014; **Accepted:** May 25, 2014;
Published: May 26, 2014

Abstract

Stereotactic radio surgery is a recognized method of treatment for cerebral Arterio Venous Malformations (AVMs). The details of the dose-response relationship are however still poorly described and radiobiological properties of AVMs, especially in children are largely unknown. We describe a case of a 9-year-old girl successfully treated with low-dose hypofractionated stereotactic radiotherapy. The girl was admitted to regional department of neurosurgery due to a massive intracranial hemorrhage caused by a ruptured AVM. She was treated surgically and postoperative imaging did not reveal remnants of the AVM. One year later magnetic resonance angiography showed an AVM at the periphery of the postoperative cavity. After unsuccessful attempt of embolization she was irradiated with linear accelerator-based stereotactic technique with 16 Gy given in 2 fractions. Fifteen months later complete obliteration was diagnosed on follow-up imaging. The extraordinary response to low-dose treatment may suggest that there exist a subpopulation of pediatric AVMs of above-average susceptibility to radiation. A multicenter study on a large group of pediatric patients could identify the hypothetical group that could benefit from reducing the dose of ionizing radiation by lowering the probability of radiation-induced complications without jeopardizing the probability of obliteration.

Keywords: Arterio venous malformation; Children; Brain; Hypofractionated stereotactic radiotherapy; Radiosurgery; Radiobiology

Background

There is still little known about radiobiology of Arteriovenous Malformations (AVMs). The estimations published to date range in a wide spectrum, from negative, to positive values with some estimations defining this value at the level of 11-14 Gy [1-3]. Some authors speculate that the alpha/beta value does not play an important role in stereotactic radiosurgery for AVMs and suggest that it has rather low values, characteristic for late-responding tissues [4,5]. There are also uncertainties concerning the value of alpha/beta ratio in AVMs of different size. Some authors claim that small AVMs have alpha/beta value higher than the large ones and propose a value of 6.4 Gy [2]. This phenomenon could explain better treatment results in case of small AVMs as higher alpha/beta ratio suggest the presence of higher number of cells sensitive to radiation. The reason for the observed difference in treatment outcome between small and large AVMs, and thus, different alpha/beta values can be also explained by differences in cellular density and volume of "acellular" space within the nidus of an AVM [6]. Pellettieri and Blomquist hypothesize that large AVMs usually have both less compact structure and wider vessels containing blood cells which are not involved in radiation-induced structural changes of the nidus. For that reason, the effect of irradiation is less pronounced in large AVMs as there is less number of cells responding to radiation per unit of volume [6]. Similar suggestion concerning distinct radiobiological properties based on comparable results of hypofractionated and single-fraction treatment has been made in case of pediatric AVMs. This observation however was not supported by

calculation of the exact alpha/beta value due to limited number of cases presented [7]. In the present study the authors describe a case of cerebral Arterio venous malformation in a child successfully treated with low-dose hypofractionated stereotactic radiotherapy.

Case Presentation

A nine-year old girl was admitted to the neurosurgery department outside our Institution after a sudden loss of consciousness and left-side hemi paresis. Imaging studies showed a large 65x29 mm right-hemisphere hematoma with accompanying edema, compression of the right lateral ventricle and pronounced mass effect. She was qualified to surgical treatment on the same day and the hematoma with an arteriovenous malformation being the source of bleeding was removed. Due to large edema and a decompressive craniectomy was made. The missing bone was replaced with a custom made Codubix plate 7 months later. Postoperative imaging performed five days after the first surgery did not reveal remnants of the AVM. MR imaging performed one year after the surgery showed scant pathological vessels on the edge of the surgical cavity suggestive of still existing portion of the AVM. The patients were qualified to digital subtraction angiography which confirmed the presence of an AVM of approximate diameter of 20 mm in the right occipital lobe. The lesion was fed with vessels originating from right Posterior Cerebral Artery (PCA). Draining veins were exclusively superficial and drained to the superior sagittal sinus. An unsuccessful attempt of endovascular embolization was made and then the girl was referred

to our Center for radiosurgery. CT angiography made during the treatment planning confirmed the presence of an AVM measuring 25 x 7 mm which was also visualized on MR scans. Moreover, diagnostic studies revealed the presence of hemoglobin metabolites focally lining the postoperative cavity. The patient was qualified to hypofractionated stereotactic radiotherapy and received 16 Gy in two 8 Gy fractions. Radiosurgery was performed with a linear accelerator equipped with a micro-multileaf collimator used for field shaping. The head was immobilized in a thermoplastic mask and the two fractions were delivered with a planned one-week gap between them. Imaging performed 3 months after radiotherapy did not reveal any changes as did imaging after 9 months. Fifteen months after the treatment in January 2013 on CT angiography no contrast enhancement in the region of residual AVM was seen and the diagnosis of total obliteration was made (Figure 1). The tolerance of the treatment was excellent and no side effects were observed both during and after the irradiation.

Discussion

The minimum dose sufficient for triggering the obliteration process is estimated on the level of 15-18 Gy [8-10]. Lower doses usually are insufficient to achieve cure. In case of hypofractionated treatment the fraction and total dose also play a role and in the adult population the effect of fractionation schedule on treatment results was demonstrated [11-14]. On the other hand, there is evidence that pediatric AVMs respond in a different way to radiation than those in adults. Differences in response to radiation in case of pediatric AVMs were already noted over twenty years ago and confirmed in later series [12,15-17]. This phenomenon however is not fully elucidated. One of the reasons of the increased radiosensitivity can be angiogenesis in arteriovenous malformations. There are observations documenting formation these lesions de novo [18]. In spite of commonly performed transcranial ultra sonography and increasingly used magnetic resonance imaging in neonates, diagnoses of neonatal AVMs are rare and the prevalence of AVMs increases with age [19]. There is also evidence that AVMs can enlarge, especially in young patients, as well, as spontaneously disappear [20,21]. Growth and regression of cerebral AVMs in children are especially observed in patients with hereditary hemorrhagic telangiectasia [22]. There are also recurrences of totally resected AVMs reported, especially in children [23]. The hypothesis of angiogenic potential of these lesions is supported by histological examination of excised specimens showing expression of VEGF and its receptor [20]. In the reported case no evidence of AVM was reported in the postoperative imaging which was however not confirmed with

DSA, and thus, recurrence after resection cannot be UN doubtfully proven. Pronounced angiogenesis and dynamic changes inside the lesion in young patients can be however the explanation of different response to radiation as compared to AVMs in adults. AVMs are usually considered late responding lesions of low alpha/beta ratio. Distinct radiobiological properties of pediatric AVMs, i.e. higher alpha/beta could explain satisfactory treatment results in case of hypofractionated irradiation [7]. This effect could be associated with greater radiosensitivity of proliferating AVM cells which is observed for example in malignant tumors or epithelium. In this case, smaller dose of radiation could generate greater effect in terms of hampering the growth of the lesion and triggering proliferation of myofibroblasts and production of collagen fibers which finally leads to occlusion of the nidus. This hypothesis could explain the results of treatment in the described case in which the total dose is in fact below the commonly accepted curative threshold. Growing evidence of distinct response to radiation in children is worth of multi institutional studies as the number of treated cases in single centers is usually low as compared to adults and the prescribed doses are within the range imposed by local protocols. Analysis of a large group of patients irradiated with different doses could enable a reliable estimation of the dose-response relationship in children and calculation of the alpha/beta ratio. This, in consequence could lead to modification of dose prescription rules and hopefully lowering the dose delivered to maturing brain without jeopardizing the probability of obliteration. The presented case is not the only one successfully treated with relative low dose of fractionated radiation. Recently, Lee et al. described a case of a large bilateral thalamic AVM in a twelve-year-old boy obliterated with 30 Gy delivered in 5 fractions given every other day [24]. The dose of 6 Gy per fraction proved sufficient for total obliteration of Spetzler-Martin grade IV lesion. The authors however advise special caution in interpretation of their results as they cannot be easily transferable to other patients. This is also the case here. Successful obliteration of an AVM with radiation dose lower than commonly proposed as minimum necessary for treatment effect indicates that there may be a population of patients with Arterio venous malformations remarkably sensitive to ionizing radiation, especially in the pediatric population. It is also important to note that different response to irradiation in children than in adults is not confirmed by all authors. Pan et al. reported worse outcomes in children harboring AVMs of 3-10 cm³ than in adults and similar results in case of both smaller and larger lesions [25]. Therefore, the same treatment guidelines for all age groups are also advised [26]. The primary concern of a physician treating a patient with a cerebral AVM should be protection from intracranial hemorrhage. If successful treatment with low doses of radiation at least in selected cases is possible, this hypothesis should be explored in order to reduce the probability of radiation-induced adverse effects of the treatment, which is of special importance in children.

Conclusion

Presentation of a single case cannot obviously lead to verification of commonly accepted standards. Nevertheless, the reported case of obliteration after relative low dose of radiation in a child can be suggestive of higher radiosensitivity of at least some AVMs in children. Further studies are required to assess radiobiological properties of pediatric AVMs. Pooling data from numerous centers

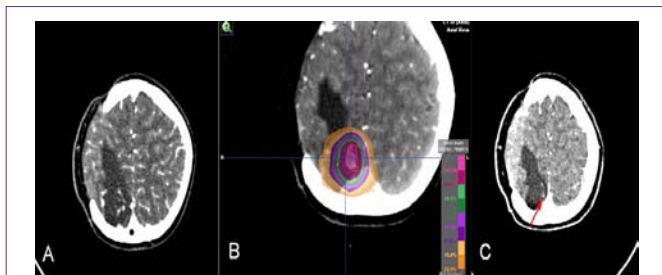


Figure 1: Appearance the arteriovenous malformation before radiosurgery (A) During treatment planning (B) The isodose distribution is shown in color wash, and after radiosurgery (C) On the CT angiography only a draining vessel (red arrow) is visible.

involved in stereotactic radiosurgery for cerebral AVMs in children could allow for selection of patients responding to lower doses of radiation. The next step would be optimization of treatment protocols to obtain optimal results with minimum risk of radiation-induced complications.

References

- Flickinger JC, Kondziolka D, Maitz AH, Lunsford LD. An analysis of the dose-response for arteriovenous malformation radiosurgery and other factors affecting obliteration. *Radiother Oncol.* 2002; 63: 347-354.
- Kocher M, Wilms M, Makoski HB, Hassler W, Maarouf M, et al. Alpha/beta ratio for arteriovenous malformations estimated from obliteration rates after fractionated and single-dose irradiation. *Radiother Oncol.* 2004; 71: 109-114.
- Wigg DR. A radiobiological basis for the treatment of Arterio venous malformations. *Acta Oncol.* 1999; 38: 3-29.
- Karlsson B, Lax I, Yamamoto M, Söderman M, Jokura H, Chrles Rosen, et al. Calculation of iso effective doses and the alpha/beta value by comparing results following radiosurgery and radiotherapy for Arteriovenous malformations of the brain. *J Neurosurg.* 2006; 105: 183-189.
- Hall EJ, Brenner DJ. The radiobiology of radiosurgery: rationale for different treatment regimes for AVMs and malignancies. *Int J Radiat Oncol Biol Phys.* 1993; 25: 381-385.
- Pellettier L, Blomquist E. Differences in radiosensitivity between brain, small and large arteriovenous malformations. A tentative explanation of the incongruent results of radiotherapy. *Med Hypotheses.* 1999; 52: 551-556.
- Blamek S, Larysz D, Miszczyk L. Stereotactic linac radiosurgery and hypofractionated stereotactic radiotherapy for pediatric arteriovenous malformations of the brain: experiences of a single institution. *Childs Nerv Syst.* 2013; 29: 651-656.
- Touboul E, Al Halabi A, Buffat L, Merienne L, Huat J, Michel Schlienger, et al. Single-fraction stereotactic radiotherapy: a dose-response analysis of arteriovenous malformation obliteration. *Int J Radiat Oncol Biol Phys.* 1998; 41: 855-861.
- Zabel A, Milker-Zabel S, Huber P, Schulz-Ertner D, Schlegel W, Dimitrios LK, et al. Treatment outcome after linac-based radiosurgery in cerebral arteriovenous malformations: retrospective analysis of factors affecting obliteration. *Radiother Oncol.* 2005; 77: 105-110.
- Blamek S, Tarnawski R, Miszczyk L. Linac-based stereotactic radiosurgery for brain arteriovenous malformations. *Clin Oncol (R Coll Radiol).* 2011; 23: 525-531.
- Veznedaroglu E, Andrews DW, Benitez RP, Downes MB, Werner-Wasik M, Maria, et al. Fractionated stereotactic radiotherapy for the treatment of large arteriovenous malformations with or without previous partial embolization. *Neurosurgery.* 2004; 55: 519-530.
- Lindvall P, Bergström P, Löfroth PO, Hariz MI, Henriksson R, Jonasson P, et al. Hypofractionated conformal stereotactic radiotherapy for arteriovenous malformations. *Neurosurgery.* 2003; 53: 1036-1042.
- Jones J, Jang S, Getch CC, Kepka AG, Marymont MH. Advances in the radiosurgical treatment of large inoperable arteriovenous malformations. *Neurosurg Focus.* 2007; 23: e7.
- Blamek S, Larysz D, Miszczyk L, Idasiak A, Rudnik A, Rafał Tarnawski, et al. Hypofractionated stereotactic radiotherapy for large or involving critical organs cerebral arteriovenous malformations. *Radiol Oncol.* 2013; 47: 50-56.
- Altschuler EM, Lunsford LD, Coffey RJ, Bissonette DJ, Flickinger JC. Gamma knife radiosurgery for intracranial arteriovenous malformations in childhood and adolescence. *Pediatr Neurosci.* 1989; 15: 53-61.
- Lunsford LD, Kondziolka D, Flickinger JC, Bissonette DJ, Jungreis CA, Maitz AH, et al. Stereotactic radiosurgery for arteriovenous malformations of the brain. *J Neurosurg.* 1991; 75: 512-524.
- Nicolato A, Lupidi F, Sandri MF, Foroni R, Zampieri P, Mazza C, et al. Gamma Knife radiosurgery for cerebral arteriovenous malformations in children/adolescents and adults. Part II: Differences in obliteration rates, treatment-obliteration intervals, and prognostic factors. *Int J Radiat Oncol Biol Phys.* 2006; 64: 914-921.
- Mahajan A, Manchandia TC, Gould G, Bulsara KR. De novo arteriovenous malformations: case report and review of the literature. *Neurosurg Rev.* 2010; 33: 115-119
- O'Lynnngar TM, Al-Holou WN, Gemmete JJ, Pandey AS, Thompson BG, Garton HJ, et al. The effect of age on arteriovenous malformations in children and young adults undergoing magnetic resonance imaging. *Childs Nerv Syst.* 2011; 27: 1273-1279.
- Kashiwazaki D, Kobayashi R, Houkin K, Kuroda S. Increased expression of vascular endothelial growth factor and its receptor in enlarging brain arteriovenous malformations--a case report. *Br J Neurosurg.* 2014; 28: 119-121.
- Zuccaro G, Argañaraz R, Villasante F, Ceciliano A. Neurosurgical vascular malformations in children under 1 year of age. *Childs Nerv Syst.* 2010; 26: 1381-1394.
- Du R, Hashimoto T, Tihan T, Young WL, Perry V, Lawton MT, et al. Growth and regression of arteriovenous malformations in a patient with hereditary hemorrhagic telangiectasia. Case report. *J Neurosurg.* 2007; 106: 470-477.
- Weil AG, Li S, Zhao JZ. Recurrence of a cerebral arteriovenous malformation following complete surgical resection: A case report and review of the literature. *Surg Neurol Int.* 2011; 2: 175.
- Lee J, Tanaka T, Westgate S, Nanda A, Cress M, Litofsky NS, et al. Hypofractionated stereotactic radiosurgery in a large bilateral thalamic and basal ganglia arteriovenous malformation. *Case Rep Neurol Med.* 2013; 2013: 631028.
- Pan DH, Kuo YH, Guo WY, Chung WY, Wu HM, Liu KD, et al. Gamma Knife surgery for cerebral arteriovenous malformations in children: a 13-year experience. *J Neurosurg Pediatr.* 2008; 1: 296-304.
- Zabel-du Bois A, Milker-Zabel S, Huber P, Schlegel W, Debus J. Pediatric cerebral arteriovenous malformations: the role of stereotactic linac-based radiosurgery. *Int J Radiat Oncol Biol Phys.* 2006; 65: 1206-1211.