

## Rapid Communication

# F-Wave during a One-Minute Period of Relaxation Imagery in Patients with Cerebrovascular Disease

Suzuki T<sup>1,2\*</sup>, Tani M<sup>1,2</sup>, Ueda S<sup>2</sup>, Fukumoto Y<sup>2</sup>,  
Todo M<sup>2</sup>, Wakayama I<sup>1</sup> and Yoshida S<sup>1</sup>

<sup>1</sup>Graduate School of Health Sciences, Graduate School of Kansai University of Health Sciences, Japan

<sup>2</sup>Clinical Physical Therapy Laboratory, Faculty of Health Sciences, Kansai University of Health Sciences, Japan

\*Corresponding author: Suzuki T, Graduate School of Health Sciences, Graduate School of Kansai University of Health Sciences, Japan

Received: November 21, 2017; Accepted: December 1, 2017; Published: December 18, 2017

## Abstract

Relaxation imagery is used in neurorehabilitation to control hypertonia in the affected arm in patients with cerebrovascular disease. We used the F-wave as an index of spinal neuronal function to investigate the neurological mechanism of relaxation imagery in patients with cerebrovascular disease. We analyzed F-waves in the left thenar muscles after stimulating the left median nerve at the wrist in 4 patients with cerebrovascular disease (mean age: 62.8 ± 8.42 years). All patients had muscular hypertonia in the affected arm and could not voluntarily move the thumb. F-waves were recorded before, during, and after a 1-min period of relaxation imagery. Recording was performed immediately after and at 5, 10, and 15 min after the relaxation imagery period. Persistence, F/M amplitude ratio, and latency were analyzed from the recorded F-waves. Compared with before and after relaxation imagery, persistence and F/M amplitude ratio during relaxation imagery tended to decrease. No significant difference was observed in latency. Persistence and F/M amplitude ratio were affected by the excitability of spinal neuronal function. The results indicate that a 1-min period of relaxation imagery may decrease the excitability of spinal neuronal function in patients with cerebrovascular disease who have hypertonia in an affected arm.

**Keywords:** F-wave; Relaxation imagery; Cerebrovascular disease

## Abbreviations

CVD: Cerebrovascular Disease

## Introduction

We use relaxation imagery in neurorehabilitation to reduce hypertonia in affected muscles in patients with cerebrovascular disease (CVD). However, the neurological mechanism and effect of relaxation imagery in patients with CVD is unclear. A previous study analyzed F-waves before, during, and after a 1-min period of relaxation imagery in 15 healthy subjects [1]. No significant differences were observed in the abovementioned parameters obtained at rest, during, or after relaxation imagery. However, the F/M amplitude ratio, as an index of spinal neuronal excitability during relaxation imagery, was used to separate subjects into those with lower excitability, unchanged excitability, and higher excitability. Subjective evaluation is very important in changing spinal neuronal excitability with relaxation imagery. In subjective evaluation of relaxation imagery methods, almost all subjects in the lower excitability group said they performed “relaxation imagery of the hand and thumb.” In the higher excitability group, almost all subjects said they performed “relaxation imagery of the whole body.” These results indicate that performing 1-min relaxation imagery focused on decreasing muscle tone in a specific area may decrease the excitability of spinal neuronal function in healthy subjects. This study investigated the effect of a 1-min period of relaxation imagery in patients with CVD, using F-wave as an index of spinal neuronal function.

## Methods

Four patients with CVD (mean age: 62.8 ± 8.42 years) participated

in this study. All patients had hypertonia of affected thenar muscles and could not move the thumb voluntarily. Subjects were placed in a comfortable supine position. The skin was prepared with abrasive gel to maintain impedance below 5 KΩ. A VIASYS Viking Quest electromyography machine (Natus) was used to record F-waves. We tested F-waves in the affected thenar muscles with a pair of round disks attached to the skin with collodion over the muscle belly and the metacarpophalangeal joint of the affected thumb after stimulating the median nerve before, during, and after 1-min of relaxation imagery; recording was performed immediately after and at 5, 10, and 15 min after the relaxation imagery period. The stimulating electrodes comprised a cathode placed over the affected median nerve 3cm proximal to the palmar crease of the wrist joint and an anode placed 2 cm further proximally. The maximal stimulus was determined by delivering 0.2-ms square-wave pulses of increasing intensity to elicit the largest compound muscle action potentials. Supramaximal shocks (adjusted up to a value 20% higher than the maximal stimulus) were delivered at 0.5Hz for the acquisition of F-waves. The bandwidth filter ranged from 2Hz to 3kHz. Subjects were asked to perform relaxation imagery involving the affected thumb muscles. The F-waves from 30 trials were analyzed with respect to persistence, F/M amplitude ratio, and latency. Persistence was defined by the number of measurable F-wave responses divided by 30 trials of supramaximal stimulation. The F/M amplitude ratio was defined as the mean amplitude of all responses divided by the amplitude of the M-wave. Latency was defined as the mean latency from the time of stimulation to the onset of a measurable F-wave. This study was approved by the Research Ethics Committee at Kansai University of Health Sciences. The experiments were conducted in accordance with the Declaration of Helsinki. The authors report no conflict of interest.

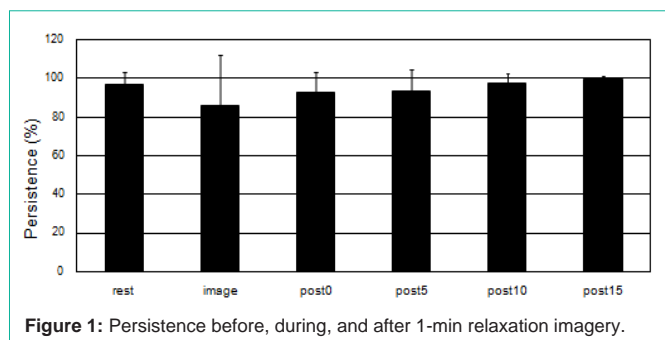


Figure 1: Persistence before, during, and after 1-min relaxation imagery.

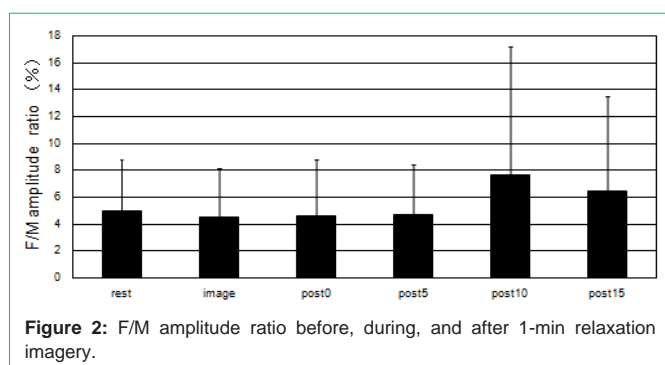


Figure 2: F/M amplitude ratio before, during, and after 1-min relaxation imagery.

## Results

Compared with before and after relaxation imagery, persistence and F/M amplitude ratio during the 1-min relaxation imagery tended to decrease (Figure 1 and 2). However, no significant difference was shown in latency before, during, and after the 1-min relaxation imagery. Typical F-waves are shown in Figure 3.

## Discussion

A literature search was conducted on relaxation methods for hypertonic muscle using physical therapy in patients with CVD. However, no studies on relaxation imagery were found.

The authors have conducted neurophysiological research using negative motor imagery and relaxation imagery in healthy subjects. Sohn et al [2] performed transcranial magnetic stimulation in 7 healthy subjects using imagery of movement suppression. Compared with the control state (no imagery), motor-evoked potential amplitudes of the first dorsal interosseus (but not the abductor pollicis brevis/abductor digiti minimi) muscle were significantly suppressed in negative motor imagery. However, the amplitudes and persistence of F-waves were unchanged during negative motor imagery. This result demonstrates that excitatory cortico spinal drive is suppressed with imagery of movement suppression, but spinal excitability is unchanged.

A previous study evaluated 1-min periods of relaxation imagery in healthy subjects [1]. F-waves of the left thenar muscles were analyzed in 15 healthy subjects (9 men, 6 women; mean age,  $27.9 \pm 9.2$  years) after stimulation of the left median nerve at the wrist at rest, and during and after a 1-min period of relaxation imagery. No significant differences were observed in the abovementioned parameters obtained at rest, during, or after relaxation imagery (at any time points). However, the F/M amplitude ratio, as an index

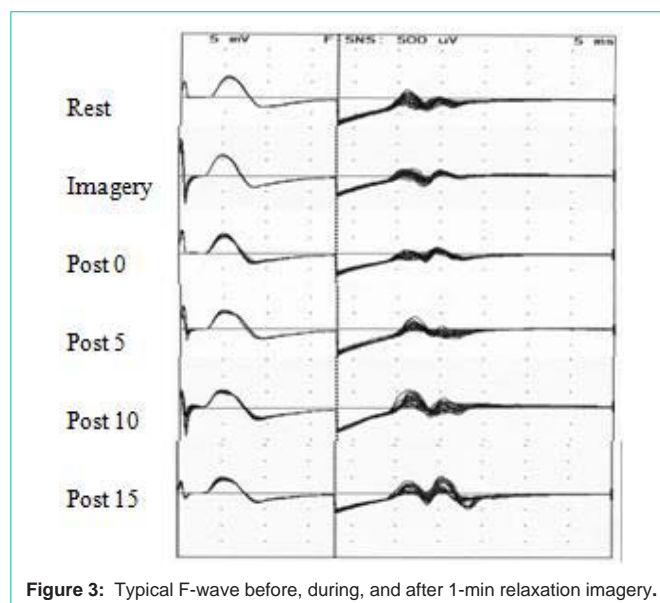


Figure 3: Typical F-wave before, during, and after 1-min relaxation imagery.

of spinal neuronal excitability, was used to separate subjects into those with lower excitability, unchanged excitability, and higher excitability. In subjective evaluation of relaxation imagery methods, almost all subjects in the lower excitability group said they performed “relaxation imagery of the hand and thumb.” In the higher excitability group, almost all subjects said they performed “relaxation imagery of the whole body.” These results indicate that a 1-min period of relaxation imagery does not change the excitability of spinal neurons in healthy subjects. However, performing relaxation imagery focused on decreasing muscle tone in a specific area may decrease the excitability of spinal neurons.

This study evaluated 4 patients with CVD who could not move the thumb voluntarily due to hypertonia of the affected thenar muscles. We asked the subjects to perform “relaxation imagery of the hand and thumb.” However, as there were only 4 patients, we could not perform statistical analysis.

Compared with before and after relaxation imagery, persistence and the F/M amplitude ratio as an index of the excitability of spinal neuronal function during 1-min relaxation imagery tended to decrease. This result indicated that a 1-min period of relaxation imagery may decrease the excitability of spinal neuronal function in patients with CVD who have hypertonia in the affected arm. In a future study, we will evaluate 2-min relaxation imagery in patients with CVD. The data for 2-min relaxation imagery in healthy subjects have already been obtained [3]. The F/M amplitude ratio was lower under conditions of relaxation imagery than at rest, but either recovered or continued to decrease after relaxation imagery. In a comparison of F-wave data using 1-min and 2-min relaxation imagery in healthy subjects, the F/M amplitude ratio with 2-min relaxation imagery decreased more than that with 1-min relaxation imagery. We think that a period of relaxation imagery can decrease spinal neuronal function.

## Conclusion

The study results suggest that a 1-min period of relaxation imagery may decrease the excitability of spinal neuronal function in

patients with CVD who have hypertonia in an affected arm.

## References

1. Suzuki T, Bunnno Y, Onigata C, Tani M, Uragami S. Excitability of Spinal Neurons During A Short Period of Relaxation Imagery. *Open Gen Int Med J.* 2014; 6: 1-5.
2. Sohn YH, Dang N, Hallett M. Suppression of Corticospinal Excitability During Negative Motor Imagery. *J Neurophysiol.* 2003; 90: 2303-2309.
3. Suzuki T, Bunnno Y, Onigata C, Tani M, Yoneda H, Yoshida T, et al. Excitability of Spinal Neurons during Relaxation Imagery for 2 Minutes. *Int J Neurorehabilitation.* 2014; 1: 105.