

Review Article

# Bilateral Tongue Bite during Epileptic Seizure: Nomenclature and Mechanism

Surya N Gupta<sup>1\*</sup>, Vikash S Gupta<sup>2</sup>

<sup>1</sup>Associated Professor, Pediatric Neurology, CAMC, Charleston, West Virginia, USA

<sup>2</sup>Texila American University, Woolford Ave, Georgetown, Guyana

\*Corresponding author: Surya N. Gupta, Pediatric Neurology, 415 Morris Street, Suite 300, Charleston, WV 25301, USA

Received: August 27, 2014; Accepted: September 26, 2014; Published: September 29, 2014

## Keywords

Tongue Biting; Epileptic Seizure; Puncture Wound.

Unilateral tongue bite is a well known phenomenon during an epileptic event. This may occur in the absence of a demonstrable cerebral lesion. We report the first case of bilateral tongue bite during seizure in a patient with left parietal arteriovenous malformation. We discuss its significance, nomenclature, and mechanism.

A 15-year-old male with the diagnosis of the left parietal arteriovenous malformation presented with new onset partial seizure with secondary generalization. His mother reported blood on his face which she thought might be due to facial injury. Examination of his tongue revealed bilateral tongue bite (Figure). His neurological examination including cutaneous sensation and the electroencephalogram both were normal.

## Discussion

A sequential history of the event, its clinical characteristics, and the occurrence of a similar previous event are essential in making the clinical diagnosis of epileptic seizures. The best indicators of a seizure are the rapid and self-limiting time-course, the post-event confusion, and if present, a bite on the lateral border of tongue. A meta-analysis of the literature reveals that tongue biting during seizures has a sensitivity and specificity of 33% and 96% respectively [1]. Tongue bites have also been reported in non-epileptic seizures [2], syncope [3], and hypoglycemia. It rarely occurs in severe orobuccolingual dystonia and during forceful myoclonus in sleep [4]. Tongue biting in these conditions occurs on the tip of the tongue [5] rather than on the lateral border which is a specific sign for an epileptic seizure [6]. However, its absence does not exclude the diagnosis. In rare occasions it is the sole manifestation of a seizure. It should be noted that the patient may not volunteer the history of tongue bite.

Biting occurs in the clonic phase of a generalized tonic-clonic seizure or during partial seizure with or without secondarily generalization. The laterality of tongue bite in relation to hemispheric focus is variable. In a series of 106 consecutively monitored during

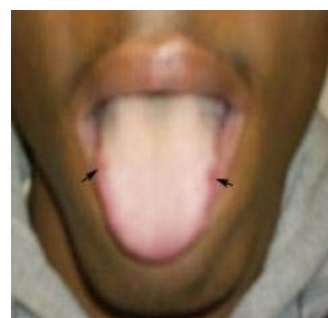
seizure, seven patients with partial epilepsy sustained a tongue injury. Analysis for the relationship between the side of tongue injury and the hemisphere of seizure revealed five patients with tongue injury ipsilateral and two patients with contralateral to the epileptogenic focus [7]. A theoretical explanation for more common ipsilateral location of the injury (5/7) may be that unilateral activation of a genioglossus muscle causes tongue deviation to the opposite side that is activated to opposite cortex, the same phenomenon which causes tongue deviation to the weak side in unilateral genioglossus paresis [8]. What is the possible relationship between the laterality of the tongue bite and the brain lesion? It should be noted that most tongue injury during seizure occurs in the absence of a demonstrable lesion on the brain neuroimaging. This may suggest a common epileptogenic cortical focus with or without a demonstrable lesion.

## Nomenclature and mechanism

Biting versus Puncture wound.

A casual "bite" involves the dorso-ventral surface tip of the tongue. However, biting during seizure involves the lateral border which is not a bite rather a puncture wound. This is an involuntary act caused by lower canines. A sudden and forceful clonic lateral movement of the tongue against clenched lower jaws produces such an injury. The stereotypic position of the puncture wound suggests the position of the tongue and lower canine during the seizure. This likely explains the variability in its occurrence and the presence of a single puncture wound. What is the mechanism for bilateral tongue injury? It is largely unknown. However, we do know that a unilateral epileptic focus can generate an ipsilateral or contralateral injury during seizure. It is possible that other side injury is caused by a following quick and forceful movement of the tongue to opposite side of the first injury that results into the bilateral tongue injury. This may occur reflexively or due to bilateral supranuclear innervations of the genioglossus muscles.

It should be noted that during seizure, bilateral symmetrical site of the puncture wounds from the tip of the tongue suggests that they



**Figure:** The photograph of the lower face shows bilateral tongue-bites (arrows). This photograph was taken 24 hours after seizure.

are caused by the lower canines. It also suggests the likely position of tongue in relation to the lower canines.

## Conclusion

Based on our discussion, we suggest that in the context of an epileptic seizure, “tongue biting” should be referred to as a puncture wound consistent with its unique mechanism. Like our patient, patient with seizure may not volunteer a history of tongue injury. Thus, in an appropriate context or when a seizure is considered, the examination of the lateral border of the tongue for unilateral or bilateral puncture wound should be sought actively.

## Acknowledgements

The authors thank Samira Naime, MD. For reviewing this manuscript.

## References

1. Benbadis SR, Wolgamuth BR, Goren H, Brener S, Fouad-Tarazi F. Value of tongue biting in the diagnosis of seizures. *Arch Intern Med.* 1995; 155: 2346-2349.
2. Stone J, Duncan R. Tongue biting in pseudo seizures and epilepsy. *Practical Neurology.* 2006; 6: 64-65.
3. Hoefnagels WA, Padberg GW, Overweg J, van der Velde EA, Roos RA. Transient loss of consciousness: the value of the history for distinguishing seizure from syncope. *J Neurol.* 1991; 238: 39-43.
4. Seneviratne U. Facio-mandibular myoclonus: a rare cause of nocturnal tongue biting. *Epileptic Disord.* 2011; 13: 96-98.
5. Oliva M, Pattison C, Carino J, Roten A, Matkovic Z, O'Brien T.J. The diagnostic value of oral lacerations and incontinence during convulsive “seizures”. *Epilepsia.* 2008; 49: 962-967.
6. Brigo F, Storti M, Lochner P, Tezzon F, Fiaschi A, Bongiovanni LG, et al. Tongue biting in epileptic seizures and psychogenic events: an evidence-based perspective. *Epilepsy Behav.* 2012; 25: 251-255.
7. Benbadis SR. Tongue biting as a lateralizing sign in partial epilepsy. *Seizure.* 1996; 5: 175-176.
8. De Jong RN. *The neurologic examination.* 5<sup>th</sup> edn. Haerer AF, editor. Philadelphia, JB Lippincott Co. 1992; 251-257.