

Case Report

Dissociated Dislocation of the Lunate and Carpal Bones: Case Report

D'ariento M¹, Galvano N¹, Butera M² and Siragusa F^{3*}

¹Department of Orthopaedic Surgery, University of Palermo, Italy

²Department of Orthopedics and Traumatology, A.R.N.A.S. Ospedale Civico, Palermo, Italy

³Department of Traumatology

*Corresponding author: Siragusa F, Department of Traumatology, Istituto Fondazione San Raffaele Giglio, Cefalù, 90136, Italy

Received: March 20, 2015; Accepted: March 27, 2015;

Published: April 08, 2015

Abstract

Purpose: Fracture-dislocations of the carpus are unusual injuries, which have been reported with different and complex anatomical patterns. Many classifications have been proposed to diagnose and make the choice of treatment easier. We report a case of dissociated fracture-dislocation of the lunate and carpal bones whose pathogenesis and X-rays seem to be peculiar and unable to be classified.

Diagnosis and Treatment: We are presenting a case of a 33-years-old man, who had a high-energy trauma and suffered a "Transradial fracture-dislocation of the navicular and the distal row of carpus and an ipsilateral volar and ulnar luno-triquetral dislocation." After a failed closed reduction, the patient was taken to the operative room, in loco-regional anesthesia, for open reduction, ligaments repair and fixation with K-wires. The wrist was immobilized in a short arm cast. The K-wires and the cast were removed six weeks later.

Results: Full range of motion was recovered after six months. At 1-year follow-up, the Mayo-score was 90/100 and the patient returned to his work as craftsman.

Conclusion: For a correct diagnosis and treatment of this kind of injuries, ligamentous disruption must be considered. In the presented case, prompt open reduction and ligamentous repair, followed by internal fixation and application of a cast, yielded a good short-term outcome.

Keywords: Carpal bones; Lunate dislocation; Dissociated; Radial Styloid; Schneck's classification

Case Presentation

Fracture-dislocation of the carpal bones is rare and usually occurs as result of a high-energy trauma. In 1927 Schneck [1] described the five different types of lesion according to the line of separation of the components of bone and / or joint, distinguishing: perilunate dislocation, transradial-styloid dislocation, trans-scaphoid-perilunate dislocation, peri-scaphoid-perilunate dislocation, and the dislocation of the luno-triquetral coalition, the last two classifications being very rare (Figure 1). In unusual cases, patients may present with a pure dislocation of the lunate resulting from a severe trauma to the ligaments. This specific injury presents with a complex fracture dislocation pattern. A 33-year-old man reported a high-energy trauma to his right wrist following a motorcycle accident. He was admitted to the emergency department of an outlying hospital, where he was diagnosed with a "fracture dislocation of radiocarpal and intercarpal joint as well as the dislocation of the lunate". Despite a closed attempt to reduce the dislocation, a subsequent X-ray of the wrist highlighted the failure to restore normal joint as well as the instability of the lesion. A splint was applied to the injured wrist and the patient was then transported to the University Hospital, where the X-rays showed a "trans-styloid dislocation of the scaphoid and the distalcarpal row as well as the volar and ulnar dislocation of the lunate, pyramidal and pisiform" (Figure 2). The patient did not present with neurovascular deficit but the wrist appeared edematous with obvious deformity. The patient, in plexus anesthesia, has undergone open surgery, through a

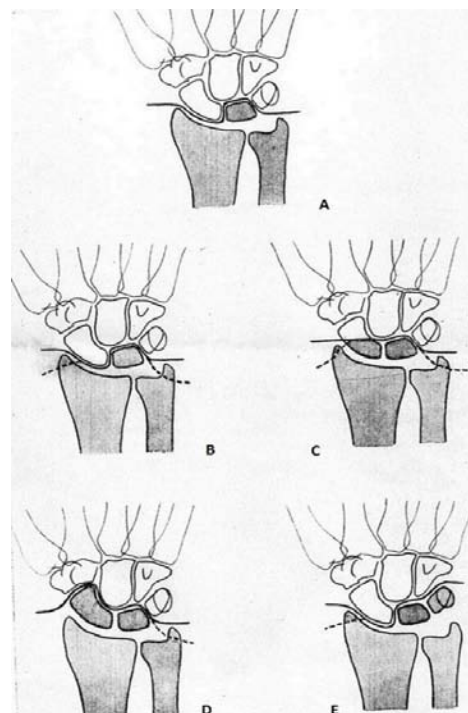


Figure 1: Schneck's classification.

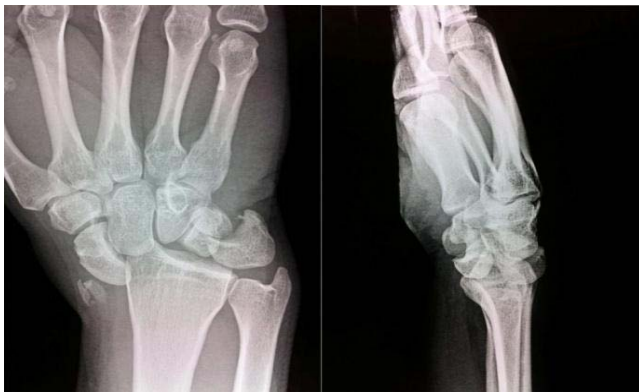

Figure 2: Pre-operative X-rays.

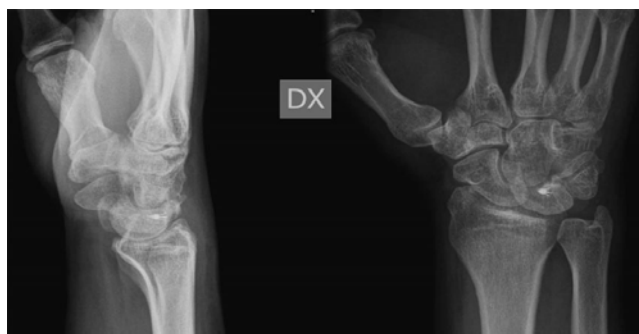

Figure 3: AP and LL X-rays, 6 week after surgery, following removal of the K-wires and the plaster cast.



Figure 4: ROM at 1 year follow-up.

dorsal approach, to reduce the dislocated carpal bones, to repair the scapholunate ligament using an anchor and the application of K-wire between the scaphoid and the lunate. At last, the radial styloid was reduced and fixed with a K-wire. The wrist was then immobilized in a plaster cast that was removed, together with the K wires, after 6 weeks (Figure 3). The patient was given a wrist brace and prescribed an intensive functional rehabilitation program. The patient was checked at 3, 6, 12 months. Pronation/Supination was restored 3 months following the trauma while the flexion-extension was limited to 60° -0° -70°. Normal joint ROM was completely restored at 6 months. After one year, the Mayo Wrist Score was 90/100 and the patient resumed his work as a craftsman (Figure 4).

Discussion

Dorsal perilunate fracture-dislocations of the carpus are far more common than pure dislocations with a ratio of 2:1. The majority of fractures-dislocations are of the trans-scaphoid variety, while the remaining categories of dislocation associated with a fracture have a lower prevalence [2]. To date, there is only one case report concerning a trans-radial styloid perilunate dislocation [3], but no cases of divergent fracture-dislocation and associated with scaphoid and the lunate. Understanding the force transmission helps to identify the injured structures and address the surgical treatment. With regard to the pathogenesis of the case that came to our attention, one can assume that the joint was subjected to two opposing force vectors resulting in the subsequent dislocation and ligament injuries. The fracture of the radial styloid is likely caused by conflict with the scaphoid during radial deviation of the extended wrist, as result of a force exerted on the ulnar side of the carpal bones. In agreement with, is described by Mayfield, in the presence of a complete lesion of the perilunate ligaments, the dorsal dislocated capitate exerts a volar force resulting in lunate dislocation [4,5].

The classifications of Herzberg and Schneck [1], do not take into consideration the deviation in the frontal plane of the carpus. The case presented by us is unusual as it shows an abnormal anatomical alteration, associated with a high degree of instability, which required a direct exposure for restoration of alignment and repair of the stabilizing ligaments, especially the scapholunate. Indeed, despite the total loss of articular connection between the lunate and the homonymous radial fossa being described in previous literature, it was not possible to find another case which described a radial deviation of the carpal components associated with the fracture of the radial styloid and concomitant complete volar-ulnar dislocation of lunate and triquetrum.

References

1. Böhler L, F. Vallardi . *Tecnica del trattamento delle fratture*. Milano. 1955.
2. Herzberg G, Comtet JJ, Linscheid RL, Amadio PC, Cooney WP, Stalder J. Perilunate dislocations and fracture-dislocations: A multicenter study. *J Hand Surg Am*. 1993; 18: 768-779.
3. Sagini D, Gilula LA, Wollstein R. Transradial radial perilunate: a case report. *Am J Orthop*. 2011; 40: E64-66.
4. D'Arienzo M, Falcone L, Acanfora A, Falcone C, Pfanner S, J Hand Surg. The volar lunatedislocation. 1997.
5. Mayfield JK, Johnson RP, Kilcoyne RK. Carpal dislocation: Pathomechanics and progressive perilunar instability. *J Hand Surg Am*. 1980; 5: 226-241.