

## Case Report

# Rare Cause of Nosocomial Urinary Tract Infection in Non Catheterised Patient

Vasireddy Teja<sup>1\*</sup>; Rucha Karad<sup>1</sup>; Malabika Biswas<sup>2</sup>;  
Hardik Patel<sup>1</sup>; Bhoudhyam Bhattacharjee<sup>3</sup>

<sup>1</sup>2<sup>nd</sup> Year Resident Department of Infectious Diseases,  
India

<sup>2</sup>Senior Resident Department of Advanced Microbiology,  
India

<sup>3</sup>1<sup>st</sup> Year Resident Department of Infectious Diseases,  
India

**\*Corresponding author:** Vasireddy Teja

2<sup>nd</sup> Year Resident Department of Infectious Diseases, Flat  
2E, Bangur Complex, Tower-10, Near New Alipore Petrol  
Pump, Kolkata, West Bengal, 700038, India.

Tel: 9490350797

Email: tejavasireddy77@gmail.com

**Received:** October 26, 2023

**Accepted:** November 21, 2023

**Published:** November 28, 2023

## Abstract

**Background:** *Leuconostoc Mesenteroides* are member of the *Streptococcae* family and currently has been recognized as potential pathogen. This cause describes a nosocomial infection caused by *Leuconostoc Mesenteroides* in an patient affected by pulmonary *Mucoromycosis*.

**Case Report:** A 59 year old diabetic and hypertensive male patient was admitted in infectious diseases department with complaint of intermittent cough with hemoptysis, breathlessness since 6 months, then patient was evaluated and found to have pulmonary *Mucoromycosis* and hence patient was started on antifungal treatment, during the treatment patient started complaining of burning micturition and increased frequency from 3 days, then patient was suspected to have hospital acquired urinary tract infection and investigated accordingly. Urine routine analysis revealed 12-16 pus cells and ultrasound abdomen showed cystitis, hence patient was started on Piperacillin and tazobactam after sending urine for culture. Automated and conventional culture methods showed culture of *Leuconostoc Mesenteroides*.

**Conclusion:** We concluded that infections caused by *Leuconostoc Mesenteroides* is serious and should be considered not only in settings of immunocompromised and on prolonged antibiotic use but also in immunocompetent patient.

**Keywords:** *Leuconostoc Mesenteroides*; Urinary tract infections; Urine culture

## Introduction

The Genus *Leuconostoc* is composed by catalase negative and gram positive microorganisms with irregular coccoid morphology [1]. *Leuconostoc* species are commonly saprophytic bacteria are now emerging as one of the opportunistic pathogens [2].

*Leuconostoc* species belonging to the family of *Streptococci* are usually found on vegetables, dairy products, wine and sugar solutions [2].

Advances in the field of microbiology and awareness among the microbiologists led to an increase in the rate of identification of rare opportunistic microorganisms in humans [3].

The outbreak potential of these opportunistic pathogens and their risk of nosocomial transmission have also been documented [4].

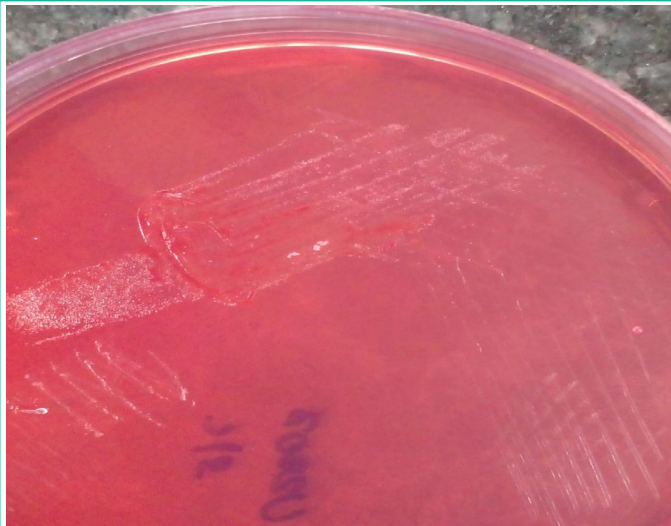
The frequency of *Leuconostoc* infections may be underestimated as they are difficult to detect with routine methods and can be easily misidentified as *Lactobacillus*, *Alpha-hemolytic streptococci*, *Pedococcus*, *Enterococcus* and *Lactococcus* [5].

The vast majority of bacteria are susceptible to Erythromycin, Minocycline, Clindamycin, Ampicillin but are intrinsically resistant to Vancomycin [6].

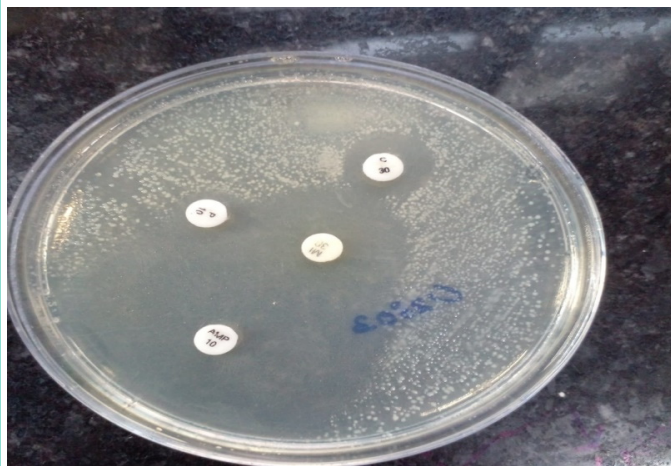
This microorganism may cause endocarditis, urinary tract infections, intraabdominal infections and catheter associated blood stream infections [6].

## Case Report


A 59 year old diabetic and hypertensive male patient was admitted in infectious diseases department with complaint of



Urine culture showing growth of *Leuconostoc Mesenteroides*.



Antibiotic sensitivity testing by Kirby Bauer disc diffusion



method.  
Bile esculin test.

intermittent cough with hemoptysis, breathlessness since 6 months, then patient was evaluated and found to have pulmonary *Mucoromycosis* and hence patient was started on antifungal treatment, during the treatment patient started complaining of burning micturition and increased frequency from 3 days,

then patient was suspected to have hospital acquired urinary tract infection and investigated accordingly. Urine routine analysis revealed 12-16 pus cells and ultrasound abdomen showed cystitis; hence patient was started on Piperacillin and tazobactam after sending urine for culture.

### Diagnosis

Urine culture showed growth only of *Leuconostoc Mesenteroides*. The identification was done both by conventional and automated system. Automated identification was done using VITEK 2 compact (Biomérieux, France), an equipment capable of automatically identifying the microorganism and drug susceptibility, in our case showed growth of *Leuconostoc Mesenteroides*. Conventional culture showed growth of pure non hemolytic tiny bacterial colonies and were catalase and bile esculin negative which suggested growth of *Leuconostoc Mesenteroides* and drug susceptibility done by Kirby-Bauer disc diffusion method showed susceptible to Penicillin, Ampicillin, Clindamycin and resistant to chloramphenicol and vancomycin. Blood cultures were sent in view of any bacteremia and the cultures were negative.

Hence diagnosis of nosocomial urinary infection was made and as isolate is susceptible to Penicillin, therapy with Piperacillin and tazobactam was continued for 7 days and patient was cured of symptoms and repeat urine cultures showed no growth.

### Discussion

The unusual feature of this case report is that our patient did not have any catheter in situ, which could have enhanced the risk of urinary tract infection. Catheter could enhance the risk of infection by *Leuconostoc* as detected in the literature by other case reports. *Leuconostoc* infections remain poorly defined and identification and reporting of *Leuconostoc* species is lacking [2].

*Leuconostoc* species were not considered as pathogens for humans until early eighties until first report as human pathogens was by Swenson et al in 1990 [7].

Site of entry is not clear in infections due *Leuconostoc* species and few reports speculate that the site of entry can be skin [8].

Despite remaining uncommon these pathogens are gaining importance as opportunistic agents of human infections associated with high mortality rates, mainly bacteremia [9].

Although catheter related blood stream infections are the main clinical precautions of *Leuconostoc Mesenteroides* infection, there have been some case reports of meningitis, abscess, urinary infections, peritonitis and intra-abdominal infections [10].

Management of *Leuconostoc* infections consists of appropriate antibiotic therapy and removal of infection source [11].

*Leuconostoc* infections are successfully related with Penicillin, Ampicillin, Carbapenems, Clindamycin and recently by Daptomycin [12].

Despite its low virulence, this microorganism may be considered as potential pathogen not only among immunocompromised but also in immunocompetent patients. This emphasizes that its identification requires special techniques to be performed in an appropriate microbiology laboratory.

## Conclusion

We concluded that infections caused by *Leuconostoc Mesenteroides* is serious and should be considered not only in settings of immunocompromised and on prolonged antibiotic use but also in immunocompetent patient.

## References

1. Ruoff KL, Kuritzkes DR, Wolfson JS, Ferraro MJ. Vancomycin-resistant gram-positive bacteria isolated from human sources. *J Clin Microbiol.* 1988; 26: 2064-8.
2. Swain B, Sahu KK, Rout S. *Leuconostoc lactis*: an unusual cause for bacteremia. *CHRISMED J Health Res.* 2015; 2: 367-9.
3. Karbuz A, Aldemir Kocabaş B, Yalman A, Kuloğlu Z, Derya Aysev A, Çiftçi E, et al. Catheter related *Leuconostoc mesenteroides* bacteremia: A rare case and review of the literature. *J Pediatr Res.* 2017; 4: 35-8.
4. Cappelli EA, Barros RR, Camello TC, Teixeira LM, Merquior VL. *Leuconostoc pseudomesenteroides* as a cause of nosocomial urinary tract infections. *J Clin Microbiol.* 1999; 37: 4124-6.
5. Facklam RR, Collins MD. Identification of *Enterococcus* species isolated from human infections by a conventional test scheme. *J Clin Microbiol.* 1989; 27: 731-4.
6. Meneguetti MG, Gaspar GG, Laus AM, Basile-Filho A, Bellissimo-Rodrigues F, Auxiliadora-Martins M. Bacteremia by *Leuconostoc mesenteroides* in an immunocompetent patient with chronic Chagas disease: a case report. *BMC Infect Dis.* 2018; 18: 547.
7. Swenson JM, Facklam RR, Thornsberry C. Antimicrobial susceptibility of vancomycin-resistant *Leuconostoc*, *Pediococcus*, and *Lactobacillus* species. *Antimicrob Agents Chemother.* 1990; 34: 543-9.
8. Handwerger S, Pucci MJ, Volk KJ, Liu J, Lee MS. Vancomycin-resistant *Leuconostoc mesenteroides* and *Lactobacillus casei* synthesize cytoplasmic peptidoglycan precursors that terminate in lactate. *J Bacteriol.* 1994; 176: 260-4.
9. Ling ML. *Leuconostoc* bacteraemia. *Singapore Med J.* 1992; 33: 241-3.
10. Bou G, Luis Saleta J, Sáez Nieto JA, Tomás M, Valdezate S, Sousa D, et al. Nosocomial outbreaks caused by *Leuconostoc mesenteroides* subsp. *mesenteroides*. *Emerg Infect Dis.* 2008; 14: 968-71.
11. Tholpady SS, Sifri CD, Sawyer RG, Hazen KC, Pruett TL, Bonatti H. *Leuconostoc pseudomesenteroides* blood stream infection following liver transplantation. *Ann Transplant.* 2010; 15: 61-6.
12. Golan Y, Poutsika DD, Tozzi S, Hadley S, Snyderman DR. Daptomycin for line-related *Leuconostoc* bacteraemia. *J Antimicrob Chemother.* 2001; 47: 364-5.