

## Case Report

# Contained Spontaneous Saphenous Vein Graft Rupture Status Post CABG: Optimal Approach to Diagnosis and Treatment

Ha QD<sup>1</sup>, Pham HN<sup>2</sup>, Dang CTM<sup>3</sup>, Liu IZQ<sup>4</sup>, Hoang T<sup>5</sup>, Pham T<sup>3</sup>, Tran VN<sup>1</sup>, Huynh BD<sup>1</sup>, Nguyen DNC<sup>1</sup>, Phan V<sup>1</sup>, Pham D<sup>1</sup>, Nguyen N<sup>6</sup>, Chung D<sup>6</sup>, Pham S<sup>7</sup>, Tran P<sup>8\*</sup>

<sup>1</sup>Department of Medicine, University of Medicine and Pharmacy at Ho Chi Minh City, Vietnam

<sup>2</sup>Department of Cardiovascular Medicine, University of Milan, Italy

<sup>3</sup>Hue University of Medicine and Pharmacy, Vietnam

<sup>4</sup>Midwestern Osteopathic University, USA

<sup>5</sup>Vietnam Military Medical University Faculty of Medicine, Vietnam

<sup>6</sup>Department of Internal Medicine, Pham Ngoc Thach University of Medicine, Vietnam

<sup>7</sup>Unity Health – White County Medical Center, Searcy, AR 72143, USA

<sup>8</sup>Department of Cardiovascular & Osteopathic Medicine Dignity Health – YRMC, Prescott, AZ 86301, USA

\*Corresponding author: Phillip Tran DO, Department of Cardiovascular & Osteopathic Medicine Dignity Health – YRMC, Prescott, AZ, 1521 Majestic Way, Prescott, 86301, USA

Received: July 25, 2022; Accepted: August 23, 2022;

Published: August 30, 2022

## Introduction

Saphenous Vein Graft (SVG) obstruction is a common complication of CABG and the management is well studied [1]. However, contained SVG rupture is a rare complication post CABG. The optimal approach to diagnose and manage this complication is still not fully understood. Multiple factors including clinical characteristics and comorbidities should be considered to decide the best approach of management.

## Case Presentation

A 73-year-old-man was referred to cardiology for evaluation of chronic chest pain and abnormal chest Computed Tomography (CT) scan. A routine follow-up chest CT for a lung nodule showed accumulation of hematoma/seroma in the anterior mediastinum. On review of symptoms, he has experienced chronic significant precordial chest pain for at least 8 months. The pain was described as chest heaviness, associated with dyspnea on exertion and has not changed since it started. Medical history was significant for triple vessel CABG 14 years ago, persistent atrial fibrillation, hypertension, peripheral vascular disease, and mitral valve regurgitation. Electrocardiogram (ECG) demonstrated atrial fibrillation with rapid ventricular response heart rate of 109. His clinical scenario and CT scan raised high suspicion of graft aneurysm versus contained rupture of bypass graft.

## Abstract

Spontaneous rupture of Saphenous Vein Graft (SVG) is a rare complication status post Coronary Artery Bypass Surgery (CABG). Its pathophysiology could depend on several factors including increased vessel wall stress, the size and thickness of the vessel. The optimal approach to diagnose and manage spontaneous SVG rupture remains unclear. Here, we describe a case of a 73-year-old man with a 14-year history of triple vessel CABG who presented with 8 months of chest pain and was found to have contained spontaneous SVG rupture. The chest pain was completely resolved after successful implantation of a covered stent.

**Learning Points:** Spontaneous rupture of SVG is worth to be considered in the differential diagnoses of chest pain status post CABG. Along with patients' comorbidities, coronary angiogram to provide information about anatomy and hemodynamic flow can contribute to individualize the management.

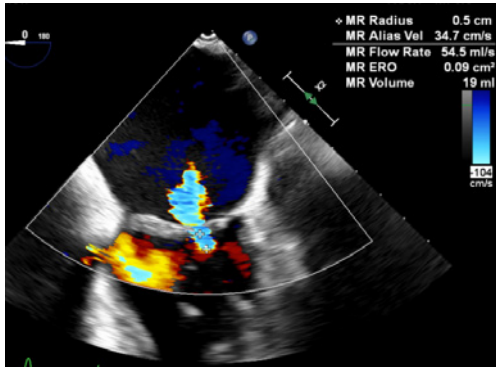
**Keywords:** Spontaneous vein graft rupture; Covered stent; CABG complications; Chest pain status post CABG

Coronary angiogram revealed a severe calcific triple-vessel coronary artery disease with chronic total occlusion of Right Coronary Artery (RCA) including SVG, patent left internal mammary artery to left anterior descending artery, spontaneous contained rupture of distal portion of sequential saphenous vein graft to diagonal and obtuse marginal branch with extensive collateral to the RCA (Figure 1).

Ventriculography showed a left ventricle ejection fraction of 40%. The patient also has moderate to severe mitral regurgitation. At that

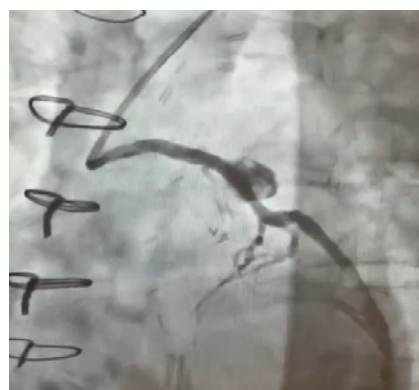

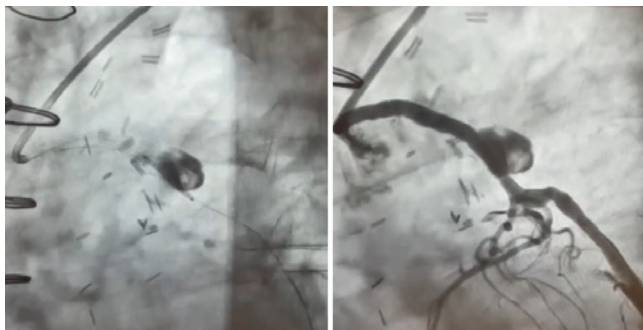Figure 1: Angiogram shows contained spontaneous vein graft rupture.



**Figure 2:** TEE, moderate mitral valve regurgitation.



**Figure 3:** Angioplasty with covered stent (arrow), good flow to the large supplying territory of vein graft compared to before procedure (Figure 1).

time, the best route for revascularization was undecided. We focused on rate control with atenolol up-titrated to 100mg and kept patient on apixaban for thrombotic event prevention. After one month of follow-up, the patient still had chest pain and dyspnea on exertion. Transesophageal Echocardiography (TEE) showed moderate mitral valve regurgitation (Figure 2).

The patient's symptoms are consistent with ischemia which corresponded with decreased flow to the supplying territory of SVG. Decision was made to proceed with angioplasty. A covered stent was successfully implanted to cover the spontaneous contained rupture of vein graft (Figure 3). At two weeks follow-up after the procedure, the patient reported feeling no more chest pain or shortness of breath since the procedure.

## Discussion

Spontaneous aortocoronary graft rupture has an incidence of < 1% and is not mentioned in the current guidelines for management of CABG complication [1,2]. Several complications secondary to SVG rupture were reported, including compression of adjacent structures, myocardial ischemia, and even sudden cardiac death [2,3,5].

From the pathophysiological view, spontaneous rupture of vascular structures can depend on several factors, including wall stress, the thickness of the vessel wall, as well as the size of the vessel [4]. In the case of SVG, the vein is thin-walled and could deteriorate over time, especially if there was saphenous disease prior to CABG. Furthermore, uncontrolled blood pressure post CABG can also play a

role in increasing wall vessel stress.

Diagnosis of SVG rupture can be suggested by Transthoracic Echocardiogram (TTE), TEE, CT scan or Cardiac Magnetic Resonance (CMR) [2,3]. Subsequently, an angiogram of grafts provides not only an anatomical view but also a hemodynamic view of the flow and seems to be the most reliable investigation to confirm diagnosis. Prognosis factors include acute symptoms, the area of supplying territory of vein graft, size of the rupture sac and signs of compression to adjacent structures [4].

Management can be surgery, trans-catheter embolization or stenting with covered stents. Multiple factors including clinical characteristics, comorbidities, anatomy and hemodynamic flow should be considered to decide the favorable management. In this case, the patient has typical ischemic symptoms with chest heaviness and shortness of breath. The vein graft in this case supplies for a very large territory including marginal branch of circumflex artery, diagonal branch, and collaterals to the posterior descending artery of RCA for which trans-catheter embolization is absolutely not indicated. Therefore, the indication for revascularization is appropriate. Furthermore, the moderate severity of mitral regurgitation and comorbidity made him not a good candidate for surgery. Angioplasty with a covered stent was performed successfully which sealed the ruptured vein graft, therefore diverted and increased blood flow to the supplying territory of SVG. This explains the resolution of ischemic symptoms.

## Conclusion

Spontaneous SVG rupture is a rare and potentially fatal long-term complication of CABG surgery. In patients with chest pain statuspost CABG and mediastinal mass, it is worth considering spontaneous rupture of SVG as one of the different diagnoses. Coronary angiogram gives information not only about anatomy but also hemodynamic flow which plays the key role in treatment plan. Optimal management of SVG spontaneous rupture is currently individualized based on the patient symptoms, anatomy as well as hemodynamic flow of grafts, and comorbidities.

## Conflicts of Interest Disclosure

The authors have declared no conflicts of interest.

## References

1. Lawton JS, Tamis-Holland JE, Bangalore S, Bates ER, Beckie TM, Bischoff JM, et al. 2021 ACC/AHA/SCAI Guideline for Coronary Artery Revascularization: A Report of the American College of Cardiology/American Heart Association Joint Committee on Clinical Practice Guidelines. *Circulation*. 2021; 145: CIR000000000001038.
2. Salcedo JD, Bhakta MD, Kern MJ. Aortocoronary saphenous vein graft rupture during diagnostic angiography. *Catheterization and Cardiovascular Interventions*. 2013; 82: 230-234.
3. Gukop P, Karapanagiotidis GT, Chandrasekaran V. Ruptured saphenous vein graft aneurysm. *European journal of cardio-thoracic surgery: official journal of the European Association for Cardio-thoracic Surgery*. 2014; 45: 1111-1112.
4. Davey P, Gwilt D, Forfar C. Spontaneous rupture of a saphenous vein graft. *Postgraduate Medical Journal*. 1999; 75: 363-364.
5. Davey P, Gwilt D, Forfar C. Spontaneous rupture of a saphenous vein graft. *Postgraduate Medical Journal*. 1999; 75: 363-364.