

## Research Article

# Urethroplasty in Children: Experience at Tertiary Care Hospital, Peshawar, Pakistan

Khan MK<sup>1</sup>, Haroon N<sup>2\*</sup>, Arshad<sup>1</sup>, Kakakhel MK<sup>1</sup>, Ullah N<sup>1</sup> and Wahab MU<sup>1</sup>

<sup>1</sup>Institute of kidney diseases, Peshawar, Pakistan

<sup>2</sup>Lady Reading Hospital Peshawar, Pakistan

\*Corresponding author: Naveed Haroon, Lady Reading Hospital Peshawar, Pakistan

Received: September 25, 2021; Accepted: October 26, 2021; Published: November 02, 2021

## Abstract

**Objectives:** The aim of this study is to share single center experience of urethroplasty in pediatric age group.

**Material and Methods:** All boys of age less than 14 years who underwent urethroplasty at institute of kidney diseases from July 2017 to December 2020 are included in this study. The details received from hospital record system on a structured proforma and analysis was performed with SPSS version 20.

**Results:** Total 75 pediatric patients with mean age of  $8 \pm 3.2$  years are included. The main etiology identified was trauma (57.3%) followed by iatrogenic (30.7%), unknown/ idiopathic (8%) and post inflammatory (4%) causes. The commonest site of urethral stricture was bulbar (62.7%), which resulted in the majority of cases from trauma. Other sites were penile in 21% and posterior urethral in 16%. The end to end urethroplasty was the leading surgical procedure (85.3%) in these patients, penile skin flap and two stage urethroplasties were performed in 9.3% and 5.3% patients respectively. Urethroplasty was found highly successful (93.3%) in the treatment of urethral stricture disease.

**Conclusion:** Children with history of perineal trauma and urethral instrumentation needs proper evaluation for lower urinary tract symptoms, as there is high suspicion of urethral stricture disease. Urethroplasty as the treatment of urethral stricture disease when performed in the specialized center is very effective modality of treatment.

**Keywords:** Urethral stricture; End to end urethroplasty; Penile skin flap urethroplasty; Two stage urethroplasty; Visual optical urethrotomy

## Introduction

Urethral stricture is the final common result of a variety of insults to the urethra. Urethral stricture is defined as "Permanent narrowing of the urethra which impede urinary flow during voiding", it is one of the earliest urologic problem [1]. The terms urethral stricture and urethral rupture should be differentiated. The stricture is narrowing of urethral lumen, which results from changes in the urethral wall caused by either trauma or inflammation. Rupture is separation (partial or complete) of the traumatized urethral margins, which subsequently result in the formation of fibrous tissue in between the two ends [2]. Its management has a couple of challenges in the form of small pelvic confines, narrow caliber urethra and fragile perianal tissue [3]. The common causes are trauma from pelvic fracture, straddle and iatrogenic urethral injuries [4].

When treating urethral stricture disease, several factors should be considered before constructive procedure. Site, size, etiology and previous interventions help guide proper treatment option. Urethral dilatation was the earliest modality of treatment [1], later in 1974 Sachse introduced the direct vision internal urethrotomy by cold-knife incision [5]. In about half of the children the urethral dilatation and direct visual urethrotomy is deemed unsuccessful, so urethroplasty should be considered earlier in the management plan [6]. Still the major treatment options currently includes optical urethrotomy (less than 1-2 cm) and urethroplasty (preferred) [7].

Here we are sharing our experience of urethroplasty in children, regarding etiology, site of stricture, procedures performed and treatment outcome.

## Materials and Methods

Following approval from research ethics committee of the institute of kidney diseases and transplant, this observational study included all boys of age less than 14 years who underwent urethroplasty in this institute from July 2017 to December 2020. The outcome was defined by the satisfactory micturition stream noted clinically and continuity of the full length urethral calibre by micturition cystourethrogram. The data collected retrospectively from hospital record system, which detailed the age, aetiology, location of stricture, type of surgical modality and finally the outcome. The analysis was done with IBM<sup>®</sup> SPSS<sup>®</sup>, version 20.0.

## Results

This study included 75 patients of urethroplasty for urethral stricture with mean age of 8 years (Std. Deviation 3.2), range (3 to 14 years). The etiology of urethral stricture was trauma in 57.3% (43/75), iatrogenic in 30.7% (23/75), unknown in 8% (6/75) and inflammatory in 4% (3/75). The major cause of bulbar stricture was trauma 65.9% (31/47), that of penile stricture was iatrogenic 81.2% (13/16) and all posterior urethral strictures were caused by trauma 100% (12/12). The etiology by age is shown in Table 1. Broadly up to the age of 5

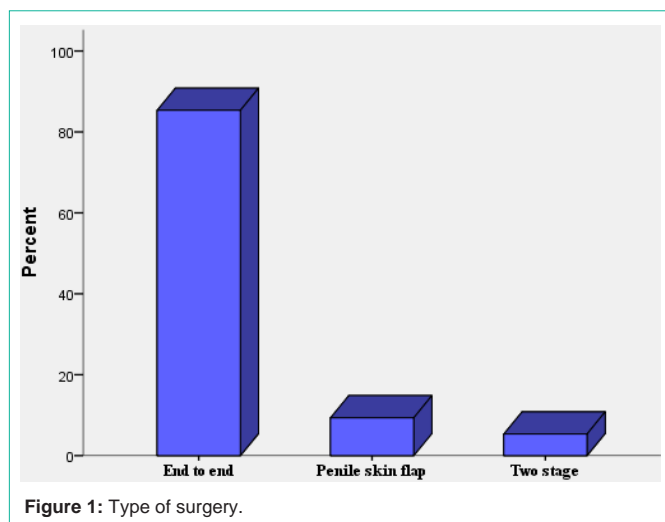


Figure 1: Type of surgery.

Table 1: Etiology noted in patients of different ages.

Age in years	Etiology				Total
	Iatrogenic	Inflammatory	Trauma	Unknown/ Congenital	
3.0	5	0	0	1	6
4.0	5	0	0	1	6
4.5	2	0	0	1	3
5.0	4	1	0	0	5
6.0	3	0	2	0	5
7.0	1	0	4	1	6
8.0	2	1	5	2	10
8.5	0	0	1	0	1
9.0	1	1	5	0	7
10	0	0	4	0	4
10.5	0	0	3	0	3
11.0	0	0	6	0	6
11.5	0	0	1	0	1
12.0	0	0	4	0	4
13.0	0	0	3	0	3
13.5	0	0	1	0	1
14.0	0	0	4	0	4
<b>Total</b>	<b>23</b>	<b>3</b>	<b>43</b>	<b>6</b>	<b>75</b>

years the leading cause was iatrogenic 80% (16/20), between 6-10 years major cause was trauma 63.6% (21/33) and after 10 years of age all strictures were caused by trauma. The common site was bulbar 62.7% (47/75), followed by penile 21% (16/75) and posterior urethra 16% (12/75). The type of surgical procedure is shown in Figure 1, with end to end urethroplasty performed in the majority of patients that's in 85.3% (64/75), penile skin flap in 9.3% (7/75) and two stage urethroplasty in 5.3% (4/75). The indications for urethroplasty as the required treatment option were, recurrence after Visual optical urethrotomy in 43.7% (26/75), blind stricture in 24% (18/75), failed Visual optical urethrotomy in 21.3% (16/75), longer length (>2cm) in 10.7% (8/75) and re-do surgery in 9.3% (7/75). The urethroplasty

was successful in 93.3% (70/75) and failed to achieve the success in 6.7% (5/75).

## Discussion

The common causes of Urethral Strictures (US) are trauma, iatrogenic and inflammatory, while some develops without known etiology. We found trauma as the main etiology in 57.3% (43/75), iatrogenic in 30.7% (23/75), unknown in 8% (6/75) and inflammatory in 4% (3/75), supported by the study of Herle K et al, and Harshman et al, where they identified trauma in 52% and 48% respectively [8,9]. In a literature review through PubMed by Vetterlein MW et al, which included published articles between 2010 and 2018, they identified iatrogenic (hypospadias related) in 35%, iatrogenic (non hypospadias related) in 13%, trauma in 34 %, congenital/unknown in 13%, inflammatory in 4% and postinfectious in 1% [10]. Kaplan et al, noticed iatrogenic as the main etiology in 59.6%, trauma in 19.2%, congenital in 14.03% and postinfectious in 7% [11]. We have comparable results regarding trauma as the main etiology, showing that trauma is the main cause of US in children, although there is some controversy in the literature about this figure. Children with road traffic accident, fall from height, blunt perineal trauma needs proper work up for lower urinary tract symptoms, as these children are prone to develop urethral stricture.

The sites of urethral stricture is different, depending on the cause or mechanism of urethral injury, like penile and pan urethral locations were commonly noted in a study of 404 urethral stricture diseases patients [12]. This localization is important regarding management and planning the surgical treatment. Over all the bulbar urethra is the common site, in present study it accounted for 62.7% cases, the other sites were penile in 21% and posterior urethra in 16%. This finding is supported by two different studies where bulbar urethra was involved in 93.75 and 62.2% respectively [13,14]. In a study by Chukwubuike in Nigerian population, the location of stricture was bulbar in 81.8%, membranous and penile urethra in 9.1% of cases [15]. An Indian study identified bulbar urethral stricture in 42.8% and penile in 30.9% [12]. In the study of Ibrahim AG et al, 38% were located in bulbar urethra and 50.7% in the bulbo penile urethra [16].

The majority of patients in our study were treated with end-to-end urethroplasty that's in 85.3% (64/75), other procedures were penile skin flap in 9.3% (7/75) and two stage urethroplasty in 5.3% (4/75). In a comprehensive study done by Chaudhari et al, the end to end urethroplasty was found to be the most common type of surgical procedure (71.4%) [17]. Shenfeld et al, in their study which included both children and adolescent, noted the use of end to end urethroplasty in 79% of cases [18]. This showed that end to end urethroplasty is the most prevalent and effective way to treat urethral stricture disease worldwide.

Here we noted the procedure with overall success rate of 93.3%. This finding is supported by the study of Zhou et al, they identified a success rate of 94.7% for simple urethral stricture and 63.6% for complex disease [19]. A single center experience shared by Gupta et al, 82.6% of patients for end to end urethroplasty has excellent outcome [20]. Overall satisfactory voiding of single stage urethroplasty was noted in 84.6% by Ibrahim AG et al, [16]. In the study of Shenfeld et al, which included patients of age 1 to 18 years, who underwent

predominantly (79%) anastomotic urethroplasty overall success was 93% [18]. Chaudhari et al, noted success rate of 85.7% [17]. The study of Zafar et al, identified overall success rate of 81.5% in children with anastomotic urethroplasty [21]. Waterloos et al, shared a referral center experience of urethroplasty in children, they found the procedure highly successful (94.4%) [22]. The excellent outcome noted in literature makes the urethroplasty and especially the end to end anastomosis as the current standard of care both in children and adult population.

## Conclusion

Children with history of perineal trauma and urethral instrumentation needs proper evaluation for lower urinary tract symptoms, as there is high suspicion of urethral stricture disease. Urethroplasty as the treatment of urethral stricture disease when performed in the specialized center is very effective modality of treatment.

## References

1. Heyns CF, Steenkamp JW, De Kock ML. Treatment of male urethral strictures: is repeated dilation or internal urethrotomy useful? *J Urol.* 1998; 160: 356-358.
2. Turner-Warwick R. The prevention of complications resulting from pelvic fracture urethral injuries-and from their surgical management. *Urol Clin N. Amer.* 1989; 16: 335-358.
3. Harshman MW, Cromie WJ, Wein AJ, Duckett JW. Urethral stricture disease in children. *J Urol.* 1981;126: 650-654.
4. Podesta M and Podesta M Jr. Traumatic Posterior Urethral Strictures in Children and Adolescents. *Front. Pediatr.* 2019; 7: 24.
5. Sachse H. Treatment of urethral stricture: Transurethral slit in view using sharp section [Article in German]. *Fortschr Med.* 1974; 92: 12-15.
6. Mazdak H, Khorrami AK, Tolou-Ghamari Z. A Retrospective Survey of Pediatric Urethral Stricture in Isfahan, Iran. *Journal of Comprehensive Pediatrics.* 2019; 10: e88802.
7. Wright JL, Wessells H, Nathens AB, Hollingworth W. What is the most cost-effective treatment for 1 to 2-cm bulbar urethral strictures: societal approach using decision analysis? *Urology.* 2006; 67: 889-893.
8. Herle K, Jehangir S, Thomas RJ. Stricture Urethra in Children: An Indian Perspective. *J Indian Assoc Pediatr Surg.* 2018; 23: 192-197.
9. Harshman MW, Cromie WJ, Wein AJ, Duckett JW. Urethral stricture disease in children. *The Journal of urology.* 1981; 126: 650-654.
10. Vetterlein MW, Weisbach L, Riechardt S and Fisch M. Anterior Urethral Strictures in Children: Disease Etiology and Comparative Effectiveness of Endoscopic Treatment vs. Open Surgical Reconstruction. *Front. Pediatr.* 2019; 7: 5.
11. Kaplan GW, Brock WA. Urethral strictures in children. *The Journal of urology.* 1983; 129: 1200-1203.
12. *UroToday Int J.* 2013; 6: 5.
13. Fall B, Zeondo C, Sow Y, et al. Résultats de l'urétroplastie anastomotique pour rétrécissement de l'urètre masculin [Results of anastomotic urethroplasty for male urethral stricture disease]. *Prog Urol.* 2018; 28: 377-381.
14. Redón-Gálvez L, Molina-Escudero R, Álvarez-Ardura M, Otaola-Arca H, Alarcón Parra RO, Páez-Borda Á. Predictors of urethral stricture recurrence after endoscopic urethrotomy. Factores predictivos de recidiva de estenosis uretral tras uretrotomía endoscópica. *Actas Urol Esp.* 2016; 40: 529-533.
15. Chukwubuike KE, Enebe JT, Nduagubam OC. Urethral injury in children: Experience in a teaching hospital in Enugu, Nigeria. *Proceedings of Singapore Healthcare.* 2020; 29: 151-155.
16. Ahmed Gadam Ibrahim, Nuhu Ali, Sulieman Aliyu, Abubakar Alhaji Bakari, "One-Stage Urethroplasty for Strictures in Maiduguri, North Eastern Nigeria", *International Scholarly Research Notices.* 2012; 2012: 4.
17. Chaudhari R, Sharma A, Shaikh I, Andankar M, Pathak H. Safety and Efficacy of Trans-Perineal Urethroplasty for Management of Post-Traumatic Urethral Strictures in Pediatric Age-Group. *Urologia Internationalis.* 2021; 1-5.
18. Shenfeld OZ, Gdor J, Katz R, Gofrit ON, Pode D, Landau EH. Urethroplasty, by perineal approach, for bulbar and membranous urethral strictures in children and adolescents. *Urology.* 2008; 71: 430-433.
19. Zhou FJ, Xiong YH, Zhang XP, Shen PF. Transperineal end-to-end anastomotic urethroplasty for traumatic posterior urethral disruption and strictures in children. *Asian journal of surgery.* 2002; 25: 134-138.
20. Gupta NP, Mishra S, Dogra PN, Hemal AK, Seth A, Kumar R. Outcome of end-to-end urethroplasty: single-center experience. *Urologia internationalis.* 2009; 82: 179-182.
21. Zafar GM, Hayat S, Amin J, Humayun F. Outcome of anastomotic urethroplasty in traumatic stricture (distraction defect) of posterior urethra in boys. *Arab Journal of Urology.* 2020; 18: 94-100.
22. Waterloos M, Verla W, Spinoit AF, Oosterlinck W, Van Laecke E, Hoebeke P, et al. Urethroplasty for urethral injuries and trauma-related strictures in children and adolescents: a single-institution experience. *Journal of pediatric urology.* 2019; 15: 176.e1-176.e7.