

Case Report

Intraparenchymal Meningioma, A Challenging Diagnosis: Case Report

Khansa Abderrahmen*; Wiem Mansour; Alaa Belhaj;

Mohamed Nidhameddine Kchir; Jalel Kallel

Department of Neurosurgery, National Institute Mongi Ben Hmida of Neurology of Tunis, Faculty of Medicine of Tunisia, Tunisia El Manar University, Tunisia

*Corresponding author: Khansa Abderrahmen

Department of Neurosurgery, National Institute Mongi Ben Hmida of Neurology of Tunis, Road Jabari 1007, Rabta, Tunisia

Tel: 0021699925418

Email: khansaabderrahmen@yahoo.fr

Received: May 19, 2023

Accepted: June 15, 2023

Published: June 22, 2023

Abstract

Background: Primary intraparenchymal meningiomas are extremely rare; their similarities to other intra-axial lesions and the lack of dural adhesion make their presurgical diagnostic approach challenging.

Case Description: A 27-year-old male, with no past medical history, presented to our emergency department for a first time grand mal seizure. Magnetic resonance imaging evidenced a 1,6×1,2 cm mass in the right temporo-parietal region. It was iso intense on T1WI, hyper intense on T2 WI, surrounded by large vasogenic edema and homogeneously enhanced on contrast magnetic resonance imaging with diffusion restriction. During surgery, the tumor was found to be located within the parenchyma with no dural attachment. It was removed en bloc. Histopathological examination confirmed the positive diagnosis of transitional meningioma (WHO Grade I).

Conclusion: Intraparenchymal meningiomas are rarely reported in the literature. Their preoperative diagnosis is extremely difficult to make. Histopathological examination plays a key role for an accurate diagnosis.

Keywords: Meningioma; Intraparenchymal meningioma; Subcortical meningioma; Meningioma without dural attachment

Introduction

Meningiomas are typically extra axial lesions originating from the arachnoid cap and meningothelial cells present in the arachnoid layer of the meninges or Pacchionian granulations. They classically display dural attachment and easily diagnosed by CT and MRI [1].

Intra-axial meningiomas are extremely rare, their unusual intraparenchymal site and the lack of dural adhesion make the presurgical diagnostic approach challenging [1]. Herein we report an unusual case of intraparenchymal meningioma that was not evocated preoperatively.

Case Report

A 27-year-old right-handed man presented to our emergency department for a first time grand mal seizure. This incident was described by the family as a generalized tonic clonic event lasting about 4 minutes with tongue biting and involuntary passing of urine after which he persisted irresponsive and confused during thirty minutes. The patient had no prior medical history, no history of tobacco, alcohol or other substance use and no prior head trauma. The physical examination was unremarkable; there were no focal neurological findings and no

papilledema on fundus. Routine blood tests were within normal limits. An emergent CT scan of the head with no contrast enhancement (Figure 1) showed an extensive low-density area in the right temporo-parietal white matter extending in a finger-like fashion. A subsequent MRI of the head (Figure 2) evidenced a right temporo-parietal subcortical lesion surrounded by large vasogenic edema. The mass, measuring 1,6×1,2 centimeters, is iso intense on T1 MRI, hyper intense on T2 MRI with diffusion restriction. After administration of Gadolinium, a homogeneous uptake of the entire lesion is noted. The first evocated diagnosis was a solitary brain metastasis. Surgical resection of the mass was planned. During operation, a standard right temporo-parietal craniotomy was performed, intraoperative findings confirmed that the dura mater was intact and the tumor was located within the parenchyma (Figure 3). It was clearly demarcated and dissected from the surrounding brain parenchyma and removed en bloc. The patient made an uneventful postoperative recovery. The histopathological examination of the tumor showed features compatible with a transitional meningioma, World Health Organization (WHO) grade I. Immunohistochemical study revealed positive staining of the tumor cells for Vimentin, S-100 and epithelial membrane antigen EMA

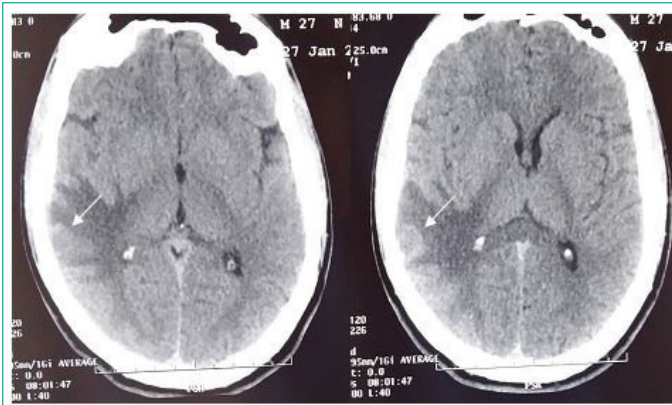


Figure 1: 27-year-old man admitted for grand mal seizure, CT scan of the head with no contrast enhancement showed a right temporo parietal brain edema with a doubt about the presence of a rounded iso dense sub cortical mass (white arrow).

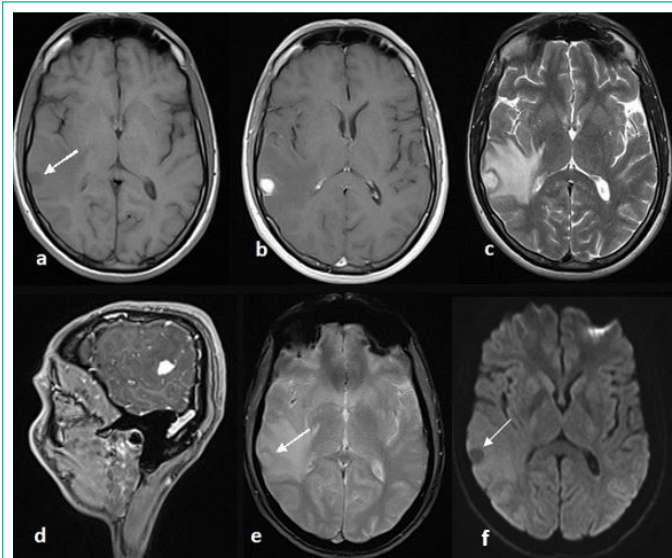


Figure 1: 27-year-old man admitted for grand mal seizure, CT scan of the head with no contrast enhancement showed a right temporo parietal brain edema with a doubt about the presence of a rounded iso dense sub cortical mass (white arrow).

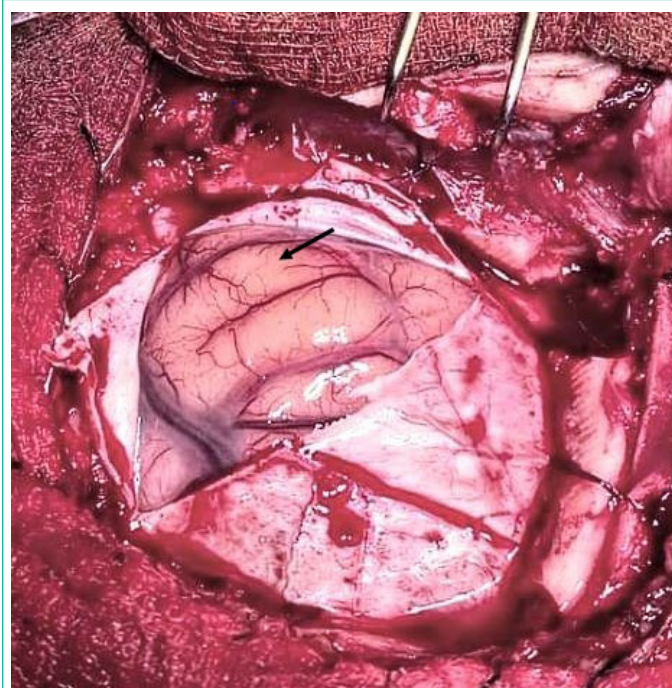


Figure 3: Surgical view, no tumor is seen at the surface of the cortex (black arrow).

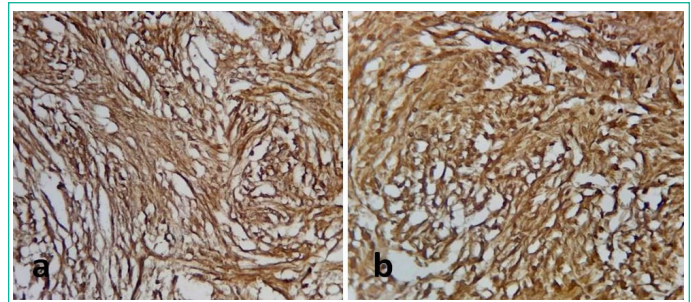


Figure 4: Staining for EMA (a) and vimentine (b) showing diffuse positivity.

(Figure 4). Tumor cells were negative for Smooth Muscle Actin (SMA) Glial Fibrillary Acid Protein (GFAP) and Cytokeratin 7. The Ki 67 labeling index was less than 1%.

Discussion

Extra axial site and broad-based dural attachment are the main imaging features of meningiomas that usually allow an accurate preoperative diagnosis [1-3]. However, both meningiomas without dural attachment and intra axial meningiomas can also occur. They are less common and their preoperative diagnosis is extremely difficult to make on both CT scan and MRI [1,2]. Supratentorial meningiomas without dural attachment were classified by Cushing and Eisenhardt [4] into 5 varieties: 1) intraventricular meningiomas, 2) pineal region meningiomas, 3) deep Sylvian meningiomas, 4) intraparenchymal or subcortical meningiomas, and 5) others, however posterior fossa meningiomas without dural attachment were classified by Abraham and Chandy [5] into 3 varieties: 1) meningiomas originating from the choroid plexus of the fourth ventricle, 2) meningiomas of the inferior telachoroidea, and 3) meningiomas within the cisterna magna.

Subcortical or entirely intraparenchymal meningiomas are very uncommon, they were defined as meningiomas without any dural attachment or connection to the sylvian fissure in spite of cerebral convexity [6] although they can reach the surface of the brain [7].

A systematic review of the literature conducted by Papicet al [8] in 2021 found 52 cases of intraparenchymal meningioma including the case published by the authors.

Almost all of the reported subcortical meningiomas were located in the cerebrum with more than half of the lesions being in the frontal and temporal lobes [8]. They are more common in males than females [1,2,8], the mean age of patients at presentation was 21.1 years, which is younger than that for ordinary meningiomas and the most common presenting symptom was seizure [1,8]. Most authors hypothesized that intraparenchymal meningiomas arise from arachnoid cells located within the pia mater and enter the surface of brain or sulcus with perforating blood vessels [8].

Radiologic features of intraparenchymal meningiomas are usually confusing and mimic other more common intra-axial tumors particularly brain metastases and high-grade gliomas [1,3]. In most reported cases, the lesion was iso-intense or hypo intense on T1 -weighted MRI and hyper intense on the T2-weighted MRI with an homogenous contrast enhancement. In rare cases, the meningioma presented a mixed signal intensity, cystic components or calcifications [8]. Peritumoral edema was frequently encountered [8].

Wada et al [9] noted that peritumoral edema accompanying subcortical meningioma has the particularity to develop from one part of the tumor surface, facilitating the preoperative differential diagnosis between subcortical meningioma and other more common brain tumors. In our case, the diagnosis of meningioma was not evocated before surgery despite the fact that peritumoral edema was mainly present from one part of the tumor surface; in addition, the patient was a young man with no previous history of cancer.

On histologic examination, 59.6% of intraparenchymal meningiomas were WHO grade I, 26.9% were WHO grade II while 13.5% were WHO grade III [8].

Conclusion

A particular attention should be paid to the peritumoral edema accompanying atypical intra-axial lesions mainly in young man patients with no medical history; the presence of edema in one part of the tumor surface may be helpful to evocate the uncommon diagnosis of intraparenchymal meningioma.

References

1. Ramirez-Gruoso R, Patino-Ladino SI, Amortegui-Beltran JA, Rios JL, Estrada-Duque L, Arias J. Intraparenchymal Meningioma. *J Med Cases*. 2021; 12: 32-36.
2. Shigeo O, Masato A, Mitsuhiro H, Yuichi H. Intraparenchymal-Meningioma: Clinical, Radiologic, and Histologic Review. *World Neurosurg*. 2016; 92: 23-30.
3. Tekkök IH, Cinel L, Zorludemir SJ. Intraparenchymal meningioma. *ClinNeurosci*. 2005; 12: 605-8.
4. Cushing H, Eisenhardt L. *Meningiomas without dural attachment*. Springfield (Ill)7 Charles C Thomas. 1938; 133- 68.
5. Abraham J, Chandy J. Meningiomas of the posterior fossa without dural attachment. *J Neurosurg*. 1963; 20: 177 -9.
6. Emoto S, Okada T. A case of subcortical meningioma. *Nippon GekaHokan* 1954; 23: 397- 400.
7. Schroeder BA, Samaraweera RN, Starshak RJ, Oechler HW. Intraparenchymal meningioma in a child: CT and MR findings. *J Comput Assist Tomogr*. 1987; 11: 192-3.
8. Papic V, Lasica N, Jelaca B, Vuckovic N, Kozic D, et al. Primary Intraparenchymal Meningiomas: A Case Report and a Systematic Review. *World Neurosurg*. 2021; 153: 52-62.
9. Wada T, Suzuki M, Beppu T, Arai H, Yoshida Y, et al. A case of subcortical meningioma. *ActaNeurochir (Wien)*. 2000; 142: 209-13.