

## Case Report

# Complete Remission and Extended Survival in a Patient with Recurrent and Metastatic Non-Small Cell Lung Cancer - A Case Report

Manje Gowda A<sup>1\*</sup>, Kaur S<sup>2</sup>, Bansal R<sup>1</sup> and Maroules M<sup>2</sup>

<sup>1</sup>Department of Internal Medicine, New York Medical College at St. Joseph's Regional Medical Center, USA

<sup>2</sup>Department of Hematology Oncology, St. Joseph's Regional Medical Center, USA

\*Corresponding author: Manje Gowda A, Department of Internal Medicine, New York Medical College at St. Joseph's Regional Medical Center, New Jersey 07503, USA

Received: September 15, 2017; Accepted: October 10, 2017; Published: November 09, 2017

## Abstract

Non-small cell cancer of the lung is an aggressive malignancy with a poor prognosis when it presents at an advanced stage. We report the case of a 51 year old Hispanic female who was initially diagnosed with stage 2 adenocarcinoma of the right lung for which she underwent curative treatment with lobectomy and post-operative chemotherapy; however the disease course was complicated by recurrence of the primary tumor and progression of the disease with development of multiple, recurrent brain and spinal metastases despite receiving different lines of chemotherapy. Due to EGFR positive status of her tumor, she was then placed on EGFR-tyrosine kinase inhibitor-Erlotinib. She achieved complete remission and has been free of the disease for the past 3 years with a prolonged survival of nearly 8 years since diagnosis, which is the longest reported so far known to us.

**Keywords:** Recurrent non-small cell lung cancer; Metastatic lung adenocarcinoma; Brain metastases; EGFR tyrosine kinase inhibitors

## Abbreviations

NSCLC: Non-Small Cell Lung Cancer; EGFR-TKIs: Epidermal Growth Factor Receptor-Tyrosine Kinase Inhibitors; PFS: Progression Free Survival; OS: Overall Survival

## Case Presentation

51-year old Hispanic female who was a non-smoker and with no past medical history was diagnosed with stage 2 adenocarcinoma of the right upper lobe in May 2009 for which she underwent right upper lobectomy. She was treated with Carboplatin and Paclitaxel chemotherapy post-operatively. Brain metastases were detected in February 2010 for which she underwent resection of the left frontal lobe lesion along with gamma knife radiation. She was then started on Erlotinib due to EGFR positive status of the tumor, but had to be discontinued after a short duration as she couldn't tolerate it due to adverse effects. The subsequent course of her disease was complicated by multiple recurrences. She had a relapse with a T5 spinal lesion in 2011 for which she underwent radiation to the spine. She was also found to have recurrent brain metastases with a new lesion in the right occipital lobe that was treated with whole brain irradiation in 2011. She had another recurrence in the right upper lobe in August 2013 for which she underwent 5 cycles of palliative chemotherapy with Gemcitabine. However, PET scan done in December 2013, showed a new tumor in the left upper lobe. Around the same time, MRI of the brain revealed progression of her frontal lobe metastatic lesion. Due to progression of her disease, she received Vinorelbine from December 2013 to July 2014. She was then restarted on Erlotinib, which she tolerated well. Serial PET CT scans since March 2015 have showed no recurrence of her disease. Patient is regularly following up in our Oncology clinic and her disease has not recurred for nearly 3 years. She is currently free of symptoms and Erlotinib was stopped in

February 2017 (Figure 1&2).

## Discussion

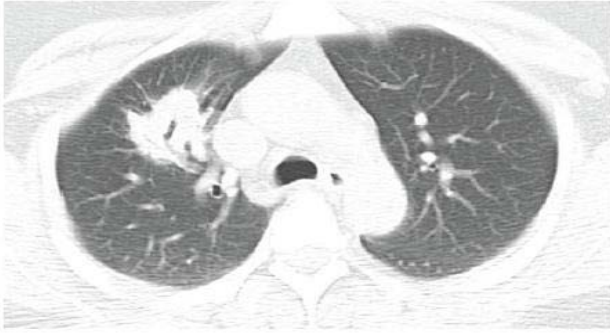Non-Small Cell Cancer (NSCLC) of the lung is an aggressive malignancy with a poor prognosis when diagnosed at an advanced stage [1,2]. Most patients who develop metastatic disease die within a year of diagnosis [2]. We report a case of advanced non-small lung cancer with multiple recurrences despite receiving different lines of chemotherapy, who eventually achieved complete remission, which is a very rare phenomenon.

The median overall survival in metastatic NSCLC with chemotherapy is 8 to 12 months and a median Progression-Free Survival (PFS) is 5 to 6 months [1,2]. With the advent of targeted therapies such as EGFR-Tyrosine Kinase Inhibitors (EGFR-TKIs), the median PFS has been prolonged to an average of 10 to 14 months, and an overall survival of 20 to 30 months [2-6].

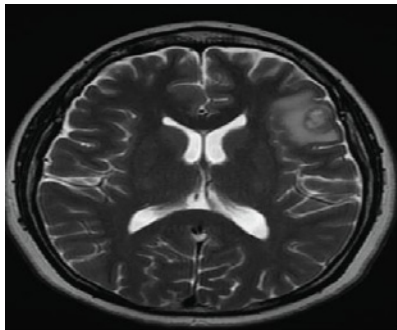
Spontaneous regression has been reported in patients with certain malignancies, such as renal cell carcinoma, neuroblastoma, malignant melanoma, however it is rarely observed in patients with lung cancer [7-10]. Spontaneous regression has been observed in cases accompanied by infection, fever, pregnancy, radiation, trauma or surgery which may play a role in triggering an immune response [7].

There are several possible mechanisms of spontaneous regression of tumors including apoptosis, immunological modulation through release of cytokines such as Interleukin-2, angiogenesis inhibition, telomerase inhibition and antitumor antibodies, such as anti-Hu antibodies and anti-Yo antibodies [11-13].

Park YH et al. [14] and Gladwish et al. [15] reported 2 cases of locally advanced squamous cell cancer who developed spontaneous



**Figure 1: Initial CT of the chest with contrast** - 3cm lesion in right upper lobe, which is suspicious for neoplastic lesion.



**Figure 2: MRI of the brain with contrast enhancement** - There is an enhancing lesion on the left frontal lobe at the gray-white junction with mild perilesional edema measuring 1.3 x 1.5 x 1.1cm suggestive of metastatic disease. There is a second small focus of nodular enhancement in the right occipital lobe of 4.3mm x 3.3mm x 5.0mm.

regression of the tumor without any chemotherapy.

The advent of EGFR-TKIs has changed the course of lung cancer treatment. Erlotinib inhibits tyrosine phosphorylation by blocking the intracellular ATP binding site of epidermal growth factor receptor [16]. It has been studied to be more effective with a better PFS and OS in NSCLC patients who have previously received platinum chemotherapy [17]. It has also been shown to be remarkably effective as a second or third-line treatment in combination with docetaxel and pemetrexed chemotherapy [18]. When used as a second or third-line treatment, erlotinib had minimum side effects, such as dysentery and minor skin irritations [19]. EGFR-TKIs have the ability to cross the blood brain barrier due to their chemical structure and low molecular weights and hence they are efficacious in the treatment of brain metastasis [20].

Very few cases with regression of tumor and prolonged survival after treatment with different lines of chemotherapy have been reported. Suzuki E et al. [21] recently reported a case of a 53 year old woman with EGFR positive left lung adenocarcinoma with bone metastases to the skull and thoracic vertebrae. She received carboplatin plus paclitaxel and bevacizumab therapy and radiation to the thoracic vertebrae. After 6 courses of treatment, a chest CT indicated that the lymphangitis carcinomatosa had disappeared. She was later started on EGFR-TKI as second line therapy. Patient reportedly survived 52 months since the initial diagnosis.

Chonan M et al. [22] described two patients with brain metastasis from EGFR positive non-small cell lung cancer who achieved the total regression of metastasis with the administration of gefitinib. One was a 70-year-old Japanese female diagnosed with EGFR positive lung adenocarcinoma with brain metastases. She was treated with gefitinib for 1 month after which the primary lesion and brain metastasis completely resolved. The other case was a 58-year-old Japanese female diagnosed with metastatic lesion in the left cerebellar hemisphere and meningeal dissemination. She was treated with gefitinib for 3 weeks after which primary lesion, brain metastasis, and meningeal dissemination had completely resolved. In both these cases, the complete resolution occurred within a short period of time [22]. Our patient has survived nearly 8 years since the initial time of diagnosis.

Most cases described are those of spontaneous regression or regression in patients with single recurrence of disease. Very few cases of complete regression of lung cancer after multiple recurrences and development of metastases have been reported. Our case is unique as our patient had recurrence of the primary lung lesion and multiple recurrences of brain metastases on different lines of chemotherapy. The patient has been disease free for nearly 3 years and is doing well.

## Conclusion

This is one of the very few cases of advanced EGFR positive lung adenocarcinoma that has been reported with recurrence of primary tumor and progression of the disease with recurrent multiple brain metastases on different lines of chemotherapy and EGFR-TKI who achieved complete radiological remission of the disease for nearly 2 years with a prolonged survival of nearly 8 years, which is the longest reported so far known to us.

## References

- Schiller JH, Harrington D, Belani CP, Langer C, Sandler A, Krook J, et al. Comparison of four chemotherapy regimens for advanced non-small cell lung cancer. *N Engl J Med*. 2002; 346: 92-98.
- Lin JJ, Cardarella S, Lydon CA, Dahlberg SE, Jackman DM, Jänne PA, et al. Five-Year Survival in EGFR-Mutant Metastatic Lung Adenocarcinoma Treated with EGFR-TKIs. *Journal of Thoracic Oncology*. 2016; 11: 556-565.
- Mok TS, Wu YL, Thongprasert S, Yang CH, Chu DT, Saijo N, et al. Gefitinib or carboplatinpaclitaxel in pulmonary adenocarcinoma. *N Engl J Med*. 2009; 361: 947-957.
- Rosell R, Carcereny E, Gervais R, Vergnenegre A, Massuti B, Felip E, et al. Erlotinib versus standard chemotherapy as first-line treatment for European patients with advanced EGFR mutationpositive non-small-cell lung cancer (EURTAC): a multicentre, open-label, randomised phase 3 trial. *Lancet Oncol*. 2012; 13: 239-246.
- Zhou C, Wu Y-L, Chen G, Feng J, Liu XQ, Wang C, et al. Erlotinib versus chemotherapy as first-line treatment for patients with advanced EGFR mutation-positive non-small-cell lung cancer (OPTIMAL, CTONG-0802): a multicentre, openlabel, randomised, phase 3 study. *Lancet Oncol*. 2011; 12: 735-742.
- Mitsudomi T, Morita S, Yatabe Y, Negoro S, Okamoto I, Tsurutani J, et al. Gefitinib versus cisplatin plus docetaxel in patients with non-small-cell lung cancer harbouring mutations of the epidermal growth factor receptor (WJTOG3405): an open label, randomised phase 3 trial. *Lancet Oncol*. 2010; 11: 121-128.
- Wiernik PH. Spontaneous regression of hematologic cancers. *Natl Canc Inst Monogr*. 1976; 44: 35-38.
- Kumar T, Patel N, Talwar A. Spontaneous regression of thoracic malignancies. *Respir Med*. 2010; 104: 1543-1550.

9. Leo F, Nicholson AG, Hansell DM, Corrin B, Pastorino U. Spontaneous regression of large-cell carcinoma of the lung- a rare observation in clinical practice. *Thorac Cardiovasc Surg*. 1999; 47: 53-55.
10. Cafferata MA, Chiamondia M, Monetti F, Ardizzoni A. Complete spontaneous remission of non-small-cell lung cancer: a case report. *Lung Cancer*. 2004; 45: 263-266.
11. Iwakami S, Fujii M, Ishiwata T, Iwakami N, Hara M, Ihara H, et al. Small-cell lung cancer exhibiting spontaneous regression. *Intern Med*. 2013; 52: 2249–2252.
12. Isobe M, Eikawa S, Uenaka A, Nakamura Y, Kanda T, Kohno S, et al. Correlation of high and decreased NY-ESO-1 immunity to spontaneous regression and subsequent recurrence in a lung cancer patient. *Cancer Immun*. 2009; 9: 8.
13. Chung C, Park DI, Kim SY, Jung SS, Park HS, Moon JY, et al. Spontaneous regression of non-small cell lung cancer that progresses after multiple chemotherapies: A case report. *Thorac Cancer*. 2015; 6: 805-807.
14. Park YH, Park BM, Park SY, Choi JW, Kim SY, Kim JO, et al. Spontaneous regression in advanced squamous cell lung carcinoma. *Journal of thoracic diseases*. 2016; 8: 235-239.
15. Gladwish A, Clark K, Bezzak A. Spontaneous regression in advanced non-small cell lung cancer. *BMJ case reports*. 2010.
16. Clark GM, Zborowski DM, Santabarbara P, Ding K, Whitehead M, Seymour L, et al. Smoking history and epidermal growth factor receptor expression as predictors of survival benefit from erlotinib for patients with non-small-cell lung cancer in the national cancer institute of canada clinical trials group study BR. 21. *Clin Lung Cancer*. 2006; 7: 389–394.
17. Syrigos KN, Saif MW, Karapanagiotou EM, Oikonomopoulos G, De Marinis F. The need for third line treatment in non-small cell lung cancer: an overview of new options. *Anticancer Res*. 2011; 31: 649–659.
18. Ng R, Loreto M, Lee R, Leigh NB. Brief report: retrospective review of efficacy of erlotinib or gefitinib compared to docetaxel as subsequent line therapy in advanced non-small cell lung cancer (NSCLC) following failure of platinum-based chemotherapy. *Lung Cancer*. 2008; 61: 262–265.
19. Shepherd FA, Rodrigues PJ, Ciuleanu T, Tan EH, Hirsh V, Thongprasert S, et al. Erlotinib in previously treated non-small-cell lung cancer. *N Engl J Med*. 2005; 353: 123–132.
20. Cappuzzo F, Ardizzoni A, Soto-Parra H, Gridelli C, Maione P, Tiseo M, et al. Epidermal growth factor receptor targeted therapy by ZD 1839 (Iressa) in patients with brain metastases from non-small cell lung cancer (NSCLC). *Lung Cancer*. 2003; 41: 227–231.
21. Suzuki E, Tanahashi M, Yukiue H, Yosiji N, Shitara M, Fujino T, et al. A Patient with Lung Adenocarcinoma, Lymphangitis Carcinomatosa, and Multiple Bone Metastases Who Achieved Long-Term Survival after Successful Treatment with Carboplatin, Paclitaxel, and Bevacizumab. *Gan To Kagaku Ryoho*. 2016; 43: 617-620.
22. Chonan M, Narita N, Tominaga T. Total regression of brain metastases in non-small cell lung cancer patients harboring EGFR mutations treated with gefitinib without radiotherapy: two case reports. *BMC Res Notes*. 2016; 9: 2.