

Case Report

Malakoplakia of the Vulva Following Lung Transplantation

Jenkins TM and Reyes MC*Department of Pathology and Laboratory Medicine,
Hospital of the University of Pennsylvania, USA***Corresponding author:** Maria Carolina Reyes,
Department of Pathology and Laboratory Medicine,
Hospital of the University of Pennsylvania, Philadelphia,
USA**Received:** June 14, 2017; **Accepted:** September 11,
2017; **Published:** September 19, 2017**Abstract**

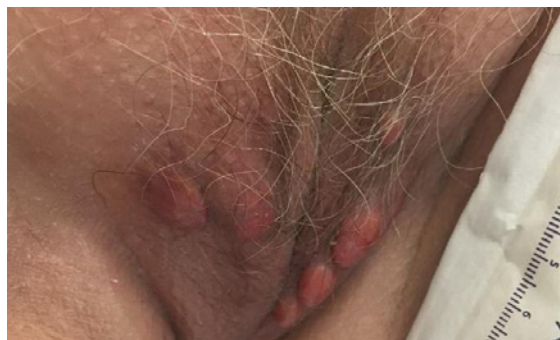
Malakoplakia is a rare histiocytic inflammatory disorder that predominantly affects the urinary tract and rarely the female genital tract. The pathogenesis is hypothesized to be a result of defective bacterial degradation within dysfunctional phagolysosomes, resulting in formation of the pathognomonic Michaelis-Gutmann bodies. Immunocompromised patients are more commonly affected. We present a case of malakoplakia of the vulva and left mainstem bronchus in a 67-year-old postmenopausal immunosuppressed female following bilateral lung transplantation. Multiple painful nodular lesions were present on the labia, which did not respond to multiple courses of antibiotic therapy. Histologic examination revealed a diffuse histiocytic infiltrate with associated lymphocytes, neutrophils, and pathognomonic Michaelis-Gutmann bodies. The patient also complained of progressive cough and was found to have concomitant bronchial malakoplakia, diagnosed after endobronchial biopsy of a nodule at the anastomotic site. Both areas were cultured and grew *Escherichia coli*, the organism most frequently implicated in malakoplakia. After surgical excision, the vulvar lesions did not recur. Malakoplakia is a diagnostic entity that the pathologist should consider in the differential diagnosis when encountered with histiocytic inflammation in the female genital tract. This entity can mimic gynecologic malignancies and can frequently persist and recur if not treated appropriately. In the gynecologic tract, it is a rare occurrence. We present an unusual case of combined malakoplakia involving vulva and lung.

Keywords: Malakoplakia; Vulva; Lung transplant**Case Presentation**

A 67-year-old woman with a past medical history of interstitial lung disease, status post bilateral lung transplant, presented with persistent painful bilateral labial lesions, which first appeared three months post-transplant. The lesions were biopsied and initially diagnosed as an abscess. Additional lesions developed and cultures grew *Escherichia coli*; however, despite treatment with multiple antibiotics and tapering of immunosuppressive agents, the lesions never resolved. A subsequent pelvic exam revealed three to five erythematous papules on bilateral labia measuring up to 4 mm in greatest dimension without spontaneous drainage (Figure 1). The patient underwent complete excision of all vulvar lesions and the specimens were received in surgical pathology.

Microscopic examination revealed a nodular proliferation of sheets of histiocytes occupying the dermis with admixed lymphocytes and neutrophils, underlying an unremarkable epidermis (Figures 2 & 3). Numerous targetoid, basophilic Michaelis-Gutmann bodies were conspicuously seen within the proliferation, highlighted by von Kossa and periodic-acid Schiff stains (Figure 4). Special stains for infectious organisms were negative. A diagnosis of malakoplakia of the vulva was made.

Interestingly, approximately one month prior to the excision of the vulvar lesions, the patient complained of an increasing cough and a bronchoscopy revealed a nodule present in the left mainstem bronchus at the anastomotic site (Figure 5). A biopsy of the lesion

**Figure 1:** Multiple erythematous, firm, bilateral labial nodules.

at the bronchial anastomotic site was diagnostic of malakoplakia. A recent bronchoalveolar lavage prior to bronchoscopy was positive for *E. coli*. The patient was treated with a ten-day course of amoxicillin-clavulanate.

Urine cultures also grew *E. coli* and the patient was treated with two weeks of intravenous ceftriaxone after excision of the vulvar lesions. No additional lesions have developed.

We present an unusual case of simultaneous vulvar and pulmonary malakoplakia following bilateral lung transplantation.

Discussion

Malakoplakia is a rare, benign histiocytic disorder that

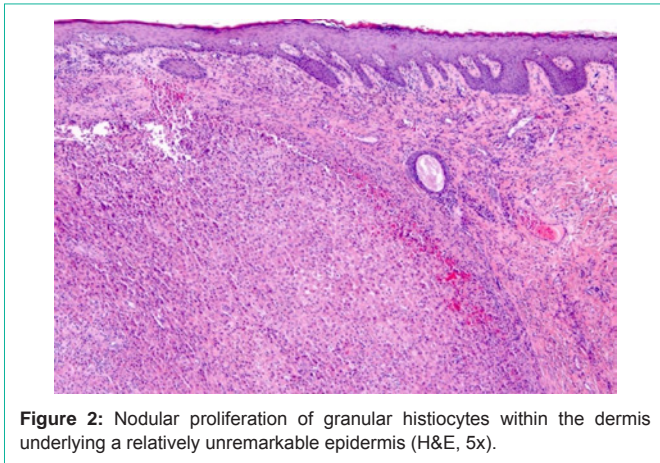


Figure 2: Nodular proliferation of granular histiocytes within the dermis underlying a relatively unremarkable epidermis (H&E, 5x).

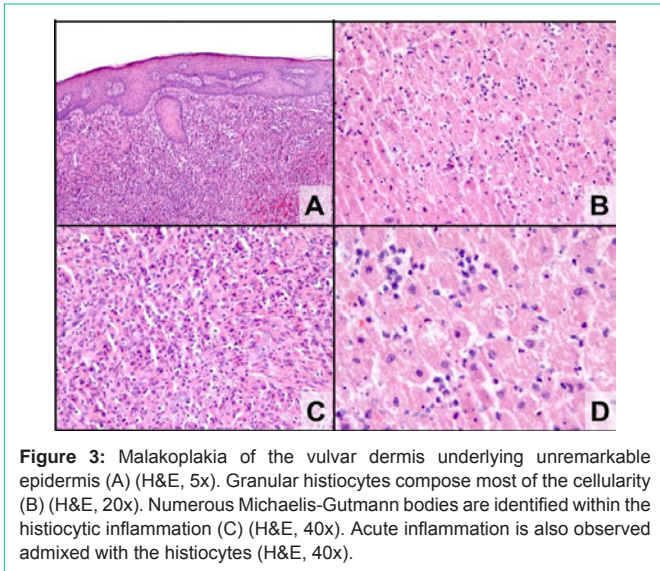


Figure 3: Malakoplakia of the vulvar dermis underlying unremarkable epidermis (A) (H&E, 5x). Granular histiocytes compose most of the cellularity (B) (H&E, 20x). Numerous Michaelis-Gutmann bodies are identified within the histiocytic inflammation (C) (H&E, 40x). Acute inflammation is also observed admixed with the histiocytes (H&E, 40x).

predominantly affects the urinary tract. Less than 500 cases have been reported in the literature [1]. It is well known that malakoplakia more commonly affects immunocompromised patients, specifically solid organ transplant recipients [1]. It was initially described in 1901 by von Hansemann and is also known as von Hansemann’s disease [2]. Malakoplakia is a Greek-derived term and stands for “soft” (malakos) “plaque” (plakos) [2]. Histologically, malakoplakia is characterized by a histiocytic infiltrate with pathognomonic Michaelis-Gutmann bodies: 5-10 μm, targetoid, concentric, basophilic intracellular and extracellular structures. The Michaelis-Gutmann bodies are characteristically positive for von Kossa’s calcium stain, Periodic Acid Schiff (PAS) stain, and iron stain [2].

The pathogenesis of malakoplakia is not well understood; however, recent theories suggest that the disease is an outcome of a bactericidal defect within the histiocyte lysosomes. The defective lysosomes have ineffective microtubule assembly due to a lack of Cyclic Guanosine Monophosphate (cGMP), which prevents the normal degranulation of lysosomes, an essential step in killing bacteria [2]. Lamellar deposition of organic and inorganic materials, such as calcium, iron, and phosphorus, form the classic Michaelis-Gutmann bodies [1,3]. The most commonly implicated organisms are *Escherichia coli*,

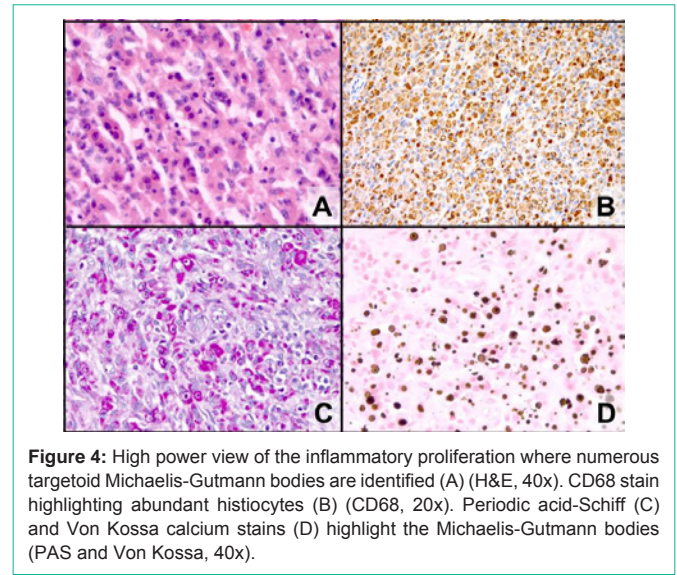


Figure 4: High power view of the inflammatory proliferation where numerous targetoid Michaelis-Gutmann bodies are identified (A) (H&E, 40x). CD68 stain highlighting abundant histiocytes (B) (CD68, 20x). Periodic acid-Schiff (C) and Von Kossa calcium stains (D) highlight the Michaelis-Gutmann bodies (PAS and Von Kossa, 40x).

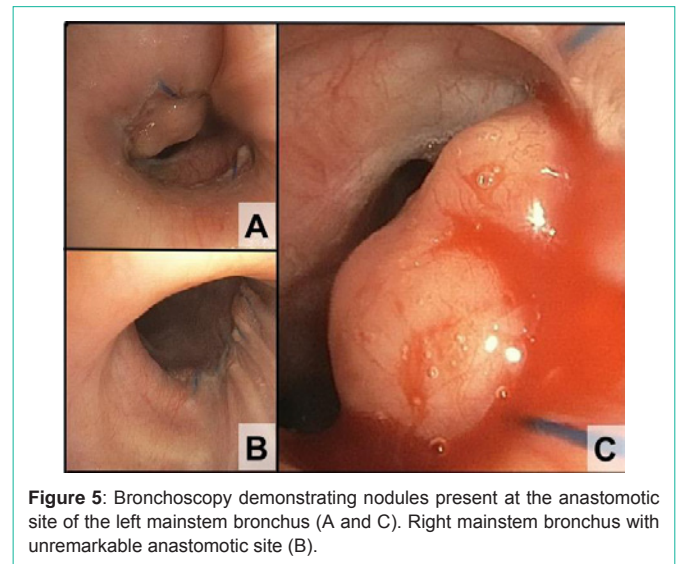


Figure 5: Bronchoscopy demonstrating nodules present at the anastomotic site of the left mainstem bronchus (A and C). Right mainstem bronchus with unremarkable anastomotic site (B).

Staphylococcus aureus, *Pseudomonas aeruginosa*, *Mycobacterium tuberculosis*, *Proteus sp.*, and *Rhodococcus equi* [1,4]. Of these, *Escherichia coli* is by far the most common causative organism [3]. *E. coli* is also the most frequently identified bacterial culprit of urinary tract infections [5], which could explain why malakoplakia is most commonly seen in the urinary tract.

Malakoplakia has been described in numerous organ systems in addition to the urinary tract, including the gastrointestinal tract, skin, lungs, central nervous system, and bone, among others [1]. These lesions have been described less commonly in the female genital tract, including the uterus, cervix, vagina, and, rarely, the vulva [6] (Table 1). Women with genital tract malakoplakia are most commonly post-menopausal with an average age of 60 years [7]. Of all of the female genital tract organs, the vagina is the most common site involved and vaginal bleeding is usually the presenting symptom [7,8]. Vulvar malakoplakia has only been previously reported four times in the literature [6,9-11]. We present an unusual case of simultaneous vulvar and pulmonary malakoplakia following bilateral lung transplantation.

Table 1: Reported cases of malakoplakia affecting the female genital tract.

Case	Reference	Year	Age	Location	Symptoms/History
1	Rao [13]	1969	40	Broad ligament, inguinal area, endometrium	Vaginal bleeding
2	Van der Walt, et al [14]	1973	65	Vagina	Vaginal bleeding
3	Scheiner, et al [8]	1975	29	Fallopian tube	--
4	Arul and Emmerson [11]	1977	75	Vulva	Ulceration; Rheumatoid arthritis
5	Thomas, et al [15]	1977	60	Endometrium	Vaginal bleeding; Rheumatoid arthritis; Sjogren's syndrome
6	Lin, et al [16]	1979	49	Vagina	Hepatitis
7	Cremer and Busanny-Caspari [17]	1979	56	Vagina	Vaginal bleeding
8	Chalvardjian, et al [7]	1980	61	Left ovary, fallopian tube	Vaginal bleeding
9	Chalvardjian, et al [7]	1980	64	Cervix, vagina	Vaginal bleeding
10	Chalvardjian, et al [7]	1980	84	Vagina	Vaginal bleeding; Urothelial carcinoma
11	Wahl [18]	1982	72	Cervix	Vaginal bleeding; Rheumatoid arthritis
12	Wahl [18]	1982	66	Cervix	Vaginal bleeding
13	Willen, et al [19]	1983	71	Uterus and cervix	Vaginal bleeding
14	Molnar and Polliak [20]	1983	69	Endometrium	Diabetes mellitus
15	Chen and Hendricks [8]	1985	83	Cervix, pelvis	Vaginal bleeding; Xanthogranulomatous pyelonephritis
16	Chadha, et al [21]	1985	72	Endometrium	Vaginal bleeding
17	Falcon-Escobedo, et al [22]	1986	--	Cervix	--
18	Paquin, et al [23]	1986	49	Bartholin's gland	Asymptomatic
19	Paquin, et al [23]	1986	61	Bartholin's gland	Tender swelling labium minus; Parkinson's disease
20	Klempner, et al [24]	1987	50	Ovary (left adnexa)	Neurofibromatosis type I
21	Kawai, et al [25]	1988	88	Endometrium	--
22	Stewart and Thomas [26]	1991	--	Cervix and endometrium	Vaginal bleeding; Rheumatoid disease
23	Bessim, et al [10]	1991	44	Vulva , vagina	Fever, vaginal bleeding; Alcohol abuse
24	Koetsawang, et al [27]	1992	67	Endometrium, omentum	Vaginal bleeding
25	Fishman, et al [28]	1993	84	Vaginal cuff	Remote history cervix squamous cell carcinoma
26	Shaikh, et al [29]	1994	28	Uterus	Severe lower abdominal pain, fever
27	Baez-Giangreco, et al [30]	1994	50	Uterus, cervix, vagina	Vaginal bleeding
28	Kogulan, et al [6]	2001	29	Vulva , vagina	Vaginal bleeding and purulent cutaneous nodules; Ureterolithiasis
29	Chou, et al [31]	2002	47	Uterus, ovary, fallopian tube	Diabetes mellitus
30	Agnarsdottir, et al [9]	2004	69	Cervix	Uterine prolapse
31	Agnarsdottir, et al [9]	2004	49	Vulva	Vulvar lesion
32	Ramdial, et al [32]	2008	36	Cervix	Acquired Immunodeficiency Syndrome (AIDS)
33	Ramdial, et al [32]	2008	27	Cervix	Acquired Immunodeficiency Syndrome (AIDS)
34	Mirfazaelian, et al [33]	2015	57	Uterus	Vaginal bleeding
35	Jenkins and Reyes, current case	2017	67	Vulva , left main stem bronchus	Painful vulvar lesions; Bilateral lung transplant

This entity is important for both clinicians and pathologists to recognize and consider in the differential diagnosis when a patient is suspected to have an infectious process, especially when this involves the urogenital tract. Michaelis-Gutmann bodies are not always identified, especially in the early or late stages of malakoplakia [12]. Malakoplakia should be included in the differential diagnosis when a post-menopausal woman presents with vaginal bleeding or lesions of the vagina, vulva, and cervix. Large tumor-like lesions can be mistaken for gynecologic malignancies of the cervix, uterine adnexa, vagina, and vulva. Thus, malakoplakia is important to recognize

both clinically and histologically, as malakoplakia can be cured with surgical or medical therapy.

Conclusion

Malakoplakia is a rare histiocytic inflammatory disorder caused by defective degradation of bacteria by phagolysosomes. Malakoplakia involving the female genital tract, especially the vulva, is rare. We present a case of persistent, painful vulvar malakoplakia and simultaneous bronchial malakoplakia in an immunosuppressed patient after bilateral lung transplant. The vulvar lesions were

unresponsive to antibiotic therapy alone, and surgical excision was necessary. Malakoplakia is an important inflammatory condition to recognize because it can mimic gynecologic malignancies and is usually cured with excision or antibiotic therapy. Pathologists must also be highly suspicious of malakoplakia when confronted with a specimen composed of sheets of foamy histiocytes and an inflammatory background, even if Michaelis-Gutmann bodies are not identified. Correlation with cultures and clinical history is essential.

References

1. Yousef GM, Naghibi B, Hamodat MM. Malakoplakia outside the urinary tract. *Arch Pathol Lab Med.* 2007; 131: 297-300.
2. Dasgupta P, Womack C, Turner AG, Blackford HN. Malakoplakia: von Hansemann's disease. *BJU Int.* 1999; 84: 464-469.
3. Stanton MJ, Maxted W. Malakoplakia: a study of the literature and current concepts of pathogenesis, diagnosis and treatment. *J Urol.* 1981; 125: 139-146.
4. Wick MR. Granulomatous & histiocytic dermatitides. *Semin Diagn Pathol.* 2017; 34: 301-311.
5. Gupta K, Hooton TM, Naber KG, Wullt B, Colgan R, Miller LG, et al. International Clinical Practice Guidelines for the Treatment of Acute Uncomplicated Cystitis and Pyelonephritis in Women: A 2010 Update by the Infectious Diseases Society of America and the European Society for Microbiology and Infectious Diseases. *Clin Infect Dis.* 2011; 52: 103-120.
6. Kogulan PK, Smith M, Seidman J, Chang G, Tsokos M, Lucey D. Malakoplakia involving the abdominal wall, urinary bladder, vagina, and vulva: case report and discussion of malakoplakia-associated bacteria. *Int J Gynecol Pathol Off J Int Soc Gynecol Pathol.* 2001; 20: 403-406.
7. Chalvardjian A, Picard L, Shaw R, Davey R, Cairns JD. Malakoplakia of the female genital tract. *Am J Obstet Gynecol.* 1980; 138: 391-394.
8. Chen KT, Hendricks EJ. Malakoplakia of the female genital tract. *Obstet Gynecol.* 1985; 65: 84S-87S.
9. Agnarsdóttir M, Hahn L, Sellgren U, Willén R. Malakoplakia of the cervix uteri and vulva. *Acta Obstet Gynecol Scand.* 2004; 83: 214-216.
10. Bessim S, Heller DS, Dottino P, Deligdisch L, Gordon RE. Malakoplakia of the female genital tract causing urethral and ureteral obstruction. A case report. *J Reprod Med.* 1991; 36: 691-694.
11. Arul KJ, Emmerson RW. Malakoplakia of the skin. *Clin Exp Dermatol.* 1977; 2: 131-135.
12. Smith B. Malakoplakia of the urinary tract: a study of twenty-four cases. *Am J Clin Pathol.* 1965; 43: 409-417.
13. Rao NR. Malakoplakia of broad ligament, inguinal region, and endometrium. *Arch Pathol.* 1969; 88: 85-88.
14. Van der Walt JJ, Marcus PB, De Wet JJ, Burger AJ. Malakoplakia of the vagina. First case report. *South Afr Med J Suid-Afr Tydskr Vir Geneesk.* 1973; 47: 1342-1344.
15. Thomas W, Sadeghieh B, Fresco R, Rubenstone AI, Stepto RC, Carasso B. Malakoplakia of the endometrium, a probable cause of postmenopausal bleeding. *Am J Clin Pathol.* 1978; 69: 637-641.
16. Lin JI, Caracta PF, Chang CH, Uchwat F, Tseng CH. Malacoplakia of the vagina. *South Med J.* 1979; 72: 326-328.
17. Cremer H, Busanny-Caspari W. [Malacoplacia of the vagina, a rare cause of vaginal bleeding (author's transl)]. *Geburtshilfe Frauenheilkd.* 1979; 39: 214-216.
18. Wahl RW. Malacoplakia of the uterine cervix: report of two cases. *Acta Cytol.* 1982; 26: 691-694.
19. Willén R, Stendahl U, Willén H, Tropé. Malacoplakia of the cervix and corpus uteri: a light microscopic, electron microscopic, and X-ray microprobe analysis of a case. *Int J Gynecol Pathol Off J Int Soc Gynecol Pathol.* 1983; 2: 201-208.
20. Molnar JJ, Poliak A. Recurrent endometrial malakoplakia. *Am J Clin Pathol.* 1983; 80: 762-764.
21. Chadha S, Vuzevski VD, ten Kate FJ. Malakoplakia of the endometrium: a rare cause of postmenopausal bleeding. *Eur J Obstet Gynecol Reprod Biol.* 1985; 20: 181-189.
22. Falcón-Escobedo R, Mora-Tiscareño A, Pueblitz-Peredo S. Malacoplakia of the uterine cervix. Histologic, cytologic and ultrastructural study of a case. *Acta Cytol.* 1986; 30: 281-284.
23. Paquin ML, Davis JR, Weiner S. Malacoplakia of Bartholin's gland. *Arch Pathol Lab Med.* 1986; 110: 757-758.
24. Klempler LB, Giglio PG, Niebles A. Malacoplakia of the ovary. *Obstet Gynecol.* 1987; 69: 537-540.
25. Kawai K, Fukuda K, Tsuchiyama H. Malacoplakia of the endometrium. An unusual case studied by electron microscopy and a review of the literature. *Acta Pathol Jpn.* 1988; 38: 531-540.
26. Stewart CJ, Thomas MA. Malacoplakia of the uterine cervix and endometrium. *Cytopathol Off J Br Soc Clin Cytol.* 1991; 2: 271-275.
27. Koetsawang A, Senapad S, Boriboonhiransarn D, Robertson DI. Malakoplakia of the omentum and endometrium. *Asia Oceania J Obstet Gynaecol.* 1992; 18: 95-98.
28. Fishman A, Ortega E, Girtanner RE, Kaplan AL. Malacoplakia of the vagina presenting as a pelvic mass. *Gynecol Oncol.* 1993; 49: 380-382.
29. Shaikh H, Khan PE, Faridi N. Malakoplakia of the uterus. *J Pak Med Assoc.* 1994; 44: 76-77.
30. Baez-Giangreco A, Afzal M, Chattopadhyay SK. Malacoplakia: extensive female genital tract and skin involvement. *Int J Gynaecol Obstet.* 1994; 45: 159-160.
31. Chou S-C, Wang J-S, Tseng H-H. Malacoplakia of the ovary, fallopian tube and uterus: a case associated with diabetes mellitus. *Pathol Int.* 2002; 52: 789-793.
32. Ramdial PK, Sing Y, Chotey NA, Bagratee JS. Concomitant malacoplakia and granuloma inguinale of the cervix in acquired immune deficiency syndrome. *Int J Gynecol Pathol Off J Int Soc Gynecol Pathol.* 2008; 27: 282-287.
33. Mirfazaelian H, Shariat M, Bedayat GR, Negahban S, Daneshbod Y. Uterine malakoplakia diagnosed in a cervical Pap smear. *Cytopathol Off J Br Soc Clin Cytol.* 2016; 27: 133-134.