

Case Report

Experience with Administration of a Branched-chain Amino Acid- and Carnitine-enriched Enteral Nutrient as a Late Evening Snack in a Patient with Hepatic Cirrhosis

Naoki Hotta*

Department of Internal Medicine, Division of Hepatology, Masuko Memorial Hospital, Japan

*Corresponding author: Naoki Hotta, Department of Internal Medicine, Division of Hepatology, Masuko Memorial Hospital, Aichi, 35-28 Takebashi Nakamura-ku, Nagoya, Aichi, 453-8566, Japan, Tel: 815204511465; Fax: 81524511360; Email: hotta4166@yahoo.co.jp

Received: July 30, 2014; Accepted: October 20, 2014;

Published: October 22, 2014

Abstract

In nutrition therapy for patients with liver cirrhosis, not only administration of branched-chain amino acid (BCAA)-containing preparations but also late-evening snack (LES) therapy is recommended to prevent the starvation-like state in these patients associated with abnormal energy metabolism in the early morning fasting condition. In the present study, we examined the usefulness of a BCAA- and carnitine-enriched enteral nutrient (ENEVO, Abbott Japan Co., LTD.) as an LES in a patient with liver cirrhosis who refused consumption of another enteral nutrient administered as part of the management of hepatic failure, as it produced abdominal distention.

Keyword: Late evening snack; Branched-chain amino acid- and carnitine-enriched enteral nutrient; Hepatic cirrhosis

Case Presentation**Patient**

A 61-year-old man

Chief complaints

General malaise and anorexia

Past history

Unremarkable except for alcoholic hepatitis

Present illness

The patient was under regular outpatient follow-up for alcoholic hepatitis. Two weeks before visiting our hospital, he began to experience anorexia and general malaise.

Status at the present visit: Height, 169 cm; weight, 89 kg; body temperature, 36.2°C; pulse, 72/min (regular); clear consciousness; no conjunctival pallor, scleral icterus, or distended cutaneous veins on the abdominal wall; liver and spleen, not palpable; palmar erythema, present; no pedal edema, spider angioma, asterixis, or tremors.

According to the blood test findings on admission, the residual liver function was classified as Child-Pugh grade B, and the BCAA-to-tyrosine ratio (BTR) was low at 1.73. The serum free fatty acid level was elevated at 1137.00 uEq/L (Table1).

Administration Method of ENEVO

The patient drank a can of ENEVO a day before bedtime for two weeks. A blood sample was collected in the early morning fasting state once a week. The degree of starvation (serum free fatty acid) was assessed in the early morning fasting state to determine the therapeutic effects. As for the secondary variables, the nutritional status (BTR, and serum levels of albumin [Alb], pre-albumin [Pre-Alb], and retinal binding protein [RBP]) was assessed, while the body weight, skeletal muscle mass, and total body fat were determined by Inbody 430.

Clinical Course

Based on the examination of blood samples collected at the time of the visit, the liver function was classified as Child-Pugh grade B; the BTR was low at 1.78. Because no BCAA formulation had been administered previously, administration of a BCAA formulation (Aminoleban EN: protein 13.5 g, BCAA 6.1 g, fat 3.5 g, and carbohydrate 31.1 g; Otsuka Pharmaceutical Co., Ltd.) was initiated at a dose of one pack (containing 50 g; 210 kcal) as an LES. However, the patient developed abdominal distention following consumption of this LES, and refused to continue with the treatment. As the patient also complained of anorexia, administration of ENEVO was initiated. A national registered dietitian interviewed the patient about his dietary habits and instructed him to reduce 300 kcal from his usual caloric intake at the start of the treatment. During the follow-up period, it was confirmed that the patient was consuming the product

Table 1: Labo data.

The residual liver function was classified as Child-Pugh grade B, and the BCAA-to-tyrosine ratio (BTR) was low at 1.73. The serum free fatty acid level was elevated at 1137.00 uEq/L.

Labo data		
Chemistry)	CBC)	(Coagulation)
TP:7.1 g/dl	WBC:4880 / μ l	HPT:52%
Alb:3.4g/dl	RBC:450 \times 103 / μ l	PT%:71%
T-Bil:2.0mg/dl	Hgb:14.5 g/dl	
AST:41IU/l	Hct:43.4 %	
ALT:32 IU/l	MCV:32fl	
ALP:350IU/l	Plt:46000 / μ l	BTR 1.73
γ -GTP:19 IU/l		transthyretin 6.7mg/dl
LDH:240 IU/l	(Virus Marker)	Retinalbinding protein0.5mg/dl
Na:142 mEq/l	HBs Ab negative	Free fatty acid 1137uEq/L
K:4.8mEq/l	HCV Ag negative	Total carnitine 96.7 μ mol/l
Cl:105 mEq/l		Free-carnitine 71.8 μ mol/l
BUN:8 mg/dl		Acyl-carnitine 24.9 μ mol/l
Cre:0.75mg/dl		

every day. Furthermore, no symptoms, such as abdominal distention, caused by this product were observed.

Administration of this product resulted in resolution of the starvation (the free fatty acid level decreased from 1137 $\mu\text{Eq/L}$ before the start of this product to 510 $\mu\text{Eq/L}$ in the first week and 209 $\mu\text{Eq/L}$ in the second week of administration). The BTR improved from 1.73 to 1.91 in the first week and 2.11 in the second week. The serum Alb, which was 3.7 g/dL before the start of administration of the product, remained unchanged at 3.7 g/dL in the first week and decreased slightly to 3.5 g/dL in the second week. The serum Pre-Alb increased from 6.7 mg/dL before the start of administration of this product to 7.2 mg/dL in the first week and 6.8 mg/dL in the second week, showing little change. The serum RBP level was 0.5 mg/dL before the start of administration of the product, 0.6 mg/dL in the first week and 0.5 mg/dL in the second week, showing no significant change (Figure 1).

The body weights before the start of administration of the product and in the first and second week of administration were 88.2 kg, 89 kg, and 89.7 kg, respectively, showing little change. The skeletal muscle mass and total body fat mass at the three time-points were 32.6 kg, 33.2 kg and 33.9 kg, and 30.2 kg, 30.30 kg and 29 kg, respectively. A slight decrease was observed in the total body fat.

Discussion

In patients with liver cirrhosis, various metabolic abnormalities, including protein-energy malnutrition (PEM), are observed [1]. PEM is observed in 50% of patients with liver cirrhosis, protein malnutrition in 25%, and energy malnutrition in 12%. Those showing normal protein-energy nutrition account for only 13%. The efficiency of intracellular energy metabolism in each organ is markedly reduced. In regard to the energy substrates utilized, the rate of utilization of endogenous fat is higher than that of carbohydrate. This pattern of nutrient metabolism is similar to that noted after long-term fasting and starvation in healthy adults. As the severity of liver cirrhosis progresses, this trend becomes increasingly more pronounced and affects the prognosis [2].

Owen et al. reported that in patients with liver cirrhosis, even a single overnight fast leads to a decrease in the supply of glucose from the liver at an early stage, which consequently decreases the amount of glucose available to the tissues. The result is a condition equivalent to the state observed in healthy people after two to three days of fasting [3]. In patients with liver cirrhosis, fasting for approximately only 10–12 hours leads to a decrease in the supply of glucose from the liver, leading to the starvation-like state. In the daily life of these patients, the period from supper to the early morning corresponds to this condition. In recent years, administration of an LES before bedtime has been attempted as a method to prevent such a state of starvation [4]. The requirements for the ideal LES include a light meal (i) containing approximately 200 kcal, (ii) containing carbohydrate (glucose), fat, and protein in proper balance, (iii) containing BCAA, that is (iv) easy to digest, and (v) easy to prepare. Although rice balls, bread, and other types of light meals can be substituted for LES, these foods lack BCAA. It is considered to be desirable to use BCAA as a supplement in the LES [5]. Products that meet these requirements include some commonly available enteral nutrients for hepatic failure

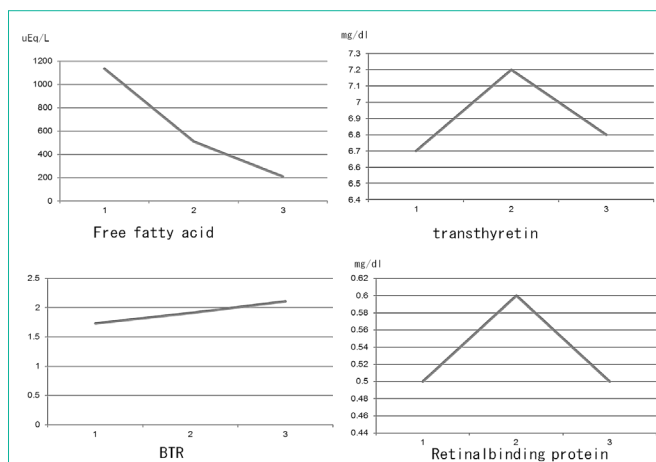


Figure 1: Transition of the laboratory findings after treatment.

The serum Alb, which was 3.7 g/dL before the start of administration of the product, remained unchanged at 3.7 g/dL in the first week and decreased slightly to 3.5 g/dL in the second week. The serum Pre-Alb increased from 6.7 mg/dL before the start of administration of this product to 7.2 mg/dL in the first week and 6.8 mg/dL in the second week, showing little change. The serum RBP level was 0.5 mg/dL before the start of administration of the product, 0.6 mg/dL in the first week and 0.5 mg/dL in the second week, showing no significant change.

(Aminoleban EN, 210 kcal/pack; Hepan ED, 310 kcal/pack). We have also reported on the usefulness of Aminoleban EN as an LES in the clinical pathway for radiofrequency ablation [6]. The introduction of LES on admission allowed us to check whether the patients could consume it, whether it caused any adverse reactions, etc. Furthermore, the compliance of patients could also be confirmed by allied healthcare professionals, including nurses, ward pharmacists, and dietitians. It has been reported that when an LES is administered to outpatients without nutrition education provided by national registered dietitians, the ammonia levels and BTR improved in patients with a 120-minute blood sugar level of 200 mg/dL or less in a 75-g oral glucose tolerance test, whereas the glucose tolerance worsened in diabetic patients with a 120-minute blood sugar value of 200 mg/dL or more [7]. These findings, which are consistent with our previous report, may be attributable to increased total daily energy intake, leading to recognition of the importance of dietary intervention. In the present study, a national registered dietitian controlled the state of food intake and provided nutrition education. Moreover, a previous study that compared the long-term effects of Aminoleban EN (BCAA group) and a carbohydrate-based ordinary diet (snack group) as an LES reported improvement in the non-protein respiratory quotient (npRQ), serum Alb levels, nitrogen balance, and BTR in the BCAA group, but no improvement of the nitrogen balance or npRQ in the snack group [5]. While many reports on LES mention the use of Aminoleban EN as described above, we examined the usefulness of the BCAA- and carnitine-enriched enteral nutrient ENEVO in a patient who experienced abdominal distention after ingestion of Aminoleban EN and refused to continue taking that product. ENEVO contains 300 kcal (250 mL), and a better improvement in the BTR might have been noted because it contains 50 kcal more than the recommended calories for an LEA of 200 kcal [8]. Moreover, the serum free fatty acid levels also improved. One of the possible reasons for these effects is that ENEVO contains dietary fiber, which slows the absorption of glucose and contributes to shortening of the duration of an energy-

depleted state. While an LES containing approximately 200 kcal is recommended at present, we propose to study the effect of ENEVO as an LES through accumulation of cases in the future.

Because patients with liver cirrhosis have various subjective symptoms, establishment of adequate methods to assess the quality of life (QOL) may be necessary for understanding the disease state of liver cirrhosis, determining therapeutic efficacy, etc. While no such method exists in Japan, there are a few reports of assessment of the QOL of patients with liver cirrhosis from Europe and the United States [9].

On the third day after administration of ENEVO, our patient reported relief from muscle cramps, which could be attributable to the replenishment of carnitine. In our study, although no significant difference in the serum carnitine levels was observed among patients with different Child-Pugh grades, the levels increased slightly despite the small carnitine dose of 20 mg in ENEVO. Thus, we also propose to investigate the significance of carnitine administration through accumulation of more cases in the future. Moreover, the use of In body allowed us to track the changes in the weight, total body fat, and skeletal muscle mass of the patients over time, and no significant changes in any of these parameters were observed as a result of the strict dietary intervention by the national registered dietitian. These findings underscore team medical care in the treatment of liver diseases.

Conclusion

We encountered a case in which administration of a BCAA- and carnitine-enriched enteral nutrient as an LES resulted in improvement of the nutritional status of the patient with hepatic failure.

References

1. Morgan AG, Kelleher J, Walker BE, Losowsky MS. Nutrition in cryptogenic cirrhosis and chronic aggressive hepatitis. See comment in PubMed Commons below Gut. 1976; 17: 113-118.
2. Tajika M, Kato M, Mohri H, Miwa Y, Kato T, Ohnishi H, et al. Prognostic value of energy metabolism in patients with viral liver cirrhosis. See comment in PubMed Commons below Nutrition. 2002; 18: 229-234.
3. Owen OE, Trapp VE, Reichard GA Jr, Mozzoli MA, Moctezuma J, Paul P, et al. Nature and quantity of fuels consumed in patients with alcoholic cirrhosis. See comment in PubMed Commons below J Clin Invest. 1983; 72: 1821-1832.
4. Nakaya Y, Okita K, Suzuki K, Moriwaki H, Kato A, Miwa Y, et al. BCAA-enriched snack improves nutritional state of cirrhosis. See comment in PubMed Commons below Nutrition. 2007; 23: 113-120.
5. Naoki Hotta. The clinical path of the radiofrequency ablation which incorporated the nutrition treatment. *Frontiers in Gastroenterology*. 2008; 13: 78-83.
6. Aoyama K, Tsuchiya M, Mori K, Kubo Y, Shiraishi K, Sakaguchi E, et al. Effect of a late evening snack on outpatients with liver cirrhosis. See comment in PubMed Commons below Hepatol Res. 2007; 37: 608-614.
7. Nakaya Y, Tsutsumi R, Harada N et al. Late evening snack JSPEN. 2010; 25: 15-20.
8. Fukuhara S, Suzukamo Y, Mito S, Kurokawa K. Manual of SF-36 Japanese version 1.2: Public Health Research Foundation, Tokyo. 2001.
9. Naoki Hotta. Carnitine deficiency and improvement of muscle cramp by administration of carnitine in patients with liver cirrhosis: *Open journal of gastroenterology* 2014; 4: 242-248.