

Case Report

Successful Treatment of Immune Thrombocytopenia as an Extrahepatic Manifestation in an HCV-Carrier Woman with Normal Liver Function Test Results

Okazaki I^{1,2,3*}, Ichiishi E², Miyakawa Y⁴ and Sohara Y^{3,5}

¹Department of Internal Medicine, Sanno Hospital, International University of Health and Welfare (IUHW), Japan

²Departments of Internal Medicine and

³Preventive Medical Center, IUHW Hospital, Japan

⁴Department of General Internal Medicine, Saitama Medical University, Japan

⁵Department of Chest Surgery, IUHW Hospital, Japan

***Corresponding author:** Okazaki I, Internal Medicine, Sanno Hospital, International University of Health and Welfare, 8-10-16 Akasaka, Minato-ku, Tokyo 107-0052, Japan, Tel: 81334023151; Fax: 81334043652; Email: iokazaki@iuhw.ac.jp

Received: August 05, 2014; **Accepted:** August 13, 2014;

Published: August 13, 2014

Abstract

The authors report a case of immune thrombocytopenia (ITP) as an extrahepatic manifestation in a hepatitis C virus (HCV)-carrier woman with normal liver function tests. The 46-year-old woman visited the Preventive Medical Center of International University of Health and Welfare (IUHW) Hospital in February 2011. She had no complaints and a conventional health check was conducted. The physical and laboratory examinations showed results within normal range except for iron-deficiency anemia and positive for HCV antibody (third generation). HCV-RNA (PCR) was 4.20 Log IU/ml, HCV genotype II and HCV core antibody 484.7. These findings suggested chronic infection with HCV, but there seemed to be no involvement of liver disease. Three months later, at the second visit, she showed thrombocytopenia. We believed the thrombocytopenia to be caused by chronic HCV infection and started anti-HCV viral therapy: interferon α 2A (90 μ g) injection weekly and ribavirin (600mg/day). Five months later the treatment was discontinued due to neutropenia even though GCSF injections were frequently administered. After treatment for two months, levels of HCV PCR copies were not detected, and the platelet count recovered to normal after six months. Since then three years have passed, HCV-PCR copies have shown non-detectable levels and the platelet count remains normal. There are numerous papers reporting that HCV causes ITP as an extrahepatic manifestation, but a case report of ITP caused by chronic HCV infection without liver disease has not been found. The present case report discusses the specificity of HCV infection on extrahepatic manifestation, and the treatment of ITP caused by chronic HCV infection

Keywords: Hepatitis c Virus; Extrahepatic Manifestations; Immune Thrombocytopenia; Interferon; Ribavirin

Abbreviations

GCSF: granulocyte-colony stimulating factor; HAV: hepatitis A virus; HBV: hepatitis B virus; HCV: hepatitis C virus; IFN: interferon; IFN α 2a: interferon α 2a; ITP: immune thrombocytopenia; PAIgG: Platelet-associated immunoglobulin G

Introduction

The authors examined a middle-aged HCV-carrier woman with no abnormal liver function test results who showed a decreased platelet count. Anti-viral therapy was used. Interferon (IFN) and ribavirin to render HCV-PCR copies negative and subsequently to recover the platelet count. This case was assumed to be secondary immune thrombocytopenia (ITP) as an extrahepatic manifestation of chronic HCV infection because the platelet-associated immunoglobulin G (PAIgG) was positive.

Worldwide, 145 million individuals have been estimated to be infected with HCV, equivalent to 2.2% of the world's population [1]. The prevalence of ITP among patients infected with HCV has been reported to be 10% to 36 % (total of 159 ITP/799 HCV patients; 20%) [2]. Moreover, the review [2] noted as follows: thrombocytopenia may be present even in the absence of clinically evident liver disease or

splenomegaly and may be mistakenly diagnosed as primary ITP [3-5]. Although the latter part of this statement is correct and important for hematologists, the former part requires clarification. Although one literature was found (not available and not yet examined in detail) [6], any case without clinically evident liver disease was described in the cited papers [3,4]. The detailed information in these papers [3,4] showed the presence of chronic hepatitis C or HCV-related cirrhosis with or without splenomegaly. Another paper [5] reported immunological alterations in HCV-positive patients with lymph proliferative and connective tissue disorders. Therefore, the present authors decided to report this case to contribute to the body of information for hepatologists and hematologists as well as to assist in the treatment of ITP as an extrahepatic manifestation in chronic HCV infection.

ITP is usually a complication in chronic hepatitis C to HCV-infected cirrhosis patients [6], 20% as noted above. The present case showed no clinically evident liver disease, the size of the spleen was normal, and abdominal ultrasonography showed no abnormal findings in the liver. The precise clinical course of this case is presented here and the possible pathogenesis of ITP in this case is discussed. Moreover, the extrahepatic manifestations of hepatitis A

virus (HAV), hepatitis B virus (HBV) and HCV are compared with those in the literature, and the treatment of ITP caused by chronic HCV infection is discussed.

Case Presentation

A 46-year-old woman visited the Preventive Medical Center of International University of Health and Welfare (IUHW) Hospital in February 2011 for a health check. She had no complaints, but physical examination revealed anemia without purpura. Laboratory findings showed positive for HCV antibody (third generation) besides low hemoglobin content (9.0 g/dl) and low iron content (0.322 μ mol/l), as shown in Table 1. Other physical and clinical data (BMI 20.3, blood pressure 106/60, urinalysis, stool blood, blood chemical examination including liver function tests, lipid analysis, etc., gastro-fluorography, and abdominal ultrasonography) were normal. There was nothing out of the ordinary in her own or her family history. She did not smoke or consume alcohol.

She had visited the Preventive Medical Center twice previously, in October 2008 and February 2010. As shown in Table 1, iron-deficiency anemia was seen in the past two visits, but she had not been treated. She visited the Hepatology Clinic of IUHW Hospital for treatment of anemia and detailed examination for HCV infection in March 2011. The findings were as follows: HCV-RNA (PCR) 4.20 Log

Table 1: Laboratory data of a 46-year-old HCV-carrier woman. Before treatment (1. 2008/Oct, 2. 2010/Oct, 3. 2011/Feb), During treatment (4. 2011/Jan, 5. 2011/Sep) and After treatment (6. 2012/May, 7. 2012/Apr).

	1	2	3	4	5	6	7
W.B.C.($10^9/l$)	5.56	2.80	2.35	3.90	3.34	4.00	4.50
R.B.C.($10^{12}/l$)	4.50	4.63	4.67	4.41	4.26	4.22	4.89
Hb(g/dl)	9.9	9.5	9.0	12.9	13.1	12.4	14.7
Plat.($10^9/l$)	211	187	185	110	113	201	163
var.sizeeryth.		+	+		+		
var.sizeplat.			+				
large plat.			+				
Iron(μ mol/l)	0.376	0.448	0.322	0.644	1.11	0.591	1.27
HBsAg	neg.	neg.	neg.			neg.	neg.
HCVab(3 rd)	pos.	pos.	pos.			pos.	pos.
HCV-RNA(LogIU/ml)			4.20		neg.	neg.	neg.
HCV-coreab			484.7		443.6		
PAIgG (less than 46ng/10 cells)						66	
HelicobacterPyroliab.				neg.		neg.	neg.
Tot.prot.(g/dl)	7.4	7.4	8.1		7.4	7.6	7.4
Alb.(g/dl)	4.1	4.2	4.2		3.9	4.3	4.4
Tot.bil.(mg/dl)	0.6	0.9	0.9	0.8	0.8	1.0	1.2
AST(IU/*)	22	20	23	24	16	16	20
ALT(IU/l)	19	15	19	22	12	10	11
γ -GT(IU/l)	26	18	26	36	25	15	16
LDH(IU/l)	178	166	182	171	174	185	206

Abbreviations: W. B. C: White Blood Cells; R.B.C: Red Blood Cells; Hb: Hemoglobin; Plat: Platelets; var. size eryth: varying size of erythrocytes; var. size plat: varying size of platelets; large plat: large platelets; HBsAg: Hepatitis B Virus Surface Antigen; HCVab: Hepatitis C Virus Antibody; HCV-RNA: Hepatitis C Virus Quantification By PCR Method; HCV-core ab: Hepatitis C Virus-Core Antibody; PAIgG: Platelet-Associated Immunoglobulin G; HelicobacterPyroli ab: Helicobacter Pyroli antibody; Tot. prot: Total Protein; Alb: Albumin; Tot.bil: Total Bilirubin; AST: Aspartate Amino Transferase; ALT: Alanine Amino Transferase; γ -GT: γ -Glutamyl Transpeptidase; LDH: Lactate Dehydrogenase; *IU/l: International Unit/L

IU/ml; HCV genotype II; HCV core antibody 484.7. These suggest chronic HCV infection, but there appeared to be no involvement of liver disease (Table 1).

Four months later, in the beginning of June, peripheral blood examination showed gradually decreasing platelet counts (Table 1). She had no signs or symptoms of any infection including common cold, and showed no purpura or skin rash. Her medication consisted only of iron for anemia prescribed at the previous consultation. She had not taken any drugs or supplements. Her physical and laboratory data were almost normal except for anemia and thrombocytopenia. Her abdominal ultrasonography showed normal size of spleen and no abnormal findings in the liver. The authors discussed the pathogenesis of thrombocytopenia and concluded that chronic HCV infection may cause ITP as an extrahepatic manifestation although liver function tests suggested normal liver. *Helicobacter pylori* antibody was negative. Anti-viral treatment for HCV was started because the platelet count rapidly decreased from $185 \times 10^9/l$ (February 2011) to $110 \times 10^9/l$ (June 2011).

Subdermal injection of interferon $\alpha 2a$ (IFN $\alpha 2a$) (180 or 90 μ g/week) and per oral ribavirin (600 mg/day) was administered. As shown in Figure 1, granulocytes decreased so Granulocyte-Colony Stimulating Factor (G-CSF) (75 μ g) was frequently injected subcutaneously. Although treatment with IFN and ribavirin was not sufficient, HCV-RNA (PCR) was not detected two months later and continued to be negative for four months, at which time IFN $\alpha 2a$ and ribavirin were discontinued. HCV core antibody gradually decreased from 484.7 to 400.9, but still remained high. Although treatment should have been continued for six more months, continuation was not possible because the number of granulocytes fell to less than $0.90 \times 10^9/l$ if G-CSF was not used. Administration of IFN $\alpha 2a$ was stopped with the 11th injection, as shown in Figure 1. One month after discontinuation of IFN $\alpha 2a$ and ribavirin, the platelet count recovered to $147 \times 10^9/l$. From that time until May 11, 2014, HCV-RNA (PCR) has continued to show negative, and the platelet count recovered to $163 \sim 201 \times 10^9/l$ (Table 1).

The treatment with IFN $\alpha 2a$ and ribavirin was effective for thrombocytopenia consistent with negative HCV-PCR. Antibodies against platelet surface antigen could not be examined before and during treatment. They were examined several times after treatment and showed negative. Very recently, platelet-associated immunoglobulin G (PAIgG) was found to be slightly high, as shown in Table 1. This was the first test after treatment. As a result, the authors diagnosed ITP to be an extrahepatic manifestation of chronic HCV infection with normal liver function test results.

Discussion

This case was diagnosed to be ITP as an extrahepatic manifestation by chronic HCV infection. ITP is defined as an acquired disorder in which there is immune-mediated destruction of platelets and possible inhibition of platelet release from megakaryocytes [6]. Serological evidence of platelet autoantibodies is not found easily [7,8]. In general ITP is a complication in chronic hepatitis C, found in 20% of patients with chronic HCV hepatitis, as noted above [2,8]. If patients with chronic hepatitis C or HCV-related cirrhosis show extensive fibrosis and thrombocytopenia, the pathophysiology of thrombocytopenia

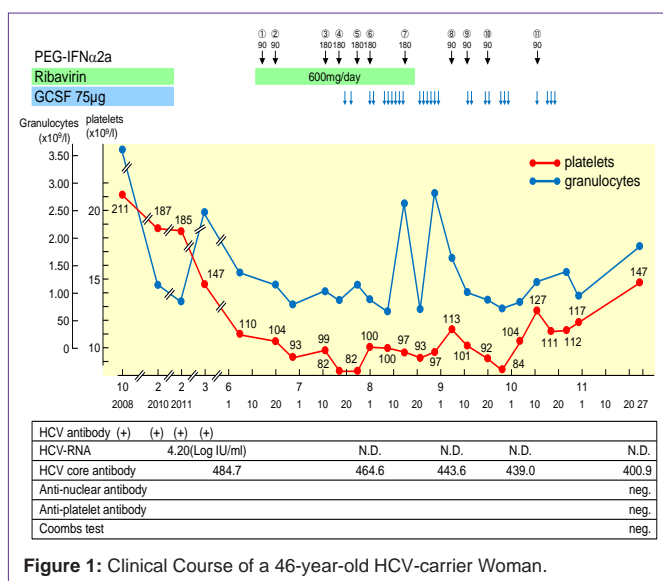


Figure 1: Clinical Course of a 46-year-old HCV-carrier Woman.

may be hypersplenism due to portal hypertension, bone marrow suppression resulting from either HCV itself or IFN treatment, immune dysfunction or anti-viral therapy [2,7-9]. Thrombocytopenia is caused by bacterial and viral infection as well as by drugs [7,10,11]. The following viral infections have been reported: varicella, Epstein-Barr virus, human immunodeficiency virus, parvovirus and HCV [7]. In the present case, no history of infectious disease or drugs was found, and conventional liver function tests showed normal values over a 7-year clinical course, as shown in Table 1. If this case had any liver disease, the ALT levels would have shown some change after IFN α 2a and ribavirin treatment because the biological stress of these treatments affect liver function tests. The reason why this case had not manifested chronic hepatitis C must be considered. The patient had shown iron-deficiency anemia over a long period of time. However, a state of continued iron deficiency probably does not cause hepatitis [12].

As for the cause of ITP in this case, chronic HCV infection is strongly suggested because IFN and ribavirin therapy led to negative HCV-RNA, followed by recovery of the platelet count to normal range. In addition to successful treatment PAIgG was detected and measured quantitatively with a result of 66 ng/10⁷ cells (normal range: less than 46) in April 2014. Therefore, the authors at present believe that ITP in this case may be due to some kind of immunological alteration [13,14].

Pascal et al [15] first described an association between HCV and extrahepatic manifestation in 1990, reporting two patients with mixed cryoglobulinemia. It has been reported that 40% to 74% of patients with HCV infection developed at least one extrahepatic manifestation during the clinical course [16-20]. HCV infection causes extrahepatic manifestations. One case with rheumatoid arthritis was caused by chronic HCV infection without any liver disease confirmed by liver biopsy [21]. Sometimes, extrahepatic syndrome represents the first sign of an HCV infection [2-5]. As noted above, however, no report on ITP as extrahepatic manifestation in chronic HCV infection without chronic hepatitis could be found in a search of Pub Med using the keywords HCV infection and ITP, and HCV infection and extrahepatic manifestation.

There are numerous papers on extrahepatic manifestations in HCV infection while very few papers exist regarding extrahepatic manifestations in hepatitis A virus (HAV) infection and hepatitis B virus (HBV) infection. Concerning HAV infection, 4 papers reporting a total of 4 cases were found [22-25]. Two cases were autoimmune thrombocytopenia [22,23]. As for HBV infection, 7 papers reported membranoproliferative glomerulonephritis, nodular polyarteritis, myositis, otological sensory disease, and Sjogrene syndrome as extrahepatic manifestations of chronic hepatitis B [26-32]. Four papers were clinical research originals [27-29,32] and three were reviews [26,30, 31]. The authors did not find any case reports because patients with chronic hepatitis B and extrahepatic manifestations are more numerous than patients with acute hepatitis A infection and extrahepatic manifestations, but absolutely less than the number of patients with chronic hepatitis C and extrahepatic manifestations. From the viewpoint of virus tropism to organ, HCV is different from HAV and HBV. Most extrahepatic manifestations seen in patients with chronic HCV infection has revealed autoimmune diseases. Even if the extrahepatic manifestations in HAV and HBV infections are also autoimmune diseases, the number of patients with HCV infection showing extrahepatic manifestations is much greater. Pivetti et al. [5] reported that autoimmune abnormalities were significantly more frequent in anti-HCV-positive than in anti-HCV-negative patients, and in anti-HCV-positive as compared to anti-HBc-positive subjects among patients with lymph proliferative disorders. Forty-five to 65% of HCV-infected patients have various autoantibodies [33]. Galossi et al. [19] wrote that an important feature of HCV is to avoid immune elimination. The present authors propose that the name HCV be changed to "immunomodulating virus."

The present case showed successful treatment of IFN α 2a and ribavirin on ITP in chronic HCV infection without any liver disease. Corticosteroids or intravenous immunoglobulin was not used as the first line therapy in this case, because this case was secondary ITP followed by chronic HCV infection and no complication of chronic hepatitis may progress to severe state. Although neutropenia was seen during treatment and injections of GCSF were required, as shown in Figure 1, the treatment with IFN α 2a and ribavirin appears to be reasonable and effective to eliminate HCV. Since the lowest platelet count in this case was 82 x10⁹/l, the treatment was effective.

As HCV-related ITP had a higher prevalence of cirrhosis and demonstrated more immunological markers than controls, Dufour et al. [34] proposed from the results of their patients' treatment that severe ITP patients with chronic HCV infection require a different strategy as follows: first line therapy of corticosteroids or intravenous immunoglobulin injection, and the second line therapy of splenectomy and antiviral therapy. If the second line therapy fails, rituximab or thrombopoietic growth factor is recommended [34]. Other authors also reported very similar strategies [3,8,10,11]. In general, at the present time, if the symptom of purpura is seen (the platelet count may be under 20x10⁹/l), new thrombopoietic agents such as eltrombopag and romiplostim have been reported to be effective for ITP as extrahepatic manifestation in chronic hepatitis C [35,36].

Conclusion

The authors report here a case of ITP as extrahepatic manifestation

in chronic HCV infection without hepatitis. HCV is very different from HAV and HBV in the organ tropism, and we suggest changing the name from HCV to “immunomodulating virus”. Patient management in the follow-up of HCV carriers should be undertaken from the viewpoint of extrahepatic manifestation.

Conflict of Interest

The authors confirm that there are no conflicts of interest regarding the contents of this article.

Acknowledgment

The authors thank Ms. Yoshie Muroya for her systematic research of the literature and Ms. Cecilia Hamagami for assistance in the English revision of the manuscript.

References

- Global surveillance and control of hepatitis C. Report of a WHO Consultation organized in collaboration with the Viral Hepatitis Prevention Board, Antwerp, Belgium. *J Viral Hepat*. 1999; 6: 35-47.
- Liebman HA. Viral-associated immune thrombocytopenic purpura. *Hematology Am Soc Hematol Educ Program*. 2008.
- Garcia-Suarez J, Burgaleta C, Hernanz N, Albarran F, Toarueta P, Alvarez-Mon M. HCV-associated thrombocytopenia: clinical characteristics and platelet response after recombinant alpha2b-interferon therapy. *Br J Haematol*. 2000; 110: 98-103.
- Rajan SK, Espina BM, Liebman HA. Hepatitis C virus-related thrombocytopenia: clinical and laboratory characteristics compared with chronic immune thrombocytopenic purpura. *Br J Haematol*. 2005; 129: 818-824.
- Pivetti S, Novarino A, Merico F, Bertero MT, Brunetto MR, Bonino F, et al. High prevalence of autoimmune phenomena in hepatitis C virus antibody positive patients with lymphoproliferative and connective tissue disorders. *Br J Haematol*. 1996; 95: 204-211.
- Beyan C, Cetin T, Kaptan K, Nevruz O, Ural AU, Avcu F, et al. Severe thrombocytopenia as a presenting symptom of hepatitis C virus infection. *Haematologia (Budap)*. 2002; 32: 277-280.
- Konke B. Disorders of platelets and vessel wall. Longo DI, Fauci AS, Kasper DL, Hauser SL, Jameson JL, Loscalzo J, editors. In: *Harrison's Principles of Internal Medicine*, 18th edition. Mc Graw Hill Medical. 2012; 1: 965-973.
- Stasi R, Chia LW, Kalkur P, Lowe R, Shannon MS. Pathobiology and treatment of hepatitis virus-related thrombocytopenia. *Mediterr J Hematol Infect Dis*. 2009.
- Weksler BB. Review article: the pathophysiology of thrombocytopenia in hepatitis C virus infection and chronic liver disease. *Aliment Pharmacol Ther*. 2007; 26: 13-19.
- Giannini EG. Review article: thrombocytopenia in chronic liver disease and pharmacologic treatment options. *Aliment Pharmacol Ther*. 2006; 23: 1055-1065.
- Stasi R. Therapeutic strategies for hepatitis- and other infection-related immune thrombocytopenias. *Semin Hematol*. 2009; 46: 15-25.
- Sartori M, Andorno S, Rossini A, Boldorini R, Bozzola C, Carmagnola S, et al. A case-control histological study on the effects of phlebotomy in patients with chronic hepatitis C. *Eur J Gastroenterol Hepatol*. 2011; 23: 1178-1184.
- Nakajima H, Takagi H, Yamazaki Y, Toyoda M, Takezawa J, Nagamine T, et al. Immune thrombocytopenic purpura in patients with hepatitis C virus infection. *Hepatogastroenterology*. 2005; 52: 1197-1200.
- Aref S, Sleem T, Menshawy N E, Ebrahiem L, Abdella D, Fouda M, et al. Antiplatelet antibodies contribute to thrombocytopenia associated with chronic hepatitis C virus infection. *Hematology*. 2009; 14: 277-281.
- Pascual M, Perrin L, Giostra E, Schifferli JA. Hepatitis C virus in patients with cryoglobulinemia type II. *J Infect Dis*. 1990; 162: 569-570.
- Cacoub P, Poynard T, Ghillani P, Charlotte F, Olivi M, Piette JC, et al. extrahepatic manifestations of chronic hepatitis C. MULTIVIRC Group. Multidepartment Virus C. *Arthritis Rheum*. 1999; 42: 2204-2212.
- Cacoub P, Renou C, Rosenthal E, Cohen P, Loury I, Loustaud-Ratti V, et al. extrahepatic manifestations associated with hepatitis C virus infection. A prospective multicenter study of 321 patients. The GERMIVIC. Groupe d'Etude et de Recherche en Medecine Interne et Maladies Infectieuses sur le Virus de l'Hepatitis C. *Medicine (Baltimore)*. 2000; 79: 47-56.
- Ali A, Zein NN. Hepatitis C infection: a systemic disease with extrahepatic manifestations. *Cleve Clin J Med*. 2005; 72: 1005-1008.
- Galossi A, Guarisco R, Bellis L, Puoti C. extrahepatic manifestations of chronic HCV infection. *J Gastrointestin Liver Dis*. 2007; 16: 65-73.
- Jacobson IM, Cacoub P, Dal Maso L, Harrison SA, Younossi ZM. Manifestations of chronic hepatitis C virus infection beyond the liver. *Clin Gastroenterol Hepatol*. 2010; 8: 1017-1029.
- Akhtar AJ, Funnyé AS. Hepatitis C virus associated arthritis in absence of clinical, biochemical and histological evidence of liver disease-responding to interferon therapy. *Med Sci Monit*. 2005; 11: CS37-39.
- Scott JX, Gnananayagam EJ, Gupta S, Simon A, Mukhopadhyaya A. Thrombocytopenic purpura as initial presentation of acute hepatitis A. *Indian J Gastroenterol*. 2003; 22: 192-193.
- Tanir G, Aydemir C, Tuygun N, Kaya O, Yarali N. Immune thrombocytopenic purpura as sole manifestation in a case of acute hepatitis A. *Turk J Gastroenterol*. 2005; 16: 217-219.
- Yoon YK, Park DW, Sohn JW, Kim MJ, Kim I, Nam MH. Corticosteroid treatment of pure red cell aplasia in a patient with hepatitis A. *Acta Haematol*. 2012; 128: 60-63.
- Zis P, Kontogeorgi E, Karakalos D, Pavlopoulou D, Sevastianos VA. Cerebral venous thrombosis as an extrahepatic manifestation of acute anicteric hepatitis a infection. *Case Rep Neurol Med*. 2012; 120423.
- Trepo C, Guillevin L. Polyarteritis nodosa and extrahepatic manifestations of HBV infection: the case against autoimmune intervention in pathogenesis. *J Autoimmun*. 2001; 16: 269-274.
- Elefsiniotis IS, Diamantis ID, Dourakis SP, Kafiri G, Pantazis K, Mavrogiannis C. Anticardiolipin antibodies in chronic hepatitis B and chronic hepatitis D infection, and hepatitis B-related hepatocellular carcinoma. Relationship with portal vein thrombosis. *Eur J Gastroenterol Hepatol*. 2003; 15: 721-726.
- Cacoub P, Saadoun D, Bourlière M, Khiri H, Martineau A, Benhamou Y, et al. Hepatitis B virus genotypes and extrahepatic manifestations. *J Hepatol*. 2005; 43: 764-770.
- Gan SI, Devlin SM, Scott-Douglas NW, Burak KW. Lamivudine for the treatment of membranous glomerulopathy secondary to chronic Hepatitis B infection. *Can J Gastroenterol*. 2005; 19: 625-629.
- Baig S, Alamgir M. The extrahepatic manifestations of hepatitis B virus. *J Coll Physicians Surg Pak*. 2008; 18: 451-457.
- Chan TM. Hepatitis B and Renal Disease. *Curr Hepat Rep*. 2010; 9: 99-105.
- Kong D, Wu D, Wang T, Li T, Xu S, Chen F, et al. Detection of viral antigens in renal tissue of glomerulonephritis patients without serological evidence of hepatitis B virus and hepatitis C virus infection. *Int J Infect Dis*. 2013; 17: e535-538.
- Bockle BC, Baltaci M, Ratzinger G, Graziadei I, Vogel W, Sepp NT. Hepatitis C and autoimmunity: a therapeutic challenge. *J Intern Med*. 2011.
- Dufour JF, Pradat P, Ruivard M, Hot A, Dumontet C, Broussolle C, et al. Severe autoimmune cytopenias in treatment-naïve hepatitis C virus infection: clinical description of 16 cases. *Eur J Gastroenterol Hepatol*. 2009; 21: 245-253.
- Panzer S. Eitrombopag in chronic idiopathic thrombocytopenic purpura and HCV-related thrombocytopenia. *Drugs Today (Barc)*. 2009; 45: 93-99.
- Buccoliero G, Urbano T, Massa P, Resta F, Pisconti S. Romiplostim for severe thrombocytopenia in the treatment of chronic hepatitis C virus infection: a new option for clinicians? *New Microbiol*. 2014; 37: 97-101.