

## Research Article

# Efficacy and Side Effects in HER2-Positive Advanced Breast Cancer Patients Treated with Pyrotinib: A Real-World Study in China

Xiaolei Wang<sup>1</sup>, Chen Xu Meng<sup>2</sup>, Jingjing Li<sup>1</sup>, Yu Su<sup>3</sup>, Fanfan Li<sup>1\*</sup> and Jun Yang Zhao<sup>3\*</sup>

<sup>1</sup>Department of Oncology, The Second Affiliated Hospital of Anhui Medical University, China

<sup>2</sup>Department of Ophthalmology, Anhui Provincial Children's Hospital, China

<sup>3</sup>Department of Pediatric Oncology Center, Beijing Children Hospital, Capital Medical University, China

\*Corresponding author: Fanfan Li, Department of Oncology, The Second Affiliated Hospital of Anhui Medical University, Hefei 230000, Anhui Province, China

Jun Yang Zhao, Department of Pediatric Oncology Center, Beijing Children Hospital, Capital Medical University, National Center for Children's Health, China

Received: June 21, 2021; Accepted: July 13, 2021;

Published: July 20, 2021

## Abstract

**Background:** Pyrotinib is a molecular and irreversible tyrosine kinase inhibitor independently developed in China, and its efficacy against HER2-positive breast cancer in the real world is not clear. In this study, we evaluated the efficacy and safety of pyrotinib in the treatment of HER2-positive advanced breast cancer based on real-world evidence.

**Materials and Methods:** We designed a prospective observational study. Thirty-six patients with HER2-positive advanced breast cancer from a single medical center were included in the study from December 2018 to February 2021. All patients received the oral HER2 receptor inhibitor pyrotinib and received concurrent chemotherapy or endocrinotherapy. The follow-up endpoint is set as April 1, 2021. The primary endpoint is Objective Response Rate (ORR) and Disease Control Rate (DCR), and the secondary endpoint is Progression-Free Survival (PFS) and related side effects.

**Results:** By the end point of follow-up, a total of 17 patients had progressed (including 6 deaths), and the progression-free survival rate was 52.78%. The median PFS was 13 months (PFS range: 3-22 months). As the best response, 4 patients achieved CR, 20 patients achieved PR, 9 patients achieved SD, and 3 patients developed PD. The ORR was 66.67% and DCR was 91.67%. In the analysis, first-line pyrotinib treatment appeared to have higher ORR (88.88% vs 59.26%), but there was no significant difference. In addition, pyrotinib showed significant efficacy in patients with brain metastases, with an ORR of 42.85%. In terms of safety, the incidence of diarrhea was 80.55%, but only 4 patients had grade 3 diarrhea, which was tolerable after the drug dose was reduced; 1 patient had grade 4 neutropenia and grade 3 and thrombocytopenia, which were considered to be related to the chemotherapy drugs. The incidence of other adverse reactions was low, and all were grade 1 to 2.

**Conclusion:** Pyrotinib combined with chemotherapy has a significant effect on HER2-positive breast cancer, and there is still a high ORR in patients who fail multiple lines of treatment. Side effects are overall controllable and safe.

**Keywords:** Breast neoplasms; Pyrotinib; Human epidermal growth factor receptor 2; Objective response rate; Disease control rate; Progression-free survival

## Introduction

Breast cancer is currently one of the most important and common malignant tumor diseases leading to female death worldwide [1], and the incidence is still increasing and showing a tendency to be younger [2]. Human Epidermal Growth Factor Receptor-2 (HER2) positive breast cancer is a pathological type with a very rapid progression of the disease, and its clinical manifestations are aggressive, prone to visceral and central nervous system metastases, and have a poor prognosis [3]. Anti-HER-2 therapy is currently the most important treatment for patients with HER-2 positive breast cancer in clinical practice. The study showed that the 5-year survival rate of HER2-positive breast cancer patients without anti-HER2 therapy was 13.2%; the absolute difference was 11.3% compared with HER2-negative patients [4]. With the clinical application of drugs such as

trastuzumab [5], pertuzumab [6] and lapatinib [7], the situation has been greatly improved, of which trastuzumab is currently the first-line treatment for HER-2 positive advanced breast cancer patients [8,9]. However, anti-HER2 therapy after drug resistance remains a clinical challenge.

At present, the therapeutic drugs targeting HER2 in clinical practice include monoclonal antibodies, tyrosine kinase inhibitors and antibody drug conjugates. The marketed pyrotinib in 2018 is a multi-target tyrosine kinase inhibitor targeting HER1, HER2 and HER4 intracellular kinase regions independently developed in China. The current phase II and III clinical studies [10,11] have encouraging results. In the multicenter randomized controlled study of MA et al. [12], it was shown that pyrotinib combined with capecitabine had a high objective response rate of 78.5% and progression-free survival

of 18.1 months in the treatment of HER2-positive advanced breast cancer. It is not difficult to find by reviewing the clinical study data that: the physical status of patients is relatively good (ECOG score 0~1); about 30% of patients experience only one chemotherapy after recurrence and metastasis, and nearly 50% of patients do not receive chemotherapy after recurrence and metastasis; the combined chemotherapeutic drugs are limited to capecitabine. At present, the treatment data of pyrotinib in the real world are limited. Considering that in clinical practice, no matter the performance status of patients, the times of chemotherapy, or the combination of chemotherapeutic drugs have different degrees of differences from clinical studies, we designed a prospective observational study to clarify the efficacy and safety of pyrotinib in the real world, in order to provide more reference for clinical practice.

## Materials and Methods

### Patients

A total of 36 patients with HER2-positive advanced breast cancer admitted from December 2018 to February 2021 were retrospectively analyzed. General information, pathology and immunohistochemistry, treatment process, imaging data during pyrotinib administration, and side effects were collected from the patients.

### Treatment method

The initial dose of oral pyrotinib was 320 mg (increased to 400 mg/day if well tolerated) or 400 mg. The combination of capecitabine, submit, vincitabine, taxanes, cemorelbine and etoposide was used. For grade 1-2 adverse reactions, corresponding symptomatic treatment should be given without dose adjustment; if grade 3 or higher adverse reactions occur, the dose of pyrotinib or chemotherapeutic drugs should be reduced according to the specific type of adverse reactions.

### Efficacy evaluation

According to Response Evaluation Criteria in Solid Tumors (RECIST) Version 1.1, Complete Response (CR) is the disappearance of all target lesions; Partial Response (PR) is  $\geq 30\%$  decrease in the sum of the long diameters of baseline lesions; Stable Disease (SD) is a decrease in the sum of the long diameters of baseline lesions but without PR or increase but without progressive disease (PD); PD is an increase in the sum of the long diameters of baseline lesions of more than 20%, an increase in the minimum absolute value of 5 mm or the appearance of new lesions. Objective Response Rate (ORR): CR + PR, disease control rate (DCR): CR + PR + SD.

### Assessment of adverse events (AEs)

The National Cancer Institute Common Terminology Criteria for Adverse Events (NCI-CTC 4.0) was used for judgment, and the AEs were classified into grade 1~5.

### Statistical analysis

SPSS 23.0 was used to statistically analyze the data: the enumeration data were expressed as an example (percentage) [n (%)],  $\chi^2$  test or Fisher's exact test was performed, and the test level was  $\alpha = 0.05$ ; there was a significant difference in the evaluation results at  $P < 0.05$ . Kaplan-Meier curves for patients' PFS were plotted using GraphPad 7.0.

**Table 1:** Baseline data of patients.

Item	Number of subjects (n)	Percent (%)
<b>Age</b>		
<50 years	19	52.78
$\geq 50$ years	17	47.22
<b>ECOG score</b>		
$\leq 1$ point	27	75
>1 point	9	25
<b>HR Status</b>		
Positive	16	44.44
Negative	20	55.56
<b>Detection for HER2</b>		
IHC	30	83.33
ISH	6	16.67
<b>Number of lines of pyrotinib used</b>		
First-line	9	25
2 <sup>nd</sup> line	19	52.78
3 <sup>rd</sup> line	8	22.22
<b>Location of Evaluable Lesions</b>		
Viscera	19	52.78
Nonvisceral	10	27.78
Central nervous system	7	19.44
<b>Combination chemotherapy regimen</b>		
Capecitabine	12	33.33
Taxanes	13	36.11
Cemcitabine	5	13.89
Vinorelbine	2	5.56
Others	4	11.11

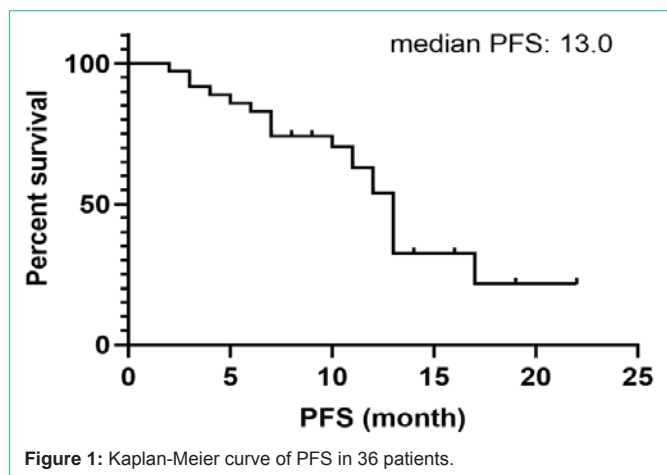
## Results

### Patient baseline data

A total of 35 female patients and 1 male with HER2-positive advanced breast cancer admitted from December 2018 to February 2021 were included, aged 29 to 82 years, the average age was 49 years old. 9 patients had ECOG score greater than 1. 20 patients had negative HR status. 19 patients had internal metastasis, 7 patients had central nervous system metastasis; the number of lines of anti-HER2 therapy with pyrotinib and the specific combination of chemotherapeutic drugs were 9 (Table 1).

### Overall response

As of the follow-up by February 2021, a total of 17 patients had progression (including 6 patients who died); 19 patients were still in medication follow-up, and the progression-free survival rate was 52.78%. The longest progression-free survival was 22 months, and the median progression-free survival was 13 months (Figure 1). As the best response, 4 patients achieved CR, 20 patients achieved PR, 9 patients achieved SD, and 3 patient developed PD. The ORR was 66.67% and DCR was 91.67%. Of the 36 evaluable patients, the onset time was 2 months (range, 0.5 to 3 months) and the optimal response time was 4 months (range, 2 to 7 months).



62.50%) compared with patients with HR+status, but no statistical difference was observed ( $P>0.05$ ).

The ORR of patients with visceral metastasis and non-visceral metastasis was 63.16% and 60.00%, respectively (Table 2). In addition, pyrotinib also had significant effect on patients with brain metastases, with ORR of 42.85%. Three of the seven patients with brain metastases achieved PR, and one of them was observed to have a reduction in the lesion by reexamination of resonance imaging (MRI) more than 40 days after medication, with significant regression of the surrounding edema zone and significant relief of the patient's headache and dizziness symptoms (Photo 1); the other patient also had a significant reduction in the brain lesion by MRI 4 months after medication (Photo 2).

### Analysis of anti-HER2 efficacy

The anti-HER2 efficacy of pyrotinib is shown in Table 2. Among them, the ORR was as high as 88.88% in patients receiving first-line therapy with pyrotinib, and only 59.26% in patients receiving 2 and 3 lines of therapy with pyrotinib, but there was no significant difference in the ORR by the number of lines of therapy ( $P>0.05$ ). The ORR of pyrotinib combined with capecitabine chemotherapy was 75.00%, which was not significantly different from the ORR of pyrotinib combined with taxanes or other chemotherapeutic drugs ( $P>0.05$ ); patients with HR - status seemed to have a higher ORR (85.1% vs

### AEs

Diarrhea was the most common side effect of pyrotinib combined with chemotherapy, with an incidence rate of 80.55%, of which grade 2 and 3 diarrhea were relieved after drug dose reduction, and grade 1 diarrhea was tolerable after dose reduction. One patient also had grade 4 neutropenia and grade 3 thrombocytopenia, which were considered to be related to chemotherapy drugs. Other observable side effects include anemia, vomiting, rash, hand-foot syndrome, and elevated transaminases, which are grade 1 to 2 (Table 3). In addition, no significant changes in ECG were observed before and after treatment in all patients in this group.

Table 2: Analysis of Anti-HER2 Efficacy [n (%)].

Classification	Number of subjects	CR	PR	SD	PD	ORR (%)
<b>Lines Used</b>						
First-line	9	1 (11.1)	7(77.78)	1 (11.11)	0	88.88
≥ 2 lines	27	3 (11.11)	13(48.15)	8(29.63)	3 (11.11)	59.26
P' value		0.393				0.221
<b>Combination chemotherapy drugs</b>						
Capecitabine	12	0	9 (75.00)	3 (25.00)	0	75
Taxanes	13	1 (7.69)	7 (53.85)	4 (30.77)	1 (7.69)	61.54
Other	11	3 (27.27)	4 (36.36)	2 (18.18)	2 (18.18)	63.63
P' value		0.219				0.75
<b>HR Status</b>						
Positive	16	1 (6.25)	8 (50.00)	6 (37.50)	1 (6.25)	56.25
Negative	20	2 (10.00)	13(65.00)	3 (15.00)	2 (10.00)	75
P' value		0.486				0.236
<b>Metastatic site</b>						
Viscera	19	2 (10.53)	10(52.63)	6(31.58)	1(5.26)	63.16
Nonvisceral	10	2 (20.00)	4 (40.00)	3 (30.00)	1 (10.00)	60
Central nervous system	7	0	3 (42.85)	3 (42.85)	1 (14.30)	42.85
P' value		0.864				0.643
<b>Age</b>						
<50	19	3 (15.79)	9 (47.37)	4 (21.05)	3(15.79)	63.16
≥50	17	1 (5.88)	11(64.71)	5 (29.41)	0	70.59
P' value		0.239				0.637

Fisher's exact test was used.

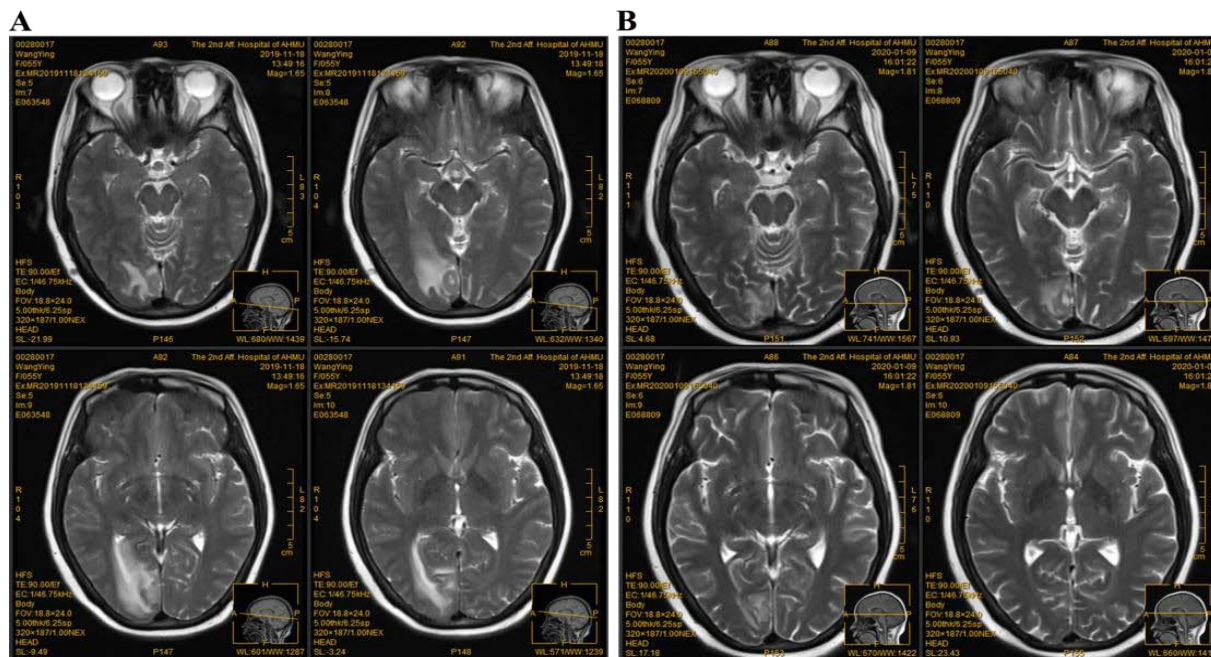


Figure 2: Patient NO. 1 Brain enhanced MRI picture before and after treatment. (A) Before treatment; (B) after more than 40 days of pyrotinib treatment.

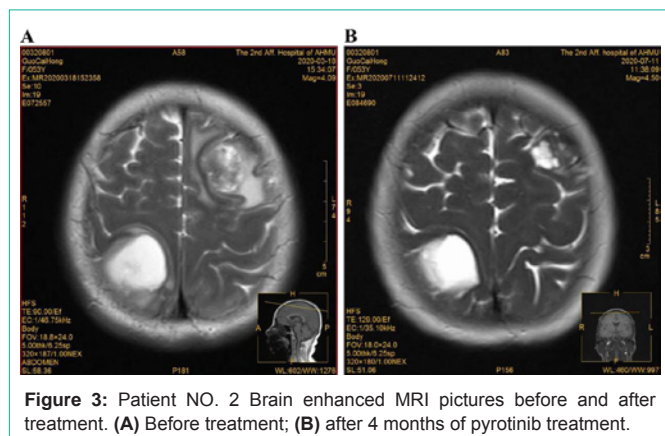


Figure 3: Patient NO. 2 Brain enhanced MRI pictures before and after treatment. (A) Before treatment; (B) after 4 months of pyrotinib treatment.

### Discussion

Pyrotinib is a multi-target tyrosine kinase inhibition independently developed in China, with targets including HER1, HER2 and HER4, which can covalently bind to the ATP binding site of its intracellular kinase region, prevent the formation of homo- or heterodimers, irreversibly inhibit autophosphorylation, block the activation of downstream signaling pathways, and inhibit tumor cell growth [13-15]. Therefore, it is more advantageous than macromolecular monoclonal antibodies acting on extracellular receptors such as trastuzumab and small molecule dual-target tyrosine kinase inhibition acting on intracellular receptors such as lapatinib. Although the phase II clinical study [12] compared the efficacy of pyrotinib combined with capecitabine and lapatinib combined with capecitabine in HER2-positive advanced breast cancer, the objective response rate was 78.5% in the pyrotinib group, but the number of patients enrolled in phase II was only 128, and the patients in clinical trials were strictly screened and needed to be further verified and

Table 3: AEs of pyrotinib combination [n (%)].

AEs	Grading			Total
	Grade 1	Grade 2	≥ Grade 3	
<b>Hematologic AEs</b>				
Anemia	6 (16.67)	3 (8.33)	0	9 (25.00)
Neutropenia	8 (22.22)	3 (8.33)	1 (2.78)	12 (33.33)
Thrombocytopenia	2 (5.56)	0	1 (2.78)	3 (8.33)
<b>Non-hematological AEs</b>				
Diarrhea	18(50.00)	7 (19.44)	4 (11.11)	29 (80.55)
Vomiting	5 (13.89)	1 (2.78)	0	6 (16.67)
Rash	3 (8.33)	0	0	3 (8.33)
Fatigue	6 (16.67)	1 (2.78)	0	7 (19.45)
Hand-foot syndrome	3 (8.33)	1 (2.78)	0	4 (11.11)
<b>Other AEs</b>				
Transaminases increased	2 (5.56)	0	0	2 (5.56)
Hematuria	1 (2.78)	0	0	1 (2.78)

AEs: adverse events.

summarized in the real world after marketing.

This study analyzed the efficacy of 36 doses of pyrotinib combined with chemotherapy in the treatment of HER2-positive advanced breast cancer patients in the real world. The optimal ORR was 66.67%, slightly inferior to 78.5% in phase II clinical study [12]. The possible reason was that the baseline characteristics of patients in phase II clinical study were consistent after strict screening. In the study, the oral dose of pyrotinib was 400 mg, and the combination chemotherapy drugs were capecitabine. In this study, the dose of pyrotinib in 36 patients was 320 mg or 400 mg, with a wide variety of combination chemotherapy drugs, including capecitabine, capcitabine and paclitaxel, etc. The 2019 ASCO head reported the phase III PHENIX

clinical study of pyrotinib, and the PFS of pyrotinib combined with capecitabine regimen reached 11.1 months [16]. The phase II clinical study of MA et al. [12] showed that the PFS of pyrotinib combined with capecitabine in the treatment of HER2-positive advanced breast cancer reached 18.1 months. In our study, the PFS of patients was 13 months, which suggests that pyrotinib has a good efficacy in second-line anti-HER2 therapy in the real world.

The lung and liver are common sites of visceral metastasis in HER2-positive breast cancer, and the presence of visceral metastasis often predicts a poor prognosis. Our real-world analysis showed that the ORR in patients who developed visceral metastases was as high as 63.16%. In the phase II clinical study of pyrotinib [12], there was also a significant advantage of pyrotinib with or without visceral metastasis (HR for visceral metastasis: 0.37, 95% CI: 0.14-0.97; HR for non-visceral metastasis: 0.35, 95% CI: 0.21-0.61). The HER2-positive subtype is a risk factor for brain metastases from breast cancer, with a 5-year cumulative incidence as high as 15.7% [7,17], and ultimately about 50% of patients with HER2-positive metastatic breast cancer develop brain metastases [18]. Brain metastasis itself and radiotherapy for brain metastasis can lead to impaired cognitive and sensory function, which becomes the main factor affecting the life expectancy and quality of life of patients. Cytotoxic drugs have limited effects on brain metastases due to blood-brain barrier limitations. In recent years, with the clinical application of small molecule targeted drugs, more patients with brain metastases from breast cancer have seen hope from small molecule targeted therapy [12]. The results of pyrotinib treatment in patients with brain metastases in this study were encouraging, with ORR as high as 42.85% in patients, and 3 of 7 patients with brain metastases achieved PR and 3 SD. In addition, the preliminary results of the PHENIX phase III clinical trial showed that in patients who progressed after trastuzumab treatment, the PFS of patients with baseline brain metastases could reach 6.9 months under the premise of no radiotherapy, and the proportion of patients with new brain metastases after pyrotinib treatment was lower in patients without baseline brain metastases (1.2% vs 3.6%) [16]. This shows that pyrotinib can effectively reduce and control the time of brain metastases, also has a good effect on patients with brain metastases, and effectively improve the quality of life of patients. However, there were few patients with brain metastases in this study, and the treatment data may be biased, which needs to be verified by further randomized studies with large sample size.

At present, in addition to capecitabine, no relevant reports have been observed to evaluate the specific efficacy of pyrotinib combined with other chemotherapeutic drugs. According to the experience of trastuzumab, tegafur [19], paclitaxel [20], vinorelbine [21] and cecitabinecan [22] also be selected for combination chemotherapy. Therefore, when we developed the combination chemotherapy regimen, we selected other drugs for patients who had previously used capecitabine and also achieved good results. In addition, our study showed that the AEs treated with pyrotinib were mainly diarrhea with an incidence of 80.55%, which is consistent with the results of previous studies [12,14,16]. One patient also had grade 4 neutropenia and grade 3 thrombocytopenia, which were considered to be related to chemotherapy drugs. The overall AEs of pyrotinib were controllable with high safety.

This study has several limitations, the most important of which

is the small sample size and the varied baseline characteristics of the patients, so the experimental data may be subject to a large bias. In addition, the follow-up of the study was not long enough, and important data including PFS of patients could not be obtained, which was unfavorable for further analysis. In addition, whether the amplification level of HER2, the effective time of previous anti-HER2 therapy, etc. affect the efficacy of pyrotinib was not analyzed. Despite these limitations, our study has several important values, first this study provides first-hand data on the efficacy of pyrotinib treatment in the real world and assesses the clinical efficacy of pyrotinib in combination with other chemotherapeutic drugs except capecitabine, which may have important guidance for treatment in the clinic. Secondly, this provides supplementary data for the upcoming registration clinical trial in China.

## Conclusion

In conclusion, our study showed that pyrotinib combined with chemotherapy in the treatment of HER2-positive breast cancer has a significant effect, with overall controllable side effects and high safety.

## References

- Macpherson IR, Spiliopoulou P, Rafii S et al. A phase I/II study of epertinib plus trastuzumab with or without chemotherapy in patients with HER2-positive metastatic breast cancer. *Breast Cancer Res*. 2019; 22: 1.
- Squires H, Stevenson M, Simpson E, et al. Trastuzumab Emtansine for Treating HER2-Positive, Unresectable, Locally Advanced or Metastatic Breast Cancer after Treatment with Trastuzumab and a Taxane: An Evidence Review Group Perspective of a NICE Single Technology Appraisal. *Pharmacoeconomics*. 2016; 34: 673-80.
- Eroglu Z, Tagawa T, Somlo G. Human epidermal growth factor receptor family-targeted therapies in the treatment of HER2-overexpressing breast cancer. *The oncologist* 2014; 19: 135-150.
- Dawood S, Broglio K, Buzdar AU, et al. Prognosis of women with metastatic breast cancer by HER2 status and trastuzumab treatment: an institutional-based review. *Journal of clinical oncology*. 2010; 28: 92-98.
- Vogel CL, Cobleigh MA, Tripathy D, et al. Efficacy and safety of trastuzumab as a single agent in first-line treatment of HER2-overexpressing metastatic breast cancer. *Journal of Clinical Oncology*. 2002; 20: 719-726.
- Gianni L, Pienkowski T, Im Y-H, et al. Efficacy and safety of neoadjuvant pertuzumab and trastuzumab in women with locally advanced, inflammatory, or early HER2-positive breast cancer (NeoSphere): a randomised multicentre, open-label, phase 2 trial. *The lancet oncology*. 2012; 13: 25-32.
- Geyer CE, Forster J, Lindquist D, et al. Lapatinib plus capecitabine for HER2-positive advanced breast cancer. *New England journal of medicine*. 2006; 355: 2733-2743.
- Takano T, Tsurutani J, Takahashi M, et al. A randomized phase II trial of trastuzumab plus capecitabine versus lapatinib plus capecitabine in patients with HER2-positive metastatic breast cancer previously treated with trastuzumab and taxanes: WJOG6110B/ELTOP. *Breast*. 2018; 40: 67-75.
- Verma S, Miles D, Gianni L, et al. Trastuzumab emtansine for HER2-positive advanced breast cancer. *N Engl J Med*. 2012; 367: 1783-1791.
- Wang C, Lin Y, Zhou Y, et al. Pyrotinib with trastuzumab and aromatase inhibitors as first-line treatment for HER2 positive and hormone receptor positive metastatic or locally advanced breast cancer: study protocol of a randomized controlled trial. *BMC Cancer*. 2020; 20: 653.
- Li Q, Guan X, Chen S, et al. Safety, Efficacy, and Biomarker Analysis of Pyrotinib in Combination with Capecitabine in HER2-Positive Metastatic Breast Cancer Patients: A Phase I Clinical Trial. *Clin Cancer Res*. 2019; 25: 5212-5220.
- Ma F, Ouyang Q, Li W, et al. Pyrotinib or Lapatinib Combined With

- Capecitabine in HER2-Positive Metastatic Breast Cancer With Prior Taxanes, Anthracyclines, and/or Trastuzumab: A Randomized, Phase II Study. *J Clin Oncol*. 2019; 37: 2610-2619.
13. Li X, Yang C, Wan H, et al. Discovery and development of pyrotinib: A novel irreversible EGFR/HER2 dual tyrosine kinase inhibitor with favorable safety profiles for the treatment of breast cancer. *European Journal of Pharmaceutical Sciences* 2017; 110: 51-61.
  14. Blair HA. Pyrotinib: first global approval. *Drugs*. 2018; 78: 1751-55.
  15. Meng J, Liu X-Y, Ma S, et al. Metabolism and disposition of pyrotinib in healthy male volunteers: covalent binding with human plasma protein. *Acta Pharmacologica Sinica* 2019; 40: 980-988.
  16. Jiang Z, Yan M, Hu X, et al. Pyrotinib combined with capecitabine in women with HER2+ metastatic breast cancer previously treated with trastuzumab and taxanes: A randomized phase III study . *American Society of Clinical Oncology*. 2019.
  17. Verma S, Miles D, Gianni L, et al. Trastuzumab emtansine for HER2-positive advanced breast cancer. *New England Journal of Medicine*. 2012; 367: 1783-1791.
  18. Pestalozzi BC, Holmes E, De Azambuja E et al. CNS relapses in patients with HER2-positive early breast cancer who have and have not received adjuvant trastuzumab: a retrospective substudy of the HERA trial (BIG 1-01). *The lancet oncology*. 2013; 14: 244-248.
  19. Fujii T, Horiguchi J, Yanagita Y, et al. Phase II study of S-1 plus trastuzumab for HER2-positive metastatic breast cancer (GBCCSG-01). *Anticancer research*. 2018; 38: 905-909.
  20. Tolane SM, Barry WT, Dang CT, et al. Adjuvant paclitaxel and trastuzumab for node-negative, HER2-positive breast cancer. *New England Journal of Medicine*. 2015; 372: 134-141.
  21. Esfahani K, Ferrario C, Le P et al. The trastuzumab and vinorelbine combination: an alternative to taxane-based chemotherapy for early-stage and locally advanced her2-positive breast cancer. *Current Oncology*. 2014; 21: e723.
  22. Stein S, Demichele A, Domchek S et al. Gemcitabine and trastuzumab combinations for patients with metastatic breast cancer overexpressing HER2/neu. *Clinical breast cancer*. 2004; 4: S117-S120.