

## Case Report

# DIAPH1 Mutation as a Novel Cause of Autosomal Dominant Macro Thrombocytopenia and Hearing Loss

Karki R<sup>1\*</sup>, Heilegiorgis Ajebo G<sup>2</sup>, Savage N<sup>3</sup> and Kutlar A<sup>4</sup>

<sup>1</sup>Division of Hematology and Oncology, Medstar Harbor Hospital, USA

<sup>2</sup>Division of Hematology and Oncology, Augusta University, USA

<sup>3</sup>Department of Pathology, Augusta University, USA

<sup>4</sup>Division of Hematology, Augusta University, USA

\*Corresponding author: Nabin Raj Karki, Division of Hematology and Oncology, Medstar Harbor Hospital, 3001 S Hanover St, Baltimore, 20160, USA

Received: December 18, 2019; Accepted: February 13, 2020; Published: February 20, 2020

## Abstract

Macrothrombocytopenia (MTP) is a group of rare disorders characterized by giant platelets, thrombocytopenia and variably associated with abnormal bleeding. Inherited MTP are frequently misdiagnosed as immune thrombocytopenia. Associated second organ manifestation can help narrow down syndromic MTPs. We describe a case of autosomal dominant sensorineural hearing loss and MTP caused by a gain of function mutation in DIAPH1. This mutation causes altered megakaryopoiesis and platelet cytoskeletal deregulation. Although hearing loss and MTP is likely progressive, clinically significant bleeding was not observed. DIAPH1 related MTP can be distinguished clinically from MYH9 mutation by the absence of cataracts and glomerular disease.

## Introduction

Macrothrombocytopenia (MTP) is a heterogeneous group of rare disorders characterized by enlarged circulating platelets that are reduced in number and variably associated with abnormal bleeding. A vast majority of MTPs are acquired. Not uncommonly, inherited thrombocytopenia's are wrongly diagnosed as immune thrombocytopenia's and patient's receive futile treatments. A careful search for associated secondary feature may help guide a workup to identify specific genetic aberration. Altered regulation of platelet formation is a feature of several inherited MTPs. This same alteration may give rise to other disorder due to sharing of affected protein in other organs. Here, we describe a novel cause of inherited MTP resulting from a mutation in a cytoskeletal gene DIAPH1 that also manifests in auditory system.

## Case Summary

A 35 year old Caucasian male was seen in the outpatient clinic for evaluation of thrombocytopenia. He had a long standing history of thrombocytopenia since childhood. He had underwent major surgeries including appendectomy, spine surgeries, left heel surgery without any bleeding issues, and never had transfusions. He was told in the past that his platelets were large and sticky; and clumped together during assays giving a spuriously low number.

He had a history of severe sensorineural hearing loss requiring cochlear implants. His other medical problems were hypertension, internal carotid artery aneurysm and medication overuse headaches. He denied any renal problems and had normal visual equity.

His manual complete blood counts showed:

Total leucocyte count: 17,700/ $\mu$ L

Absolute neutrophil count: 1900/ $\mu$ L

Hemoglobin: 17.7 gm/dL

Platelets: 83,000 cells/ $\mu$ L

Mean platelet volume: 11.9 fL [normal: 7.4-10.4 fL]

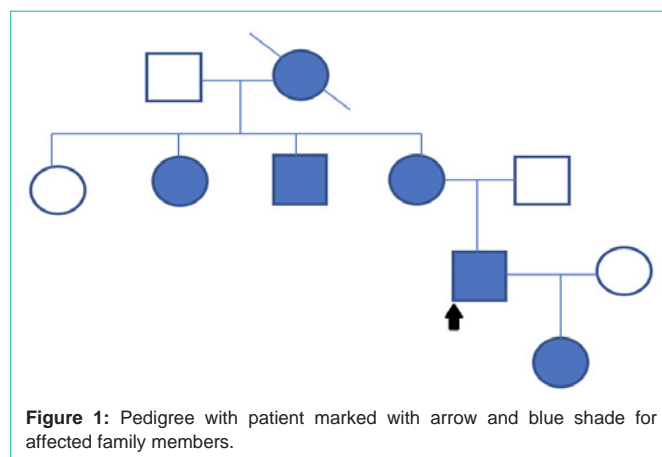


Figure 1: Pedigree with patient marked with arrow and blue shade for affected family members.

Liver function tests: unremarkable

Urine protein: negative

HIV and hepatitis panel: negative

Erythropoietin level: 7.2 mIU/mL [normal: 2.6-18.5]

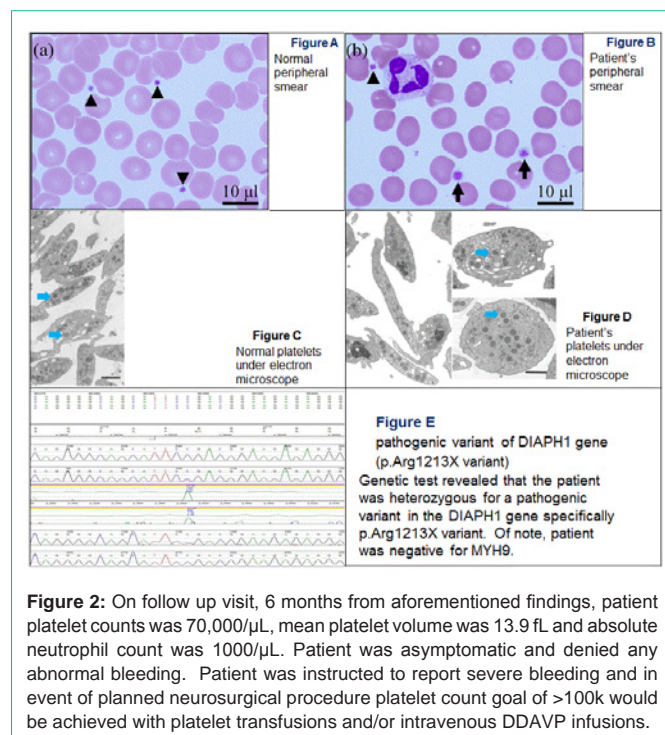
Platelet Function Assay (PFA): abnormal with

PFA C/ADP CT: 265 s [normal: 75-110 s]

PFA C/Epi CT: >300 [normal: 109-183 s]

His family history was notable for hearing problems and low platelet counts in multiple members in his mother's side. His maternal grandmother, mother, a maternal aunt and a maternal uncle all suffered from hearing problems and low platelet counts. The only one among his mother's siblings who didn't have hearing issues was a maternal aunt who also didn't have low platelet counts. His father side of family doesn't have anyone with either hearing issues or low platelet counts (Figure 1).

He denied drinking and is a light smoker (<5 cigarettes/day). His only medication is low dose metoprolol for hypertension.



A manual peripheral smear review and electron microscopy was sent. Genetic testing for a panel of 131 genes associated with hearing loss was sent to GeneDx© after genetic counselling.

Peripheral blood smear with May-Grunwald-Giemsa stain showed platelets of different sizes and large elongated abnormal platelets (Figure 2).

Electron microscopy of these platelets showed very large ovoid platelets with heterogeneous sizes, shapes and distribution of  $\alpha$ -granules (Figure 2).

For comparison, a peripheral smear from a normal patient shows small platelets of more homogenous size (Figure 2).

Electron microscopy of normal platelets showing discoid shape and regular size with homogeneously distributed granules (Figure 2).

Genetic test revealed that the patient was heterozygous for a pathogenic variant in the DIAPH1 gene specifically p.Arg1213X variant. Of note, patient was negative for MYH9.

On follow up visit, 6 months from aforementioned findings, patient platelet counts was 70,000/ $\mu$ L, mean platelet volume was 13.9 fL and absolute neutrophil count was 1000/ $\mu$ L. Patient was asymptomatic and denied any abnormal bleeding. Patient was instructed to report severe bleeding and in event of planned neurosurgical procedure platelet count goal of >100k would be achieved with platelet transfusions and/or intravenous DDAVP infusions.

## Discussion

Inherited MTPs have been associated with pathogenic variants in genes that regulate megakaryocyte maturation or that encode platelet surface proteins. However, a subgroup of MTP arising from

variants of genes that encode megakaryocyte cytoskeletal proteins or interactors is newly described. The prototype of the later, MYH9 mutation, is associated with a phenotype of hearing loss, cataract and glomerulopathy in addition to MTP [1].

Our case had a heterozygous non sense mutation, p.Arg1213X (c3637C>T) in DIAPH1 gene resulted in a truncated protein. DIAPH1 gene encodes the cytoskeletal regulator and Rho effector Diaphanous related formin 1 (DIAPH1) which is a regulator of megakaryocytopoiesis [2]. DIAPH1 is regulated by a Diaphanous Autoregulatory Domain (DAD) near the carboxy terminus which inhibits DIAPH1 activity through an interaction with the Diaphanous Inhibitory Domain (DID) near the amino terminus. The truncated protein lacks DAD domain and hence is constitutively active resulting in increased filamentous actin and stable microtubules [3]. DIAPH1 is also expressed in the organ of Corti in inner pillar cells and base of outer hair cells, spiral ganglion and cochlear nerve in mice [4]. This gain of function mutation causes autosomal dominant MTP and hearing loss compared to autosomal recessive microcephaly caused by biallelic truncating DIAPH1 mutations [5,6].

Syndromic MTP, hearing loss and mild neutropenia in association with DIAPH1 mutation has been reported lately [3,4,7]. Familial clustering of cases and lack of abnormal bleeding in spite of low platelet counts have been uniformly noted. The low platelet and low normal neutrophil counts in our case is similar to other reports. In 1 case series, the hearing loss and MTP was observed to be progressive [7]. DIAPH1 related disease should be differentiated from MYH9 related syndrome where patients have additional findings of cataract and glomerular disease. Although rare, the DIAPH1 p.Arg1213X variant is a cause of autosomal dominant progressive hearing loss and MTP [3]. Inherited macrothrombocytopenias are usually associated with higher MPV and MPD than immune thrombocytopenias [8]. In clinically suspected cases, DIAPH1 should be tested in addition to MYH9 as they overlap in their clinical feature and platelet morphology.

## Conclusion

A gain of function variant in DIAPH1 causes MTP and sensorineural hearing loss and is inherited in an autosomal dominant fashion. DIAPH1 related disease does not cause cataract and glomerular disease as opposed to MYH9 mutation. Patients with hearing loss and MTP should be probed for family history and DIAPH1 should be examined.

## References

- Saposnik B, Binard S, Fenneteau O, Nurden A, Nurden P, Hurtaud-Roux MF, et al. Mutation spectrum and genotype-phenotype correlations in a large French cohort of MYH9-Related Disorders. *Mol Genet genomic Med.* 2014; 2: 297–312.
- Pan J, Lordier L, Meyran D, Rameau P, Lecluse Y, Kitchen-Goosen S, et al. The formin DIAPH1 (mDia1) regulates megakaryocyte proplatelet formation by remodeling the actin and microtubule cytoskeletons. *Blood.* 2014; 124: 3967–3977.
- Stritt S, Nurden P, Turro E, Greene D, Jansen SB, Westbury SK, et al. A gain-of-function variant in DIAPH1 causes dominant macrothrombocytopenia and hearing loss. *Blood.* 2016; 127: 2903–2914.
- Neuhaus C, Lang-Roth R, Zimmermann U, Heller R, Eisenberger T, Weikert M, et al. Extension of the clinical and molecular phenotype of DIAPH1-associated autosomal dominant hearing loss (DFNA1). *Clin Genet.* 2017; 91:

- 892–901.
5. Al-Maawali A, Barry BJ, Rajab A, El-Quessny M, Seman A, Coury SN, et al. Novel loss-of-function variants in DIAPH1 associated with syndromic microcephaly, blindness, and early onset seizures. *Am J Med Genet A*. 2016; 170: 435–440.
  6. Ercan-Sencicek AG, Jambi S, Franjic D, Nishimura S, Li M, El-Fishawy P, et al. Homozygous loss of DIAPH1 is a novel cause of microcephaly in humans. *Eur J Hum Genet*. 2015; 23: 165–172.
  7. Ganaha A, Kaname T, Shinjou A, Chinen Y, Yanagi K, Higa T, et al. Progressive macrothrombocytopenia and hearing loss in a large family with DIAPH1 related disease. *Am J Med Genet A*. 2017; 173: 2826–2830.
  8. Noris P, Klersy C, Zecca M, Arcaini L, Pecci A, Melazzini F, et al. Platelet size distinguishes between inherited macrothrombocytopenias and immune thrombocytopenia. *J Thromb Haemost*. 2009; 7: 2131–2136.