

Clinical Image

Erythrophagocytosis by Neutrophils in Paroxysmal Cold Hemoglobinuria

Sampagar A¹, Bartakke S^{2*}, Lukade U³ and Sethuratnam S³

¹Department of Pediatrics, Jawaharlal Nehru Medical College and Hospital, India

²Department of Clinical Hematology, Aditya Birla Memorial Hospital, India

³Department of Pathology, Aditya Birla Memorial Hospital, India

*Corresponding author: Sandip Bartakke, Department of Clinical Hematology, Aditya Birla Memorial Hospital, Pune, India

Received: April 12, 2017; Accepted: April 27, 2017;

Published: May 17, 2017

Clinical Image

Paroxysmal Cold Hemoglobinuria (PCH) is the most common cause of acute autoimmune hemolytic anaemia in children [1,2]. The presence of marked erythrophagocytosis by neutrophils is a relatively rare observation on blood smears, but it is a prominent feature of PCH [3-5]. This case highlights the necessity for clinicians to be aware of the importance of erythrophagocytosis in diagnosis of PCH.

A 4-year-old boy presented with 4 days history of fever, jaundice and dark colored urine. On examination, he had pallor and icterus. A complete blood count was remarkable for haemoglobin of 41 gm/l, a white cell count of $27.1 \times 10^9/l$ and a platelet count of $367 \times 10^9/l$. The reticulocyte count was 2%. Serum lactate dehydrogenase was significantly elevated at 4700 U/L. His serum creatinine was 2.0 mg/dl and urine analysis showed presence of hemoglobin.

The peripheral blood smear showed occasional spherocytes and neutrophilic leucocytosis. Approximately 22% of neutrophils showed

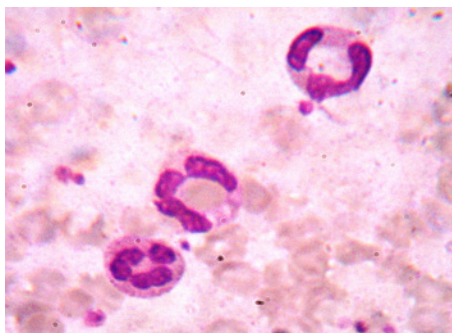


Figure 1:

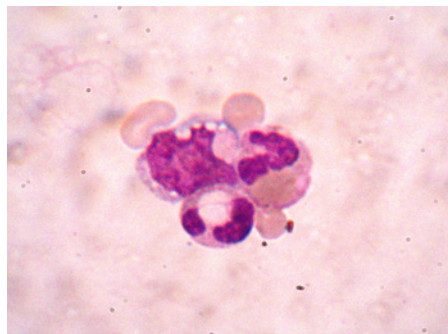


Figure 2:

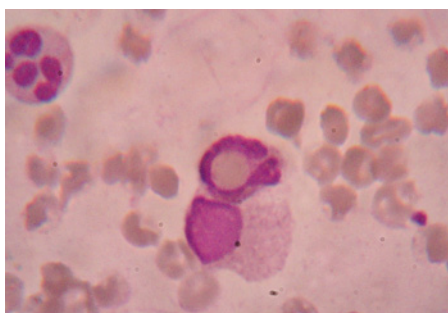


Figure 3:

erythrophagocytosis. The direct antiglobulin test was strongly positive with complement and was negative with polyspecific antihuman globulin. The above laboratory results were suggestive of intravascular haemolysis due to cold-reactive autoantibody. The diagnosis of PCH was confirmed by positive Donath- Landsteiner antibody test.

References

1. Weerakkody RM, Ranasinghe NN, Sivagnanam FG. A case of paroxysmal cold haemoglobinuria following chickenpox. *Ceylon Med J.* 2010; 55: 96.
2. Mukhopadhyay S, Keating L, Souid AK. Erythrophagocytosis in paroxysmal cold hemoglobinuria. *Am J Hematol.* 2003; 74: 196-197.
3. Chandrashekar V, Soni M. Florid Erythrophagocytosis on the Peripheral Smear. *J Lab Physicians.* 2012; 4: 59-61.
4. Heddle NM. Acute paroxysmal cold hemoglobinuria. *Transfus Med Rev.* 1989; 3: 219-229.
5. Garratty G. Erythrophagocytosis on the peripheral blood smear and paroxysmal cold hemoglobinuria. *Transfusion.* 2001; 41: 1073-1074.