

Case Report

Asymptomatic Rhabdomyoma of the Larynx: Case Report and Review of the Literature

Ahmed HS¹, Parikh AS², Srikanth P¹, Tjoa T³, Faquin WC⁴ and Lin DT^{2*}

¹Harvard Medical School, USA

²Department of Otolaryngology, Massachusetts Eye and Ear Infirmary, USA

³Department of Otolaryngology, University of California Irvine, USA

⁴Department of Pathology, Massachusetts Eye and Ear Infirmary, USA

*Corresponding author: Lin DT, Department of Otolaryngology, Massachusetts Eye and Ear Infirmary, 243 Charles Street, Boston, MA 02114, USA

Received: January 09, 2017; Accepted: February 13, 2017; Published: February 17, 2017

Abstract

Rhabdomyoma of the head and neck is an uncommon tumor. Tumor occurrence in the larynx is particularly rare, with only 53 reported cases. We describe the case of a 59-year-old woman with an asymptomatic, incidentally discovered adult type rhabdomyoma of the left aryepiglottic fold, successfully treated with endoscopic resection. We also conduct a comprehensive review of the literature, including operative management and surgical outcomes. Of 53 cases reviewed, the mean age at diagnosis was 33.8 years and a 2.4:1 male predominance was observed. The most common presenting symptom was hoarseness, and the most common site of origin was the true vocal fold. Endoscopic and open resection were used at similar rates, and there were no obvious differences in patient characteristics by surgical approach. However, a higher recurrence rate and shorter time to recurrence were observed with endoscopic resection, as compared with open resection. Thus, we suggest the potential downside of endoscopic management that must be balanced with the potential for significantly lower morbidity and ease of re-resection when considering the appropriate surgical approach for a given patient.

Keywords: Larynx; Rhabdomyoma; Laryngeal neoplasms

Introduction

Rhabdomyomas are extremely rare benign neoplasms of striated muscle and comprise less than 2% of all skeletal muscle tumors [1]. Most extracardiac rhabdomyomas occur in the head and neck, specifically the oropharynx, larynx, pharyngeal constrictor muscles, submandibular region, base of the tongue, and less commonly lip, lateral neck, soft palate, uvula, cheek, and orbit [2-6].

Rhabdomyomas of the head and neck are slow-growing and well-circumscribed; malignant transformation is rare [4,7]. Treatment generally involves surgical excision of the lesion, preventing invasion of surrounding tissues and obstruction of the airway or esophageal inlet. Although treatment is typically curative, these lesions do occasionally recur. Histologically, rhabdomyomas are divided into two types: neoplastic and hamartoma [8]. Neoplastic rhabdomyomas are further classified into adult, fetal, and genital (or vaginal) subtypes [8]. Adult type rhabdomyomas are characterized by sheets of closely-packed polygonal vacuolated (glycogen-containing) cells with granular eosinophilic cytoplasm, with occasional cross-striations and prominent nucleoli [2,3]. Fetal cellular type is characterized by immature skeletal muscle elements at varying stages of differentiation [2], while genital cellular type appears as a mixture of fibroblast-like cells with clusters of mature cells with cross-striations and collagen- and mucoid-rich matrix [3].

Clinically, adult type rhabdomyomas occur in the soft tissues of the head and neck in 70 to 93% of cases; the fetal subtype is most prevalent in children, and the genital (also known as vaginal) type is typically a polypoid mass found in the vagina and vulva of middle-aged women [3,4,6]. The most common presenting symptoms for the adult type are hoarseness, dyspnea, and dysphagia [3,4]. Fetal type rhabdomyomas

present with obstructive and constrictive oropharyngeal symptoms, and the genital type is typically asymptomatic but presents with dyspareunia [3,9].

Here, we describe the case of an incidentally discovered adult rhabdomyoma of the larynx in a 59-year-old woman. We also systematically review 53 cases of laryngeal rhabdomyoma reported in the literature, which to our knowledge, has not been done previously.

Case Presentation

The patient is 59-year-old woman with a 40 pack year smoking history who presented to her primary care physician for routine care. Given her extensive smoking history, a screening chest CT was ordered and demonstrated a left upper lobe lung mass. Subsequent PET-CT showed this lung mass, as well as an incidental 3.2 cm left supraglottic laryngeal mass, and the patient was referred to otolaryngology. Fiberoptic laryngoscopy showed a large obstructing left arytenoid mass with normal overlying mucosa. Dedicated neck CT showed a well-circumscribed, oval, left supraglottic mass measuring 3.3x2.8x1.8 cm, centered in the left piriform sinus and along the left aryepiglottic fold, without involvement of the true vocal folds (Figure 1).

The patient underwent direct laryngoscopy with biopsy and at that time, and an elective tracheotomy was performed due to concern for airway obstruction from the mass. The biopsy showed large polygonal tumor cells, with immunohistochemistry strongly positive for desmin and negative for keratin, S-100, Sox-10, NSE, and CD68, consistent with a diagnosis of adult rhabdomyoma. The patient underwent endoscopic surgical resection, with a combination of laryngeal microscissors, OmniGuide CO₂ laser, and microdebrider (Figure 2). A complete resection was achieved, with the area of attachment to

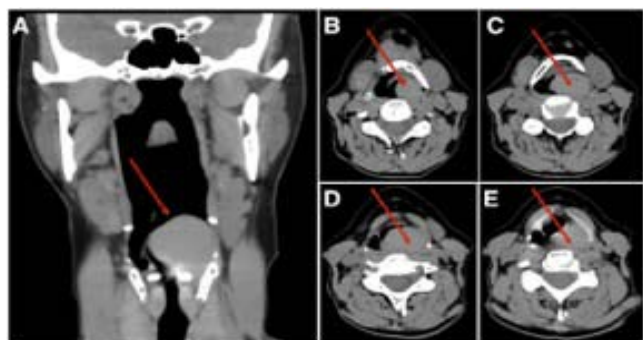

Figure 1: CT neck showing left supraglottic mass on coronal (A) and axial (B-E) sections.

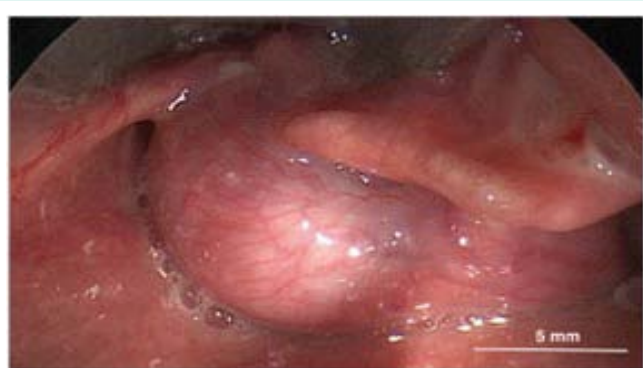

Figure 2: Intra-operative image showing large, well-circumscribed mass arising from left aryepiglottic fold.

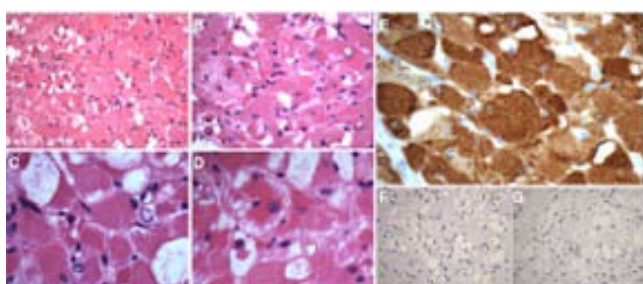


Figure 3: Hematoxylin and eosin staining of adult rhabdomyoma showing large polygonal vacuolated cells with eosinophilic cytoplasm (A, B), with occasional cross-striations (C) and prominent nucleoli (D). Immunostaining of adult rhabdomyoma showing positive desmin immunoreactivity (E) and negative synaptophysin (F) and S-100 (G) and immunoreactivity.

the left aryepiglottic fold free of gross disease. Final pathology was consistent with the initial biopsy specimen (Figure 3). The patient had no evidence of tumor recurrence at a 9 month follow up visit. Regarding her lung mass, she also underwent left upper lobectomy, which revealed stage I non-small cell lung cancer.

Discussion and Conclusion

We describe the case of an asymptomatic, incidentally-discovered rhabdomyoma of the supraglottic larynx, arising from the left aryepiglottic fold. We also perform a comprehensive review the literature using the MEDLINE database as indexed by PubMed. The MEDLINE database was searched using the terms “rhabdomyoma

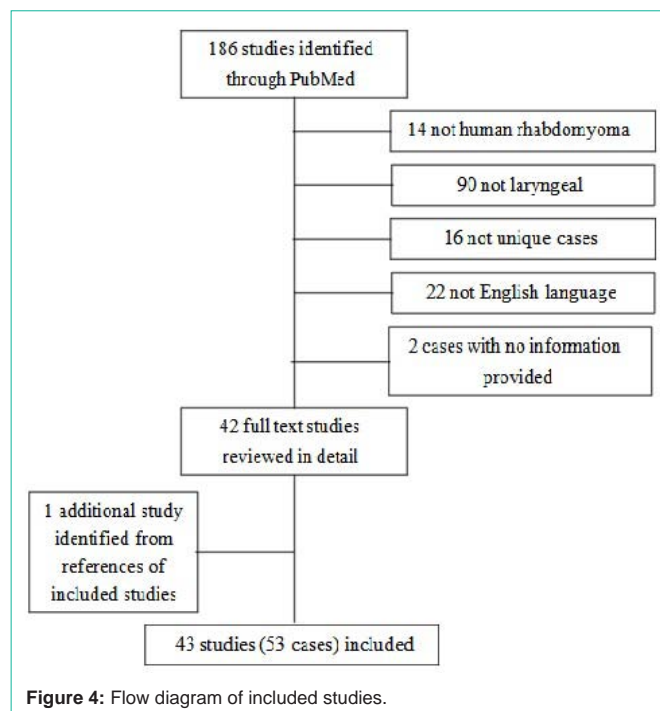


Figure 4: Flow diagram of included studies.

larynx,” “laryngeal rhabdomyoma,” and “rhabdomyoma head neck.” A total of 186 entries were screened by title and abstract. Articles were excluded if they were not human rhabdomyoma (14), not laryngeal (90), not unique cases (13), or not English-language (22). In addition, one case was added based on references from articles obtained from the above searches [2]. A total of 53 cases were included (Figure 4) (Table 1).

Patients with laryngeal rhabdomyoma are most commonly middle-aged men presenting with hoarseness [7]. Other presenting symptoms include dysphagia [7], dyspnea [10], dysphonia [11], and rarely stridor [11], aspiration [12], and airway obstruction [13]. Mean age at diagnosis was 33.8 years (range 1.25 to 82 yrs), with a 2.4:1 male predominance. 40/53 cases (75%) were adult rhabdomyomas, 11/53 (21%) were fetal type, 2/53 (4%) did not report a type. The most common subsites were the true vocal fold (20/53 cases, 38%), false vocal fold (7/53 cases, 13%), and the aryepiglottic fold (5/53 cases, 9%).

On biopsy, histopathology typically demonstrates large closely-packed polygonal cells that often have a spiderweb-like appearance [14,15]. Immunohistochemically, rhabdomyomas stain positively for myoglobin, desmin, and myo-D1, with occasionally positive muscle-specific actin. Immunoreactivity for smooth muscle actin, S-100 protein, vimentin, Leu-7 and cytokeratin are typically negative. There is typically no immunoreactivity for epithelial markers, chromogranin, synaptophysin, glial fibrillary acidic protein, or CD68 (KP-1), and the expression of proliferation marker ki-67 is low, consistent with the indolent, slow-growing nature of these tumors. Electron microscopy typically shows thin and thick myofilaments with Z-band material [14,15]. An accurate diagnosis can be made due to the characteristic microscopic appearance and immunohistochemical staining. Our patient’s histopathology and immunostaining are consistent with the diagnosis of adult type rhabdomyoma.

Table 1: Laryngeal rhabdomyomas previously described in literature.

Age/ Sex	Site	Symptom(s)	Treatment	Type	Size (cm)	Follow-up/Outcome
23M	TVF	Hoarseness	Endoscopic excision	Fetal	1.5	No recurrence after 1 yr
39F	FVF to subglottis	Hoarseness	Laryngofissure	NS	3	No follow up reported
82M	TVF	Hoarseness	None (found at autopsy)	Adult	1	No recurrence at 20 yr
48M	TVF	Hoarseness	Endoscopic excision	Adult	1	No recurrence at 1 yr
55M	FVF to subglottis	Hoarseness	Laryngofissure	Adult	5	No follow up reported
36F	Ventricle	Hoarseness	Laryngofissure	Adult	1.5	No follow up reported
50M	Interarytenoid region	Hoarseness, dysphonia	Endoscopic excision	Fetal	1.5	No recurrence at 1 yr
52F	FVF	Hoarseness	Endoscopic excision	Adult	0.5	No recurrence after 7 mo
39M	TVF	Hoarseness	Endoscopic excision	Adult	0.5	Local resections for recurrences at 2, 7, 11 mo
55M	FVF	Not reported	Endoscopic excision	Adult	2.5	No recurrence at 2 yr
64F	Ventricle	Hoarseness, globus	Endoscopic excision	Adult	1.5	No recurrence at 3 mo
16M	TVF, thyroid cartilage	Airway obstruction	Total laryngectomy	Adult	2	No recurrence at several yr
76F	TVF	Hoarseness	Endoscopic excision	Adult	0.75	No recurrence at 2 yr
53M	TVF	Hoarseness	Open excision	Fetal	NS	No recurrence at 3.5 yr
65F	TVF	Hoarseness	Open excision	Fetal	NS	No recurrence at 1.5 yr
58M	AE fold, pyriform sinus	Dysphagia, globus	Transhyoidpharyngotomy	Adult	3	No recurrence at 2 yr
34F	Anterior TVF	Hoarseness	Endoscopic excision	Fetal	3	Two recurrences; lateralpharyngotomy then supraglotticlaryngectomy at 7 mo, no recurrence at 3 yr
60M	Ventricle	Not reported	Unspecified	Adult	15	No follow up reported
31M	FVF	Hoarseness	Lateral thyrotomy	Fetal	3	No recurrence at 1 yr
78F	Posterior TVF	Hoarseness	Endoscopic excision	Fetal	0.6	No recurrence at 2 yr
52M	TVF	Hoarseness	Lateral pharyngotomy	Adult	1.5	No recurrence at 18 mo
66M	Inferior to TVF	Hoarseness	Unspecified	Adult	3	No follow up reported
44M	Posterior TVF	Sore throat	Unspecified	Fetal	0.5	No follow up reported
29M	FVF	Hoarseness	Unspecified	Fetal	1.2	No recurrence at 2 yr
51F	Arytenoid	Dyspnea, dysphagia	Lateral pharyngotomy	Adult	4	Resection for recurrence 12 yr, no recurrence at 2 yr
15 mo F	Subglottis	Dysphagia, stridor	Open excision	Adult	2	No recurrence after 6 mo
32M	Larynx	Not reported	Unspecified	Adult	NS	No follow up reported
59M	Larynx	Hoarseness	Unspecified	Adult	NS	No recurrence at 5 yr
59M	BOT, pharynx, larynx	Airway obstruction	Unspecified	Adult	NS	No recurrence at 10 yr
60M	Larynx	Airway obstruction	Unspecified	Adult	1.5	No recurrence at 2 yr
54M	Larynx, hypopharynx	Airway obstruction	Unspecified	Adult	NS	No recurrence at 2 yr
56F	Interarytenoid region	Dyspnea, dysphagia	Endoscopic excision	Adult	2.5	Recurrence resected, date unknown, no recurrence at 1 yr
31F	TVF	Dysphonia	Unspecified	Adult	NS	No follow up reported
51M	Ventricle	Hoarseness	Hemilaryngectomy	Adult	7.5	No recurrence at 1 yr
64M	AE fold	Asymptomatic	Lateral pharyngotomy	Adult	5	Lateral pharyngotomy for recurrence at 2 mo, contralateral pharyngotomy for recurrence at 7 yr
69F	TVF	Hoarseness	Endoscopic excision	Adult	NS	No recurrence at 6 mo
39M	AE fold, TVF	Dysphagia, aspiration	Unspecified	Adult	NS	No follow up reported
66M	Arytenoid	Hoarseness, dysphagia	Open excision	Adult	NS	No recurrence
81M	TVF	None (incidental finding)	Laryngectomy for SCC	Adult	0.04	No follow up reported
79M	FVF	Hoarseness	Open excision	Adult	2	No recurrence at 6 weeks
69M	Epiglottis	None	Unspecified	Adult	2.8	No follow up reported
66M	Arytenoid	Dysphagia, obstruction	Endoscopic excision	Adult	2	No recurrence at 18 mo

72F	AE fold	Hoarseness, globus	Transoral laser excision	Adult	3.5	No follow up reported
76M	Arytenoid	Hoarseness, dysphagia	Laser debulking	Adult	3.5	Recurrences at 5, 9 mo
68M	Supraglottis	Dysphagia, globus	Open excision	Adult	5.5	No recurrence at 10 mo
NS	Glottis	Dysphonia	Endoscopic excision	NS	NS	No follow up reported
67F	Supraglottis	Hoarseness, dyspnea	Hemilaryngectomy	Adult	3	No recurrence at 16 mo
55M	Supraglottis	Hoarseness, dysphagia	Endoscopic excision	Adult	8.5	Recurrence at 3 mo
35M	Supraglottis	Hoarseness	Endoscopic excision	Adult	NS	No recurrence at 15 mo
42M	TVF	Hoarseness	Endoscopic excision	Fetal	0.5	No follow up reported
11M	Supraglottis, TVF	Dysphonia, stridor	Endoscopic excision	Fetal	1.6	No recurrence at 5 yr
75M	TVF	Hoarseness	Endoscopic excision	Adult	2.2	No recurrence at 1 yr
59F†	AE fold	None	Endoscopic excision	Adult	3.3	No recurrence at 9 mo

TVF: True Vocal Fold; AE: Aryepiglottic; FVF: False Vocal Fold; NS: Not Stated; yr: year; mo: months
 †Current report

Patients with laryngeal rhabdomyoma are generally treated surgically. Of the cases reported in the literature, 18/53 patients (34%) had open resections, while 22/53 patients (42%) had endoscopic resections; there were 13 additional cases for which the surgical details were not reported. Patients who underwent open resection tended to have slightly larger lesions (average size 2 cm vs. 1.6 cm for lesions resected endoscopically), but this difference was not statistically significant. There was no obvious difference in resection technique by age, subsite, or presenting symptom. Of patients who underwent open resection, 2/18 (11%) recurred, while of those who underwent endoscopic resection, 5/22 (23%) recurred. Moreover, the average time to recurrence in patients treated with open surgery was 6.1 years, while in patients treated endoscopically, it was 4.3 months.

Although this sample is small and heterogeneous, these data suggest anecdotally that there may be a higher recurrence rate with endoscopic resection than with open resection. However, this consideration must be balanced with the increased morbidity of an open resection, as well as the relative ease of repeat endoscopic resection when necessary, particularly given the benign nature of these lesions. Moreover, although these lesions do occasionally cause airway obstruction they typically present with other symptoms first and may be readily caught at an early stage with routine surveillance. Thus, endoscopic resection should still be considered when possible but given the potentially increased rate of and accelerated time to recurrence, frequent surveillance should be considered, particularly in the early postoperative period.

References

- Papaspyrou G, Werner JA, Roeßler M, Devaney KO, Rinaldo A, Ferlito A. Adult rhabdomyoma in the parapharyngeal space: report of 2 cases and review of the literature. *Am J Otolaryngol*. 2011; 32: 240-246.
- Imperatori CJ. Rhabdomyoma of the larynx. Report of a case. *The Laryngoscope*. 1933; 43: 945-948.
- Enzinger FM, Weiss SW. Rhabdomyoma. In: Enzinger FM, Weiss SW, eds. *Soft tissue tumors*, 3rd ed. St. Louis: Mosby; 1995; 523-536.
- Kapadia SB, Meis JM, Frisman DM, Ellis GL, Heffner DK, Hyams VJ. Adult rhabdomyoma of the head and neck: a clinicopathologic and immunophenotypic study. *Hum Pathol*. 1993; 24: 608-617.
- Bastian BC, Bröcker EB. Adult rhabdomyoma of the lip. *Am J Dermatopathol*. 1998; 20: 61-64.
- Knowles DM, Jakobiec FA. Rhabdomyoma of the orbit. *American journal of ophthalmology*. 1975; 80: 1011-1018.
- Koutsimpelas D, Weber A, Lippert BM, Mann WJ. Multifocal adult rhabdomyoma of the head and neck: a case report and literature review. *Auris Nasus Larynx*. 2008; 35: 313-317.
- Leon Barnes, John W. Eveson, Peter Reichart DS. WHO Classification of Tumours. *Pathol Genet Head Neck Tumours*. 2005; 209-281.
- Montgomery EA. Biopsy interpretation of the gastrointestinal tract mucosa. Lippincott Williams & Wilkins. 2006.
- Pichi B, Manciooco V, Marchesi P, Pellini R, Ruscito P, Vidiri A, et al. Rhabdomyoma of the parapharyngeal space presenting with dysphagia. *Dysphagia*. 2008; 23: 202-204.
- Elawabdeh N, Sobol S, Blount AC, Shehata BM. Unusual presentation of extracardiac fetal rhabdomyoma of the larynx in a pediatric patient with tuberous sclerosis. *Fetal Pediatr Pathol*. 2013; 32: 43-47.
- Liang GS, Loevner LA, Kumar P. Laryngeal rhabdomyoma involving the paraglottic space. *Am J Roentgenol*. 2000; 174: 1285-1287.
- Jensen K, Swartz K. A rare case of rhabdomyoma of the larynx causing airway obstruction. *Ear Nose Throat J*. 2006; 85: 116-118.
- Weiss SW, Goldblum JR. Osseous soft tissue tumors. Weiss SW, Goldblum JR. *Enzinger and Weiss Soft Tissue Tumors*. 2001.
- Wenig BM. Atlas of head and neck pathology. Elsevier Health Sciences. 2015.