

Review Article

The Therapy of Hairy Cell Leukemia: The State of Art

Lauria AF Gozzetti* and Raspadori D

Department of Hematology, University of Siena, Italy

*Corresponding author: Francesco Lauria, Sezione di Ematologia e Trapianti, Dipartimento di Medicina Clinica e Scienze Immunologiche, Università di Siena & AOUS, Siena, Italy, Email: lauria@unisi.it

Received: March 25, 2015; Accepted: May 01, 2015;

Published: May 08, 2015

Abstract

Hairy cell leukemia is a B-cell chronic lymphoproliferative disorder in which in the last 3 decades has been registered tremendous progress both in the development of effective treatments capable to improve complete remission rates, as well as in elucidating new biologic and molecular aspects of the leukemic hairy cells. α -IFN was the first effective therapeutic approach in HCL capable of improving the clinical course of the disease. However, only after introduction of purine analogs (Pentostatin and Cladribine), a significant improvement in the number and duration of CR has been observed. Beside purine analogs agents who still represent the cornerstone of HCL treatment, the addition of anti-CD20 monoclonal antibody (Rituximab) and/or anti-CD22 (BL22) immunotoxins, represent the best way to rescue patients who failed prior treatments with α -IFN or purine analogs. Finally, new emerging drugs as Vemurafenib (BRAFV600E mutation inhibitor) and Ibrutinib, are under investigation with success in resistant and/or relapsed patients.

Introduction**What is Hairy Cell Leukemia (HCL)**

First described by Bouroncle et al. [1] as leukemic Reticuloendotelios is, HCL is a well-recognized chronic lymphoproliferative disorder frequently associated with anemia, thrombocytopenia, granulocytopenia, monocytopenia, bone marrow fibrosis and splenomegaly. It is characterized by the proliferation of large lymphocytes arising from a post-germinal mature B cell (activated B cell) which present typical cytoplasmic projections (Hairy cells) involving peripheral blood, bone marrow, spleen, liver and, very infrequently, lymphnodes. Common clinical characteristics include fatigue, fever, infections, abdominal discomfort and easy bruising.

HCL is considered a very rare disease accounting for the 2% of all types of leukemia's (500-600 cases every year) and is particularly prevalent in males (male: female ratio 5:1) with a median age at diagnosis of 56 years.

Diagnosis

HCL should be suspected in patients with variable degree of pancytopenia, absolute monocytopenia, and on the recognition, on the peripheral blood smears, of the circulating Hairy cells (HC) and, possibly, by the presence of spleen enlargement (Figure 1). After that, diagnosis should be confirmed by:

- Immune phenotypic analysis of peripheral blood lymphocytes (HC's are characteristically positive with CD103, CD25, CD20, CD22, CD11c, FMC7, CD123 MoAbs).
- Bone marrow aspirate: often dry-tap because of increased fibrosis.
- Bone Marrow biopsy: typical morphological "fried-egg" pattern. Positivity, at the immune histochemical level, with DBA44, CD20, CD103, CD25, ANNEXINA1 MoAbs.

- BRAFV600E mutation. This mutation, first described by Tiacci et al. [2], was present in many cancers including HCL suggesting a possible role of BRAFV600E mutation in the pathogenesis of HCL. This analysis should be considered for investigational purposes and for cases with uncertain diagnosis.
- Negative prognostic aspects are:
- Severe pancytopenia and neutropenia
- Massive splenomegaly
- Increased Hairy cell index (HCI) (defined as bone marrow total cellularity/Hc marrow infiltration, divided by 100)
- Unmutated IGHV configuration
- P53 dysfunction
- Increased HC number in peripheral blood ($\geq 10.000/\mu\text{l}$)
- Increased serum level of soluble Interleukin-2 receptor (sIL-2R)
- Presence of a large abdominal mass

Evolution of treatment in HCL patients

At diagnosis, asymptomatic patients with indolent clinical course and acceptable hematological values should be only observed until an overt clinic-hematological progression.

Patients requiring treatment are those who present with the following characteristics:

- Symptomatic anemia
- Neutropenia ($\leq 1,000/\mu\text{l}$) and/or thrombocytopenia ($\leq 30,000/\mu\text{l}$) independently by related symptoms.
- Symptomatic splenomegaly
- Presence of large abdominal lymphnodes

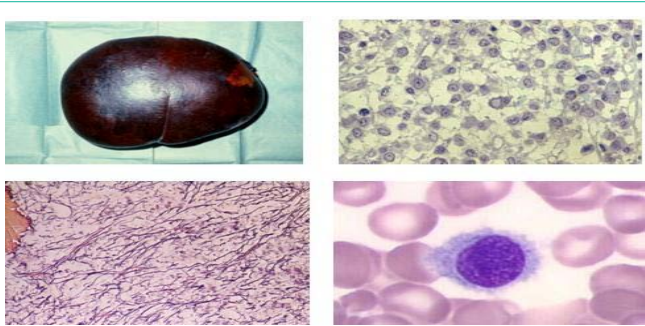


Figure 1: Clinical features of HCL.

- Splenomegaly (>80%)
 - Rare lymph node involvement
 - Pancytopenia with monocytopenia
 - "Hairy" cells in the peripheral blood and in the bone marrow
 - "Fried egg" pattern bone marrow infiltration and increased reticulin fibrosis
- Constitutional symptoms.
 - Associated diseases or unrelated symptoms (i.e. autoimmune disorders, risk of infection or neuropathies).

Prior to early eighties, treatment of HCL patients was unsatisfactory and was based mainly on splenectomy [3]. Since the introduction of α -Interferon (α -IFN) and subsequently of purine analogs: Pentostatin and Cladribine, treatment has become effective and prognosis Improved significantly.

We can identify at least six therapeutic phases:

1. Pre- α -IFN phase where splenectomy was the best therapeutic option.
2. α -IFN phase characterized by the first significant improvement of survival of the patients.
3. Purine analogs phase: Pentostatin and Cladribine employment which had led to more frequent and persistent complete responses.
4. Immunotherapy and immunochemotherapy: anti-CD20 MoAb alone or in combination with purine analogs mainly for progressed or resistant patients.
5. Other Mo Abs combined with immunotoxins.
6. New biological treatments based on the anti-BRAFV600E mutation (constitutional expressed in HCL patients) and on anti BTK-targeted molecules.

Before treatment we should consider the fact that we are dealing with an indolent disease, characterized by a very prolonged survival and thus we must tailor the therapy for each individual patient in order to minimize the risk of life-threatening complications and other adverse events possible causes of death in HCL. Secondly, since at the moment there are no evidence of cure of this disease, our therapeutic approach should be very strategic in employing the therapeutic agents available in order to obtain the more complete and long-lasting response, avoiding to overexpose the patients to several treatments which severely affect hematological and immunological conditions and the performance status.

Splenectomy

Before α -IFN, treatments available for HCL, such as androgens, corticosteroids, lithium, Chlorambucil and splenic irradiation were toxic and scarcely effective. Only splenectomy demonstrated better results leading to a resolution of abdominal discomfort, improvement of anemia, neutropenia and thrombocytopenia acting, at least, through 2 principal mechanisms:

- Reducing the splenic pooling
- Removing a large bulk of the disease.
- In fact, it is well known that splenic HCs produce a large amount of cytokines, mainly TNF and soluble Interleukin2 which exert inhibitory effect on the hematopoietic progenitor cells [4,5,6] and impairment of immunological status(7,8), respectively. This explains why, after splenectomy, despite the persisting bone marrow involvement hematological improvement was better than that expected with the removal of the simple pooling effect. However, splenectomy at the onset of the disease should be considered only in selected cases such as splenic infarct or rupture and in case of pregnancy (in this latter case α -IFN is another valid therapeutic option). During the course of the disease, splenectomy should be considered as a part of treatment in particular cases (i.e. need of therapy in progressive patients with marked cytopenia and large spleen).

α -Interferon

Interferons are cytokines involved in the regulation of several cellular processes and are able to block viral replication. Until now, the mechanism by which α -IFN is so effective in HCL has remained uncertain. Direct antileukemic effect, induction of HCs apoptosis, inhibition of TNF effect on the proliferation of HCs as well as induction of T-cell cytotoxicity against HCs are the mechanisms often recognized to α -IFN [9-11].

α -IFN represents the first effective therapeutic approach in HCL capable of changing the clinical course and the survival in this disease [12]. The administration of this lymphokine leads to the progressive reduction and disappearance of circulating HCs, improvement of hematological values, (reappearance of monocytes followed by the increase of neutrophils) and lastly by the progressive improvement of bone marrow normal cellularity. Furthermore, in splenomegalic patients, treatment with α -IFN is also capable of producing a marked reduction or even disappearance of splenic enlargement [13,14]. Finally, an improvement of T-cell subset distribution, as well as a marked enhancement and/or normalization of the depressed Natural Killer (NK) function, has been reported [15]. Despite these therapeutically effects, complete remission are rare, bone marrow results are often unsatisfactory due to the persistence of small clusters of HCs. Discontinuation of treatment leads, in few months, to the progression of the disease, even in those who achieved a morphological CR. Only prolonged treatment with α -IFN, maintained for years, even at reduced doses may produce, in sensitive patients, true and persistent CR. Therefore, treatment with α -IFN implies maintenance for several years if the common adverse events such as flu-like

syndrome, gastrointestinal symptoms, liver toxicity, hair and weight loss, libido reduction and chronic fatigue are absent or well tolerated by the patient.

Nowadays α -IFN is scarcely employed at the onset of the disease; however, treatment is particularly suggested in patients with severe neutropenia and/or bone marrow hypocellularity with concurrent high risk of infection. It has been employed before purine analogs to improve peripheral blood counts in order to render safer subsequent treatment with Cladribine or Pentostatin (16). α -IFN could be also used after purine analogs as consolidation/maintenance in case of incomplete remission in cytopenic patients. Finally, it could be considered in HCL pregnant women ineligible or refusing splenectomy.

Purine Analogs

Pentostatin and Cladribine are now considered the principal and most employed therapeutic agents in the management of HCL patients. Both act on the Adenosine Deaminase (ADA) cascade an enzyme predominantly expressed on lymphoid cells which plays an important role in the differentiation of both T and B lymphocytes.

Pentostatin

Pentostatin is a purine analog (anti metabolite) that irreversibly inhibits ADA with the consequent accumulation of the deoxyadenosine triphosphate metabolites that will eventually cause DNA strand breaks and cell death [17,18]. Efficacy in HCL was firstly documented by Spiers et al. [19] who reported responses in 26 out of 27 patients treated. Subsequently, high response rates were confirmed by several other investigators with CR rates remarkably high never reported with splenectomy neither with α -IFN [20-22]. High and persistent response rates were documented in untreated as well as in those previously splenectomized and/or treated with α -IFN. In a large seminal trial [23] where HCL patients were randomized to receive α -IFN or Pentostatin, it was documented that Pentostatin induced more frequent and longer responses, while patients treated with α -IFN achieved a negligible proportion of CR together with a progression free-survival significantly shorter than that achieved with Pentostatin. However, in these latter patients, hematological and immunological toxicity with an increased life-threatening infection complications, were often observed [24,25].

The recommended dose of Pentostatin is: 4 mg/m² every 2 weeks for 4-6 weeks and then 2 additional administrations every month. The CR rate ranges from 44 to 100% [19-25].

Overall, Pentostatin is an extremely effective drug that may induce frequent and durable responses in HCL. However, the high risk of neutropenic infections, lymphocytopenia and monocytopenia should be taken always in to consideration mainly in older patients and/or in those heavily treated.

Cladribine

Cladribine is a purine analog that does not inhibit ADA, but is highly resistant to adenylating enzyme due to the introduction of an additional hydrogen atom in position 2 of purine ring [15]. Cladribine enter lymphoid cells where is phosphorylated by a deoxycytidine kinase creating mono, bi and triphosphate deoxynucleotides that accumulate in the cells and are incorporated in to DNA leading to

DNA breaks and to activation of two enzymatic systems: a poly (ADP-ribose) syntetase that consumes cellular Nicotinamide Adenine Dinucleotide (NAD) and ATP, and dependent endonucleases that determines DNA fragmentation. Depletion of NAD essential for survival and DNA fragmentation will ultimately lead to death and apoptosis [15]. Cladribine is the most common drug used in the treatment of HCL. Piro et al. [26] first described in 1990 Cladribine activity in 12 HCL patients treated with a single 7-day continuous infusion of the drug at the dose of 0.1 mg/Kg a day and observed a response in all cases with 11 CR and one PR. Since then several large studies confirmed the elevated proportion of CR [27-30]. The route and modality of administration of Cladribine has subsequently changed maintaining the high efficacy. Cladribine is now frequently administered intravenously (2-hours daily infusion for 5 or 7 days). The oral bioavailability is variable around 50% while the subcutaneous injection has 100% bioavailability [31].

In order to limit the incidence of severe neutropenia and thrombocytopenia, and infection complications, Cladribine was also administered once a week for 5-7 weeks. This regimen produced similar CR rates and a very low proportion of infectious complications [32].

Profound degree of lymphocytopenia has also been described as well as with Pentostatin. In particular, Cladribine reduces the number and the function of T lymphocytes with a severe and persistent reduction of CD4 positive cells (mainly naive CD4 T cells). CD8 and NK positive cells were less affected [33,34]. This, together with the preservation of CD4 memory cells, may in part explain the reduced infectious complications once neutrophils and monocytes recovery has occurred.

In conclusion, Cladribine is very effective in HCL and in one week of treatment, induces very high CR remission rate independently by the route and modality of administration. However, as for Pentostatin, treatment with Cladribine should be avoided, modified or post-poned in patients with a high risk of infection or bone marrow hypocellularity.

Immunotherapy and Immunochemotherapy

Immunotherapeutic strategies with MoAbs have been investigated and include unlabeled MoAbs targeting CD20 (Rituximab) and recombinant immunotoxins such as LMB2 and BL22, targeting CD25 and CD22, respectively.

Unconjugated monoclonal antibodies (Rituximab)

CD20 is typically expressed at high intensity on HCs and therefore is an ideal target for treatment with Rituximab. However, in the early studies conducted generally in a limited number of cases, responses were variables but only in few cases CR was achieved, suggesting that in relapsed HCL patients or in those still showing an evident residual disease, Rituximab alone was not particularly effective [35,36]. When Rituximab was administered sequentially or concomitantly with purine analogs, CR rates were particularly high and long-lasting [37,38]. However, this combination, because of the toxicity and the high risk of infective complications, should be limited only to progressed and/or resistant patients and not encouraged in patients at diagnosis where neutropenia, lymphocytopenia and monocytopenia are generally more pronounced and the infection complications are

at major risk. The recent introduction of “new” anti-CD20MoAbs, such as atumumab and Obinotumumab, in the treatment of CLL has shown, in combination with Chlorambucil, very exciting results [39,40]. Certainly, the combination of these “new” MoAbs with purine analogs needs to explore in HCL since is reasonable to expect better results than those achieved in combination with Rituximab.

Immunotoxins

LMB2 and BL22 are potent immunotoxins produced, respectively, by an anti-CD25 and anti-CD22 single chain Fv linked to a truncated form of pseudomonas immunotoxin (PE38). Results were extremely interesting in a good proportion of patients with HCL and other lymphoproliferative disorders. Toxicity was also present and characterized mainly by transaminase elevation, nausea, vomiting or hemolytic uremic syndrome and cytokine syndrome [41,42].

Recently, Kreitman et al. [43] produced a further improvement of CD22 immunotoxin called Moxetumomab pasudotox (HA-22, CAT8015) which had higher affinity with CD22 and a 50-fold higher toxicity after modification of BL22. Phase 1 study showed CR in 44% of HCL patients and 76% of them are still responding to the treatment after an observation of 20 months. Toxicity is represented by hypoalbuminemia, edema, aminotransferase elevation, headache and hypotension. Trials with Moxemumomab pasudotox are ongoing.

Emerging Therapies

The BRAF V600E mutation has been first described in melanoma patients and other several human cancers [44,45] including HCL patients where is present in almost all cases [2]. This observation led to the synthesis of Vemurafenib, a BRAFV600E inhibitor approved for mutant metastatic melanoma and employed also in HCL patients resistant to chemotherapy. Given orally at a dose of 960 mg twice daily, Vemurafenib led, in 29 HCL relapsed/resistant patients, to durable remissions with rapid normalization/improvement of peripheral hematological values and spleen size [46]. In addition, similar good results were reported in an additional study [47].

Treatments under Investigation

Following the experience raised in patients with CLL and non-Hodgkin lymphomas [39], the oral Bruton’s thymosin kinase inhibitor (PC-32765) (Ibrutinib) has being studied in clinical trials as single agent for the treatment of relapsed HCL patients [48].

First line of treatment

The majority of HCL patients, who require treatment at diagnosis, nowadays are best treated with Cladribine or Pentostatin. Cladribine is generally preferred because a lower toxicity and it can be given in a single 5-day course.

In patients with an older age, severe neutropenia, hypocellular bone marrow and/or inter current infection, α -IFN is a safer treatment and should be preferred in order to avoid the risk of life-threatening infections. We should take into account that partial response is not particularly different from a more complete response in terms of quality of life and survival. In these patients, once achieved a good hematological response, a further consolidation with purine analogs may be considered.

In case of pregnancy, α -IFN should be preferred.

Second line of treatment

Patients who relapse after purine analogs within 24 months, or those who at the end of treatment experienced an unsatisfactory response, should be treated with a combination of Rituximab given concomitantly/or sequentially with Cladribine or Pentostatin depending by the previous purine analog employed. Anyhow, we should be aware that sometime response could be delayed therefore; poor response should not be confused with a late response. A possible therapeutic alternative could be represented by the immunotherapy with Moxetumomab pasudotox especially if the ongoing trials will give the expected good results. Randomized studies are warranted in these relapsed cases and the inclusion of the majority of patients in trials exploring the effect of the emerging molecules in B-cell lymphoproliferative disorders such as the “new” anti-CD20 MoAbs, Ibrutinib and Idelalisib are mandatory. Anyway, in relapsed patients we should always perform, before retreatment, bone marrow HCL, peripheral hematological values and spleen size.

Third line of treatment

Vemurafenib presents, the treatment of choice for the pluri-progressed or resistant patients. Alternatively, these patients should enter in clinical trials exploring the effect of emerging drugs (Figure 2).

Conclusive Considerations

At the moment, the treatment of HCL is very satisfactory since we can obtain, in the majority of cases, long-lasting good clinical and hematological responses. For the minority of cases who tend to have rapid relapses, the future should be regarded with optimism since numerous new effective agents and scarcely toxic and often given orally, are coming.

An important question is what should be the strategic approach

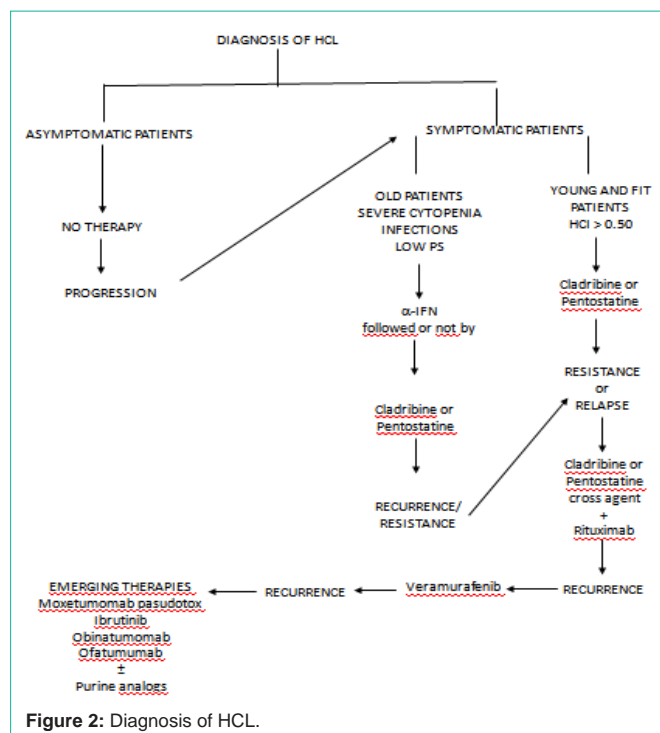


Figure 2: Diagnosis of HCL.

to HCL patients? Should we pursue the eradication of the disease or instead try to control it using sequentially, and at best, all the drugs that are available at the moment? True CRs, even assessed with immunohistochemistry and/or with immunofenotypic or molecular tools, are few and there are no proofs that in these patients survival is significantly longer than that obtained in patients with morphological CR. Minimal Residual Disease (MRD) is virtually always present and even in negative patients, the study of MRD is assessed only in the peripheral blood and bone marrow [49,50]. What happens in the spleen? In an Italian multicenter study [51], it has been demonstrated that in some HCL patients splenectomized after a documented CR obtained after a prolonged treatment with α -IFN, histology of the spleen revealed the persistence of the disease at that level.

Accordingly, the possibility to achieve the cure of the disease is very difficult. We need to improve our treatments as well as the approach to the detection of MRD. Probably, in the definition of CR we should include again the routine determination of serum soluble IL-2 Receptor because is universally accepted as a reliable tool which strictly correlate with the status of the disease [7,8,52] with the bulk of the disease [8,52], with the spleen involvement [8] and, in addition, may predict the relapse of the disease before absolute granulocyte count decrease [53].

In conclusion, despite the brilliant results achieved in the biology and treatment of HCL, paradoxically we need additional efforts in order to completely elucidate the biology of the disease, the role of MRD and the best approach for the cure of the disease limiting at maximum life-threatening risks.

References

- Bouroncle BA, Wiseman BK, Doan CA. Leukemic reticuloendotheliosis. *Blood*. 1958; 13: 609-630.
- Tiacci E, Trifonov V, Schiavoni G, Holmes A, Kern W, Martelli MP, et al. BRAF mutations in hairy-cell leukemia. *N Engl J Med*. 2011; 364: 2305-2315.
- Mintz U, Golomb HM. Splenectomy as initial therapy in twenty-six patients with leukemic reticuloendotheliosis (hairy cell leukemia). *Cancer Res*. 1979; 39: 2366-2370.
- Lauria F, Bagnara GP, Catani L, Gaggioli L, Guarini A, Raspadori D, et al. The inhibitory effect of serum from hairy-cell leukaemia patients on normal progenitor cells may disappear following prolonged treatment with alpha-interferon. *Br J Haematol*. 1989; 72: 497-501.
- Foa R, Guarini A, Francia di Celle P, Trentin L, Gillio Tos A, Bellone G, et al. Constitutive production of tumor necrosis factor- α in Hairy cell leukemia: possible role in the pathogenesis of the cytopenia(s) and effect of treatment with Interferon alfa. *J. ClinOncol*. 1992; 10: 954-959.
- Barak V, Nisman B, Polliack A. The tumor necrosis factor family and correlation with disease activity and response to treatment in hairy cell leukemia. *Eur J Haematol*. 1999; 62: 71-75.
- Chilosi M, Semenzato G, Cetto G, Ambrosetti A, Fiore-Donati L, Perona G, et al. Soluble Interleukin-2 receptor in the sera of patients with Hairy cell leukemia: relationship with the effect of recombinant γ -Interferon therapy on clinical parameters and natural killer in vitro activity. *Blood*. 1987; 70: 1530-1535.
- Lauria F, Rondelli D, Raspadori D, Zinzani PL, Benfenati D, Pileri S, et al. Serum soluble Interleukin-2 receptor levels in Hairy cell leukemia: Correlation with clinical and hematological parameters and with α -Interferon treatment. *Leukemia and Lymphoma*. 1991; 7: 103-107.
- Vedantham S, Gamliel H, Golomb HM. Mechanism of interferon action in hairy cell leukemia: a model of effective cancer biotherapy. *Cancer Res*. 1992; 52: 1056-1066.
- Platanias LC, Pfeffer LM, Barton KP, Vardiman JW, Golomb HM, Colamonic OR. Expression of the IFN alpha receptor in hairy cell leukaemia. *Br J Haematol*. 1992; 82: 541-546.
- Ahmed S, Rai KR. Interferon in the treatment of hairy-cell leukemia. *Best Pract Res Clin Haematol*. 2003; 16: 69-81.
- Quesada JR, Reuben J, Manning JT, Hersh EM, Gutterman JU. Alpha interferon for induction of remission in hairy-cell leukemia. *N Engl J Med*. 1984; 310: 15-18.
- Bardawil RG, Groves C, Ratain MJ, Golomb HM, Vardiman JW. Changes in peripheral blood and bone marrow specimens following therapy with recombinant alpha 2 interferon for hairy cell leukemia. *Am J Clin Pathol*. 1986; 85: 194-201.
- Lauria F, Foà R, Raspadori D, Zinzani PL, Buzzi M, Fierro MT, et al. Treatment of hairy-cell leukaemia with alpha-interferon (alpha-IFN). *Eur J Cancer Clin Oncol*. 1988; 24: 195-200.
- Foa R, Fierro MT, Lusso P, Bonferroni M, Raspadori D, Buzzi M, et al. Effect of alpha-interferon on the immune system of patients with hairy cell leukemia. *Leukemia*. 1987; 1: 377-379.
- Habermann TM, Andersen JW, Cassileth PA, Bennett JM, Oken MM. Sequential administration of recombinant interferon alpha and deoxycoformycin in the treatment of hairy cell leukaemia. *Br J Haematol*. 1992; 80: 466-471.
- Saven A, Piro L. Newer purine analogues for the treatment of hairy-cell leukemia. *N Engl J Med*. 1994; 330: 691-697.
- Johnston JB. Mechanism of action of pentostatin and cladribine in hairy cell leukemia. *Leuk Lymphoma*. 2011; 52: 43-45.
- Spiers AS, Moore D, Cassileth PA, Harrington DP, Cummings FJ, Neiman RS, et al. Remissions in hairy-cell leukemia with pentostatin (2'-deoxycoformycin). *N Engl J Med*. 1987; 316: 825-830.
- Kraut EH, Grever MR, Bouroncle BA. Long-term follow-up of patients with hairy cell leukemia after treatment with 2'-deoxycoformycin. *Blood*. 1994; 84: 4061-4063.
- Grever MR, Lozanski G. Modern strategies for hairy cell leukemia. *J Clin Oncol*. 2011; 29: 583-590.
- Else M, Dearden CE, Matutes E, Garcia-Talavera J, Rohatiner AZ, Johnson SA, et al. Long-term follow-up of 233 patients with hairy cell leukaemia, treated initially with pentostatin or cladribine, at a median of 16 years from diagnosis. *Br J Haematol*. 2009; 145: 733-740.
- Grever M, Kopecky K, Foucar MK, Head D, Bennett JM, Hutchison RE, et al. Randomized comparison of pentostatin versus interferon alfa-2a in previously untreated patients with hairy cell leukemia: an intergroup study. *J Clin Oncol*. 1995; 13: 974-982.
- Kraut EH, Neff JC, Bouroncle BA, Gochnour D, Grever MR. Immunosuppressive effects of pentostatin. *J Clin Oncol*. 1990; 8: 848-855.
- Flinn IW, Kopecky KJ, Foucar MK, Head D, Bennett JM, Hutchison R, et al. Long-term follow-up of remission duration, mortality, and second malignancies in hairy cell leukemia patients treated with pentostatin. *Blood*. 2000; 96: 2981-2986.
- Piro LD, Carrera CJ, Carson DA, Beutler E. Lasting remissions in hairy-cell leukemia induced by a single infusion of 2-chlorodeoxyadenosine. *N Engl J Med*. 1990; 322: 1117-1121.
- Saven A, Burian C, Koziol JA, Piro LD. Long-term follow-up of patients with hairy cell leukemia after cladribine treatment. *Blood*. 1998; 92: 1918-1926.
- Cheson BD, Sorensen JM, Vena DA, Montello MJ, Barrett JA, Damasio E, et al. Treatment of hairy cell leukemia with 2-chlorodeoxyadenosine via the Group C protocol mechanism of the National Cancer Institute: a report of 979 patients. *J Clin Oncol*. 1998; 16: 3007-3015.
- Hoffman MA, Janson D, Rose E, Rai KR. Treatment of hairy-cell leukemia with cladribine: response, toxicity, and long-term follow-up. *J Clin Oncol*. 1997; 15: 1138-1142.

30. Lauria F, Rondelli D, Zinzani PL, Bocchia M, Marotta G, Salvucci M, et al. Long-lasting complete remission in patients with hairy cell leukemia treated with 2-CdA: a 5-year survey. *Leukemia*. 1997; 11: 629-632.
31. Juliusson G, Samuelsson H; Swedish Lymphoma Registry. Hairy cell leukemia: epidemiology, pharmacokinetics of cladribine, and long-term follow-up of subcutaneous therapy. *Leuk Lymphoma*. 2011; 52: 46-49.
32. Lauria F, Bocchia M, Marotta G, Raspadori D, Zinzani PL, Rondelli D. Weekly administration of 2-chlorodeoxyadenosine in patients with hairy cell leukemia: a new treatment schedule effective and safer in preventing infectious complications. *Blood*. 1997; 89: 1838-1839.
33. Seymour JF, Kurzrock R, Freireich EJ, Estey EH. 2-chlorodeoxyadenosine induces durable remissions and prolonged suppression of CD4+ lymphocyte counts in patients with hairy cell leukemia. *Blood*. 1994; 83: 2906-2911.
34. Raspadori D, Rondelli D, Birtolo S, Lenoci M, Nardi G, Scalia G, et al. Long-lasting decrease of CD4+/CD45RA+ T cells in HCL patients after 2-chlorodeoxyadenosine (2-CdA) treatment. *Leukemia*. 1999; 13: 1254-1257.
35. Lauria F, Lenoci M, Annino L, Raspadori D, Marotta G, Bocchia M, et al. Efficacy of anti-CD20 monoclonal antibodies (Mabthera) in patients with progressed hairy cell leukemia. *Haematologica*. 2001; 86: 1046-1050.
36. Nieva J, Bethel K, Saven A. Phase 2 study of rituximab in the treatment of cladribine-failed patients with hairy cell leukemia. *Blood*. 2003; 102: 810-813.
37. Ravandi F, O'Brien S, Jorgensen J, Pierce S, Faderl S, Ferrajoli A, et al. Phase 2 study of cladribine followed by rituximab in patients with hairy cell leukemia. *Blood*. 2011; 118: 3818-3823.
38. Else M, Dearden CE, Matutes E, Forconi F, Lauria F, Ahmad H, et al. Rituximab with pentostatin or cladribine: an effective combination treatment for hairy cell leukemia after disease recurrence. *Leuk Lymphoma*. 2011; 52: 75-78.
39. Byrd JC, Brown JR, O'Brien S, Barrientos JC, Kay NE, Reddy NM, et al. Ibrutinib versus ofatumumab in previously treated chronic lymphoid leukemia. *N Engl J Med*. 2014; 371: 213-223.
40. Goede V, Fischer K, Busch R, Engelke A, Eichhorst B, Wendtner CM, et al. Obinutuzumab plus chlorambucil in patients with CLL and coexisting conditions. *N Engl J Med*. 2014; 370: 1101-1110.
41. Kreitman RJ, Wilson WH, White JD, Stetler-Stevenson M, Jaffe ES, Giardina S, et al. Phase I trial of recombinant immunotoxin anti-Tac(Fv)-PE38 (LMB-2) in patients with hematologic malignancies. *J Clin Oncol*. 2000; 18: 1622-1636.
42. Kreitman RJ, Stetler-Stevenson M, Margulies I, Noel P, Fitzgerald DJP, Wilson WH, et al. Phase II trial of recombinant immunotoxin RFB4(dsFv)-PE38 (BL22) in patients with B-cell malignancies. *J Clin Oncol*. 2009; 27: 2983-2990.
43. Kreitman RJ, Tallman MS, Robak T, Coutre S, Wilson WH, Stetler-Stevenson M, et al. Phase I trial of anti-CD22 recombinant immunotoxin moxetumomab pasudotox (CAT-8015 or HA22) in patients with hairy cell leukemia. *J Clin Oncol*. 2012; 30: 1822-1828.
44. Davies H, Bignell GR, Cox C, Stephens P, Edkins S, Clegg S, Teague J. Mutations of the BRAF gene in human cancer. *Nature*. 2002; 417: 949-954.
45. Pakneshan S, Salajegheh A, Smith RA, Lam AK. Clinicopathological relevance of BRAF mutations in human cancer. *Pathology*. 2013; 45: 346-356.
46. Tiaci E, DeCarolis L, Zinzani PL, Pulsoni A, Zaia F, Cimminiell M. Efficacy and safety of the BRAF inhibitor Vemurafenib in Hairy cell leukemia patients to or relapsed after purine analogs: A phase 2 Italian trial. *ASH 2014*.
47. Dietrich S, Glimm H, Andrusis M, von Kalle C, Ho AD, Zenz T. BRAF inhibition in refractory hairy-cell leukemia. *N Engl J Med*. 2012; 366: 2038-2040.
48. Sivina M, Kreitman RJ, Arons E, Ravandi F, Burger JA. The bruton tyrosine kinase inhibitor ibrutinib (PCI-32765) blocks hairy cell leukaemia survival, proliferation and B cell receptor signalling: a new therapeutic approach. *Br J Haematol*. 2014; 166: 177-188.
49. Lauria F, Foa R, Raspadori D, Pileri S, Tassinari A, Buzzi M, et al. Evaluation of complete remission in hairy cell leukemia patients treated with alpha-IFN. *Bone Marrow Transplant*. 1989; 4: 176-178.
50. Lauria F, Raspadori D, Benfenati D, Rondelli D, Pallotti A, Tura S. Biological markers and minimal residual disease in hairy cell leukemia. *Leukemia*. 1992; 6: 149-151.
51. Damasio EE, Federico M, Frassoldati A, Lamparelli T, Annino L, Bernasconi C, et al. Splenectomy after initial therapy with alpha-IFN in patients with Hairy-Cell Leukemia (HCL): a multi-center study by the Italian Cooperative Group for HCL. Preliminary results. *Eur. J. Hematol*. 1990; 45: 29-31.
52. Richards JM, Mick R, Latta JM, Daly K, Ratain MJ, Vardiman JW, et al. Serum soluble interleukin-2 receptor is associated with clinical and pathologic disease status in hairy cell leukemia. *Blood*. 1990; 76: 1941-1945.
53. Arun B, Curti BD, Longo DL, Stevens D, Alvord WG, Gause BL, et al. Elevations in serum soluble interleukin-2 receptor levels predict relapse in patients with hairy cell leukemia. *Cancer J Sci Am*. 2000; 6: 21-24.