

Case Presentation

A Case of Synchronous Rectal Cancer and Right Sided Colon Cancer Treated with Transvaginal NOSES Technique

Tiefeng Gu¹; Yujia Lin²; Hanqing Hu^{1*}; Guiyu Wang^{1*}¹Department of Colorectal Cancer Surgery, the Second Affiliated Hospital of Harbin Medical University, China²Department of General Surgery, the Second Affiliated Hospital of Harbin Medical University, China***Corresponding author: Guiyu Wang**

Hanqing Hu, Department of Colorectal Cancer Surgery, the Second Affiliated Hospital of Harbin Medical University, China.

Email: guiyuwang@hrbmu.edu.cn; huanqing@hrbmu.edu.cn

Received: July 17, 2023

Accepted: August 15, 2023

Published: August 22, 2023

Abstract

Introduction: We reported a 53 years old female patient with synchronous rectal cancer and right sided colon cancer who underwent transvaginal NOSES to resect two tumors with no serious postoperative complications.

Case report: The patient underwent electronic colonoscopy and found two lesions in the intestine, located in the right colon and rectum. Pathological examination confirmed that both lesions were malignant tumors, and the patient was diagnosed with concurrent colon and rectal cancer. After diagnosis, the patient underwent transvaginal NOSES, and the intraoperative exploration results were consistent with electronic colonoscopy. The surgery completely resected two malignant tumors at same time. The pathological report staging of right colon cancer is AJCC stage II (pT3N0M0), with moderately differentiated adenocarcinoma and negative circumferential margin. The pathological report staging of rectal cancer is AJCC stage III (pT2N1aM0), with moderately differentiated adenocarcinoma and negative circumferential margin. The patient recovered well after surgery and did not experience any serious postoperative complications. Patient receives XELOX chemotherapy after surgery.

Discussion: Transvaginal NOSES is a safe and effective surgical method for synchronous multiple primary colorectal cancer. However, due to the complexity of the surgery and the increased anesthesia risks associated with additional surgical time, experienced surgical and anesthesia teams are required.

Conclusion: The application of transvaginal NOSES in the treatment of synchronous multiple primary colorectal cancer is still in the exploratory stage, and more clinical studies are needed to prove its feasibility, safety, and effectiveness.

Keywords: Multiple primary cancer; Colorectal cancer; Transvaginal; NOSES

Introduction

Synchronous multiple primary colorectal cancer refers to two or more primary colorectal malignancies detected in the same patient simultaneously or within 6 months after the first medical examination. Its incidence is significantly related to habitual behaviors [1]. Compared to solitary colorectal cancer, concurrent colorectal cancer has a significantly worse prognosis [2]. Its incidence in primary colorectal cancer varies among studies [3-6]. Transvaginal NOSES has been recognized as a safe and effective form of surgery [7-9]. Here, we reported a case of synchronous multiple primary colorectal cancer curative resection with transvaginal NOSES.

Case Presentation

A 53 year old woman underwent electronic colonoscopy examination due to unexplained bloody stools. Electronic colonoscopy revealed two lesions. One lesion is located in the right colon, occupying the entire intestinal cavity, and the other lesion is located in the rectum, with a distance of about 8 cm from the anus and a extent of approximately 5×6 cm. Two lesions were pathologically reported as adenocarcinoma. The patient's computed tomography scan showed no distant metastasis. The preoperative staging of both lesions is cT3N0M0. The American Association of Anesthesiologists is rated II and BMI is 21.5Kg/m².

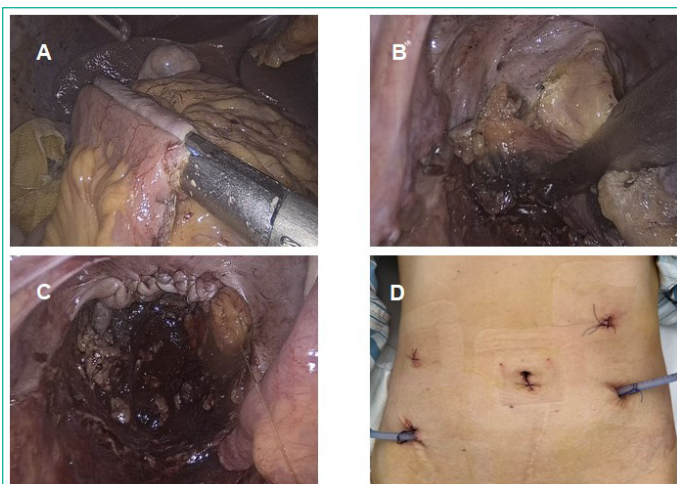


Figure 1: (a). Side-to-side overlapping anastomosis of the transverse colon and ileum (b). The resection of the rectum (c). Suture of vaginal incision D. Postoperative abdominal photos.

After a multidisciplinary comprehensive evaluation of the patient's condition and the location of two lesions, it was decided to use transvaginal NOSES as the surgical method. The patient underwent surgery on April 13, 2023.

During intraoperative exploration, two tumors were located in the right colon and rectum, consistent with the results of preoperative electronic colonoscopy. We first performed anatomical separation and resection of the right colon, also with mesenteric lymph nodes dissection. And then reconstructed the digestive tract of the right colon, the method is a side-to-side overlapping anastomosis of the transverse colon and ileum (Figure 1A). The excised right colon specimen is placed in a sterile protective sleeve and placed in the left upper abdomen. Afterwards, we aimed the laparoscopic camera at the pelvic cavity, performed anatomical separation and resection of the rectum with mesenteric lymph nodes dissection (Figure 1B). After resection, the assistant inserted iodine gauze through the vagina and supported the posterior wall of the vagina. The surgeon used Harmonic to cut open the posterior wall of the vagina, and the assistant used oval forceps to pull the sterile protective sleeve out of the body. Insert the oval forceps again through sterile protective sleeves and take out the right colon specimen. The assistant inserted the oval forceps again through a sterile protective sleeve, clamped the proximal rectal stump, and pulled the separated rectum out of the body. The rectum was cut 10 cm above the rectal tumor, and the head of the single stapling procedure was inserted into the proximal Sigmoid colon and returned to the abdominal cavity. After removing the sterile protective sleeve through the vagina, the surgeon sutured the incision on the posterior wall of the vagina (Figure 1C), the assistant placed a single stapling procedure through the anus to perform rectosigmoid anastomosis. No bleeding or leakage was found at the anastomotic site. The surgeon placed two drainage tubes at the lowest point of the pelvic cavity and the lower edge of the liver. After suturing the Trocar hole, the surgery was completed (Figure 1D).

The surgical time was 195 minutes, and the estimated intraoperative blood loss was 100ml. Patient resumed flatus 36 hours after surgery, and oral liquid diet was resumed on the 3rd day after surgery. The pathological report staging of right colon cancer was AJCC stage II (pT3N0M0), with moderately differentiated adenocarcinoma and negative circumferential margin. No positive lymph nodes were found in the 20 harvested lymph nodes. The pathological report staging of rectal cancer was

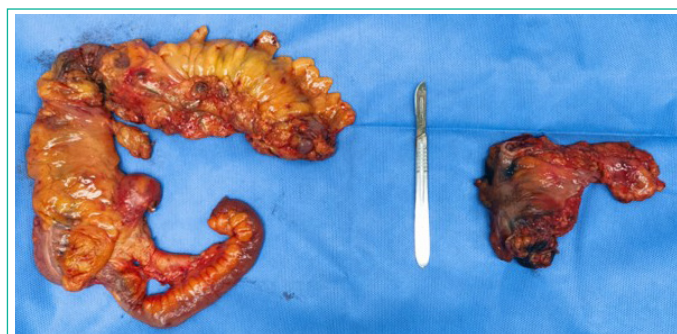

Figure 2: Right colon and rectal specimens.

AJCC stage III (PT2N1aM0), with moderately differentiated adenocarcinoma and negative circumferential margin. One positive lymph nodes was found in the 18 harvested lymph nodes (Figure 2).

The patient received XELOX adjuvant chemotherapy four weeks after surgery. Two months after surgery, the QLQ-C30 questionnaire showed good functional and symptom scores, and there were no related postoperative complications.

Discussion

For the diagnosis of synchronous multiple primary colorectal cancers, perioperative colonoscopy is crucial as it can determine the location and number of lesions [4]. The treatment strategy for patients with synchronous multiple primary colorectal should take into account the location of different primary lesions [10]. For this patient, preoperative colonoscopy revealed two lesions, and both of which were malignant tumors. The two lesions were located in the hepatic flexure of colon (65 cm from the anus) and rectum (8 cm from the anus). Based on these situations, the final surgical method determined for the female patient was transvaginal NOSES.

Our primary considerations are the safety and quality of the surgery. Compared with traditional laparoscopic colorectal cancer surgery, NOSES has a lower overall postoperative complication rate, and data such as postoperative anastomotic complications, intraperitoneal infection, pelvic floor function, intraoperative blood loss, lymph node clearance, 3-year disease-free and overall survival are not inferior to traditional laparoscopic surgery for colorectal cancer [8,9,11].

In this case, our surgical method is transvaginal NOSES. After laparoscopic resection of two tumors, the tumors were removed from the body through the vagina without an abdominal incision. Compared with the traditional laparoscopic surgery, we avoided incision infection and other related complications, meanwhile, patient had a shorter postoperative pain period, which is consistent with previous research results [12]. The patient did not develop complications such as anastomotic leakage or intraperitoneal infection after the surgery, indicating the safety of this surgery. The postoperative pathological results of the patient showed that the circumferential margins (including the upper and lower margins) of both tumor specimens were negative, indicating that the two lesions were completely resected during this procedure, fitting the principle of an-neoplasia surgical operation. These all indicate that this surgery technique is of high quality and safe.

There are still some challenges to this surgery. Due to the circumferential diameter of both tumors is over 3 cm, we chose the vagina for specimen removal, which increases the risk of postoperative vaginal fistula. In addition, the operation removed two malignant tumors at the same time, cleared abdom-

inal and pelvic lymph nodes, performed side to side anastomosis of Transverse colon and ileum and end-to-end anastomosis of rectum and Sigmoid colon, which lead to the prolongation of the operation time and increasing anesthesia risks. Therefore, similar surgeries require experienced surgical and anesthesia teams. We recommend similar surgeries for suitable patients in qualified medical centers.

Conclusion

Transvaginal NOSES has been proven to be a safe and effective method for the treatment of colorectal cancer, the incidence of postoperative complications is comparable to transanal NOSES and lower than traditional laparoscopic surgery [13]. In this case, the effect of transvaginal NOSES treatment for simultaneous colorectal cancer is excellent, with no serious postoperative complications and guaranteed surgical quality. However, the current implementation of this surgery is still in the exploratory stage, and more clinical studies are needed to prove its feasibility, safety, and effectiveness.

Author Statements

Acknowledgements

This work is supported by National Natural Foundation of Science (grant number: 8210303 and 62276084) and Marshal Initiative Funding (grant number: HMUMIF-22004).

References

1. Kuo YH, Hung HY, You JF, Chiang JM, Chin CC. Common habitual behaviors and synchronous colorectal cancer risk: a retrospective case-control study. *Int J Colorectal Dis.* 2019; 34: 1421-30.
2. Chin CC, Kuo YH, Chiang JM. Synchronous colorectal carcinoma: predisposing factors and characteristics. *Colorectal Dis.* 2019; 21: 432-40.
3. Samadder NJ, Curtin K, Wong J, Tuohy TM, Mineau GP, Smith KR, et al. Epidemiology and familial risk of synchronous and metachronous colorectal cancer: a population-based study in Utah. *Clin Gastroenterol Hepatol.* 2014; 12: 2078-84.e1.
4. Kato T, Alonso S, Muto Y, Noda H, Miyakura Y, Suzuki K, et al. Clinical characteristics of synchronous colorectal cancers in Japan. *World J Surg Oncol.* 2016; 14: 272.
5. Lam AK, Chan SS, Leung M. Synchronous colorectal cancer: clinical, pathological and molecular implications. *World J Gastroenterol.* 2014; 20: 6815-20.
6. Huang CS, Yang SH, Lin CC, et al. Synchronous and metachronous colorectal cancers: distinct disease entities or different disease courses? *Hepato-Gastroenterology.* 2015; 62: 838-42.
7. Brincat SD, Lauri J, Cini C. Natural orifice versus transabdominal specimen extraction in laparoscopic surgery for colorectal cancer: meta-analysis. *BJS Open.* 2022; 6: zrac074.
8. Wang S, Tang J, Sun W, Yao H, Li Z. The natural orifice specimen extraction surgery compared with conventional laparoscopy for colorectal cancer: A meta-analysis of efficacy and long-term oncological outcomes. *Int J Surg.* 2022; 97: 106196.
9. Tang Q, Zhu Y, Xiong H, Sheng X, Hu Z, Hu H, et al. Natural Orifice Specimen Extraction Surgery versus Conventional Laparoscopic-Assisted Resection in the Treatment of Colorectal Cancer: A Propensity-Score Matching Study. *Cancer Manag Res.* 2021; 13: 2247-57.
10. Lee BC, Yu CS, Kim J, Lee JL, Kim CW, Yoon YS, et al. Clinicopathological features and surgical options for synchronous colorectal cancer. *Med (Baltim).* 2017; 96: e6224.
11. Lin J, Lin S, Chen Z, Zheng B, Lin Y, Zheng Y, et al. Meta-analysis of natural orifice specimen extraction versus conventional laparoscopy for colorectal cancer. *Langenbecks Arch Surg.* 2021; 406: 283-99.
12. Hisada M, Katsumata K, Ishizaki T, Enomoto M, Matsudo T, Kasuya K, et al. Complete laparoscopic resection of the rectum using natural orifice specimen extraction. *World J Gastroenterol.* 2014; 20: 16707-13.
13. Franklin ME, Jr., Liang S, Russek K. Natural orifice specimen extraction in laparoscopic colorectal surgery: transanal and transvaginal approaches. *Tech Coloproctol.* 2013; 17: S63-7.