

Case Report

A Pediatric Case of Chronic Immune Thrombocytopenic Purpura Treated with Sirolimus

Wenliang Geng¹ and Guillermo de Angulo^{2*}¹Department of Pediatrics, Miami Children's Hospital, US²Department of Pediatric Hematology and Oncology, Miami Children's Hospital, US

***Corresponding author:** Guillermo de Angulo, Department of Pediatric Hematology/Oncology, Miami Children's Hospital, 3100 SW 62nd Avenue #121, Miami, FL 33155, Florida, US, Tel: 301662-8360; Fax: 305666-6387; Email: guillermo.deangulo@mch.com

Received: August 21, 2014; **Accepted:** September 15, 2014; **Published:** September 18, 2014

Abstract

Few pediatric patients with Immune Thrombocytopenic Purpura (ITP) continue to have low platelets despite treatment with pooled gamma globulin (IVIg), corticosteroids, and anti-D immunoglobulin. Sirolimus (previously known as rapamycin) is an mTOR inhibitor that may improve platelet counts for this subset of patients. Here we present a pediatric case of chronic ITP refractory to first-line pharmacotherapy. Following treatment with sirolimus, our patient's average platelet count increased from $41.9 \times 10^9/L$ to $264.4 \times 10^9/L$ ($P=6.7 \times 10^{-6}$). Furthermore, she experienced resolution of her bleeding symptoms without encountering side-effects related to treatment.

Keywords: ITP; Pediatric; Purpura; Rapamycin; Sirolimus; Thrombocytopenia

Introduction

A patient with immune thrombocytopenic purpura has chronic disease when the platelet count remains below $150 \times 10^9/L$ beyond six months and is refractory to treatment [1]. This condition affects 10% to 30% of patients with ITP and is more common in females as well as patients with detectable anti-platelet antibodies [2-4]. Despite the persistent thrombocytopenia, current literature suggests that chronic ITP is a self-limited and asymptomatic condition that rarely results in significant bleeding problems and often resolves with conservative management alone [4]. Pharmacologic treatment may be indicated in patients with clinically significant thrombocytopenia characterized by severe bleeding symptoms [3].

Options for first line treatment of ITP include IVIG, corticosteroids, and (for Rh+ patients) anti-D immunoglobulin [5-7]. Prior to the past decade, those who were refractory to medical management were referred for splenectomy, which rendered the immune system vulnerable to infection by encapsulated bacteria. More recently, Bennett, et al. pioneered the use of rituximab, an anti-CD20 monoclonal antibody, for the successful treatment of refractory ITP [8]. Other immune-modulating agents are also currently being evaluated as viable second line treatment modalities.

Sirolimus is an immune-modulating agent that interferes with T and B cell proliferation by inhibiting the mammalian target of rapamycin (mTOR) pathway. By an unclear mechanism, it is thought to promote the regulatory $CD4^+CD25^+FoxP3^+T$ -lymphocytes (T_{reg}), which are responsible for energy and frequently depleted in autoimmune diseases [9,10]. Sirolimus has been used successfully for the treatment of thrombocytopenia in the setting of autoimmune lymphoproliferative syndrome (ALPS) [11], and we believe may be effective for ITP as well. Although sparse evidence exists supporting its utility in the management of ITP, however there is increasing data that hint at its effectiveness in treating ITP in the adult population [12]. Here we present our observations from a pediatric case where sirolimus was used off-label for the treatment of chronic refractory ITP.

Case Presentation

Our patient was a 15 year old female who presented with ecchymoses, petechiae, and easy bruising. Her complete blood count (CBC) revealed a platelet count of $3 \times 10^9/L$. She was diagnosed with ITP and treated immediately with two rounds of IVIG. Her platelet count improved to $121 \times 10^9/L$ but steadily decreased following hospital discharge. She also developed pseudotumor cerebri attributed to IVIG, and was subsequently treated with two doses of anti-D immune globulin. Despite all initial efforts her thrombocytopenia persisted.

Three years after diagnosis, our patient was hospitalized due to menorrhagia accompanied by a platelet count of $4.0 \times 10^9/L$. She received another dose of IVIG followed by a course of low potency corticosteroids; however, her low platelet count was again refractory. The option for immunotherapy with rituximab was considered and subsequently refused by the patient and her family. After careful discussion of risks and benefits, the patient chose to begin off-label treatment with a course of sirolimus, which was initiated shortly after her hospitalization.

The treatment regimen consisted of a single 6 mg sirolimus loading dose followed by 4 mg daily. The daily dose was tapered by 1 mg every 6 weeks, totaling 24 weeks of therapy prior to discontinuation. All doses were self-administered orally. Complete blood count and routine side effect screening was performed at each subsequent follow-up clinic visit.

Discussion

A two-sample t-test comparison of the average platelet count using all data available before treatment ($41.9 \times 10^9/L$) and after treatment ($264.4 \times 10^9/L$) showed a seven-fold increase in the average platelet count ($p=6.7 \times 10^{-6}$) following administration of sirolimus (Figure 1). Furthermore, the pre-treatment average includes data during which the patient received IVIG, anti-D immunoglobulin, and steroids, suggesting a pre-treatment baseline that is lower and thus a more prominent therapeutic response.

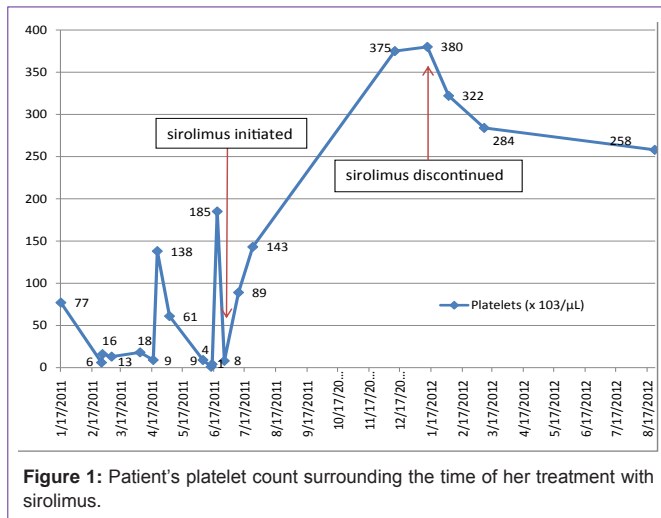


Figure 1: Patient's platelet count surrounding the time of her treatment with sirolimus.

Consideration of treatment with immune modulating medications necessitates a discussion of potential side effects. Sirolimus shares a side effect profile with other immunosuppressive agents. Laboratory values may reflect a combination of anemia, leukopenia, and thrombocytopenia. Additionally, transient elevations in serum transaminases have been described [7]. Symptomatically, patients may develop fevers, rash, GI disturbances, and mucositis [10,13-15]. One of the most important considerations when placing patients on immune modulating agents is increased susceptibility to infection. Leukopenia and neutropenia are non-dose dependent side-effects of sirolimus therapy [13]. Neutropenia was not seen during our patient's treatment course, nor did she have any documented sirolimus-related gastrointestinal complaints. Monitoring CBCs was sufficiently suitable considering the tolerability of sirolimus at low doses [11], and sirolimus levels were not obtained as the dose was further tapered.

In one of the earliest studies of the side-effect profile, thrombocytopenia was observed in the majority of patients, with an average drop in platelets of 29% 15 days after initiating therapy [13]; however, the severity of thrombocytopenia was dose-dependent. The underlying pathogenesis of ITP is destruction of platelets caused by an overactive immune system. We believe through mTOR inhibition-mediated suppression and modification of the autoimmune response to circulating platelets, sirolimus is able to improve the platelet count in chronic ITP rather than exacerbating the underlying thrombocytopenia.

In addition to safety and efficacy, cost and convenience are becoming increasingly important in today's health care environment. Immune globulins (IVIG, anti-D immune globulin, rituximab) require intravenous delivery, usually in a healthcare facility capable of monitoring for immediate side effects. The additional cost of skilled nursing, frequency of hypersensitivity reactions, and possible need of hospitalization should be considered. Sirolimus can be taken in pill form and in the comfort of the home setting, whereas rituximab requires four infusions given at once weekly intervals. The convenience and ease of once-daily dosing is likely to result in excellent patient compliance.

Conclusion

Management of chronic refractory ITP in the pediatric population poses many challenges. Identifying a suitable treatment option requires a case by case assessment of illness severity, patient comorbidities, desired outcomes, and economic cost. There is an obvious need for prospective studies and randomized controlled trials to confirm our findings and broaden its application. Further inquiry may confirm that pediatric patients with chronic ITP refractory to first-line medical management may benefit from treatment with sirolimus.

References

- Rosthøj S, Rajantie J, Treutiger I, Zeller B, Tedgård U, Henter JI, NOPHO ITP Working Group. Duration and morbidity of chronic immune thrombocytopenic purpura in children: five-year follow-up of a Nordic cohort. *Acta Paediatr.* 2012; 101: 761-766.
- Blanchette V, Bolton-Maggs P. Childhood immune thrombocytopenic purpura: diagnosis and management. *Hematol Oncol Clin North Am.* 2010; 24: 249-273.
- Bennett Carolyn M, Michael Tarantino. "Chronic immune thrombocytopenia in children: epidemiology and clinical presentation." *Hematology/oncology clinics of North America.* 2009; 23: 1223-1238.
- Buchanan GR, Adix L. Current challenges in the management of children with idiopathic thrombocytopenic purpura. *Pediatr Blood Cancer.* 2006; 47: 681-684.
- Beck CE, Nathan PC, Parkin PC, Blanchette VS, Macarthur C. "Corticosteroids versus intravenous immune globulin for the treatment of acute immune thrombocytopenic purpura in children: a systematic review and meta-analysis of randomized controlled trials." *The journal of pediatrics.* 2005; 147: 521-527.
- Qin YH, Zhou TB, Su LN, Lei FY, Zhao YJ, Huang WF. "The efficacy of different dose intravenous immunoglobulin in treating acute idiopathic thrombocytopenic purpura: a meta-analysis of 13 randomized controlled trials." *Blood coagulation & fibrinolysis.* 2010; 21: 713-721.
- Freiberg A, Mauger D. Efficacy, safety and dose response of intravenous anti-D immune globulin (WinRho SDF) for the treatment of idiopathic thrombocytopenic purpura in children. *Semin Hematol.* 1998; 35: 23-27.
- Bennett CM, Rogers ZR, Kinnamon DD, Bussel JB, Mahoney DH, Abshire TC, et al. Prospective phase 1/2 study of rituximab in childhood and adolescent chronic immune thrombocytopenic purpura. *Blood.* 2006; 107: 2639-2642.
- Procaccini C, De Rosa V, Galgani M, Abanni L, Cali G, Porcellini A, et al. An oscillatory switch in mTOR kinase activity sets regulatory T cell responsiveness. *Immunity.* 2010; 33: 929-941.
- Chong BH. ITP: Tregs come to the rescue. *Blood.* 2010; 116: 4388-4390.
- Breakey VR, Blanchette VS. Childhood immune thrombocytopenia: a changing therapeutic landscape. *Semin Thromb Hemost.* 2011; 37: 745-755.
- Li J, Wang Z, Dai L, Cao L, Su J, Zhu M, et al. Effects of rapamycin combined with low dose prednisone in patients with chronic immune thrombocytopenia. *Clin Dev Immunol.* 2013; 2013: 548085.
- Tejani A, Alexander S, Ettenger R, Lerner G, Zimmerman J, Kohaut E, et al. "Safety and pharmacokinetics of ascending single doses of sirolimus (Rapamune, rapamycin) in pediatric patients with stable chronic renal failure undergoing dialysis." *Pediatric transplantation.* 2004; 8: 151-160.
- Murgia MG, Jordan S, Kahan BD. "The side effect profile of sirolimus: a phase I study in quiescent cyclosporine-prednisone-treated renal transplant patients." *Kidney international.* 1996; 49: 209-216.
- McCormack FX, Inoue Y, Moss J, Singer LG, Strange C, Nakata K, et al. Efficacy and safety of sirolimus in lymphangiomyomatosis. *N Engl J Med.* 2011; 364: 1595-1606.