

Research Article

Predicting MDM2 Amplification in Well-Differentiated Liposarcomas

Tran V^{1*}, Slavina J⁴, Spelman T^{1,5}, May D³ and Choong PFM^{1,2,3}

¹Department of Surgery, Melbourne Medical School, University of Melbourne, Melbourne, Victoria, Australia

²Bone and Soft Tissue Sarcoma Service, Peter MacCallum Cancer Centre, Melbourne, Victoria, Australia

³Department of Orthopaedics, St. Vincent's Hospital, Melbourne, Victoria, Australia

⁴Department of Anatomical Pathology, St. Vincent's Hospital, Melbourne, Victoria, Australia

⁵Karolinska Institute, Stockholm, Sweden

*Corresponding author: Vanessa Tran, Department of Surgery, Melbourne Medical School, University of Melbourne, Melbourne, Victoria, Australia

Received: November 01, 2021; Accepted: November 25, 2021; Published: December 02, 2021

Abstract

Background: Well-Differentiated Liposarcoma (WDLPS) is the most common subtype of malignant lipomatous tumours. This low-grade neoplasm carries a risk of local recurrence and dedifferentiation into higher-grade subtypes, and therefore requires aggressive treatment with wide local excision and neoadjuvant radiotherapy. WDLPS, however, shares overlapping features with its benign counterpart, lipoma. Diagnostically challenging cases can be resolved with molecular testing for Mouse Double Minute 2 (MDM2) amplification, which is found in almost all WDLPS. This study aimed to determine the predictors of MDM2 amplification to better inform the decision for tumours to undergo molecular testing.

Methods: A retrospective study was performed on 173 lipomatous tumours. Demographic, clinical, radiology and pathology data were obtained from institutional records. Multivariate analysis was performed to determine the features of lipomatous tumours that correlate with MDM2 amplification. The relative strength of the associations between predictor variables and MDM2 amplification were measured via derivation of coefficients of determination (Pseudo-R²).

Results: The significant predictors of MDM2 amplification were age of diagnosis ≥ 60 years (odds ratio (OR)=25.71; 95% confidence interval (CI)=4.47-148.02); size ≥ 15 cm (OR=11.68; 95% CI=2.70-50.59); presence of thick septa (OR=78.13; 95% CI=3.23-1890.71) on MRI; variable cell morphology (OR=22.19; 95% CI=4.03-122.20); and cytological atypia (OR=15.03; 95% CI=3.07-73.68).

Conclusion: Molecular testing for MDM2 amplification should be considered for tumours 15cm or greater, in patients aged 60 years or older, with thick septa on MRI, even in the absence of concerning histological features.

Keywords: Lipoma; Well-differentiated liposarcoma; MDM2 amplification; Molecular genetics

Abbreviations

CI: Confidence Interval; FISH: Fluorescence *In Situ* Hybridization; MDM2: Mouse Double Minute 2; OR: Odds Ratio; WDLPS: Well-Differentiated Liposarcoma

Introduction

Well-Differentiated Liposarcoma (WDLPS) is the most common liposarcoma subtype, accounting for almost half of all liposarcomas [1,2]. These often arise in the extremities and retroperitoneum, though are also found in the spermatic cord, mediastinum, and head and neck regions [1]. WDLPS are low-grade malignant tumours characterized by the predominance of mature adipocytes of variable size with fibrous septa containing atypical spindle cells. While these tumours lack metastatic potential, WDLPS carry a risk of local recurrence or dedifferentiation into a higher-grade subtype, namely DDLPS [3,4]. Importantly, WDLPS may be mistaken for a simple lipoma and treated in a suboptimal fashion. Identification of WDLPS is therefore important to provide adequate treatment and prevent local recurrence.

Molecular cytogenetic analysis is increasingly recognized as a valuable diagnostic tool for soft tissue sarcomas, given the many overlapping histological features and presence of characteristic genetic aberrations [5]. It is well recognized that WDLPS harbour characteristic amplified sequences of the chromosomal 12q13-15 region. This region almost invariably contains the Mouse Double Minute 2 (MDM2) gene, which is subsequently also amplified. Previously, amplification of this region was detected by the presence of supernumerary ring or marker chromosomes in conventional karyotyping, which were surrogate representations of the amplified sequence. More recently, Fluorescence *In Situ* Hybridization (FISH) has been interrogated as an accurate tool in the identification of MDM2 amplification. The use of FISH in distinguishing WDLPS from lipoma has yielded a sensitivity and specificity of up to 100% in several studies [6-8]. The characterization of MDM2 amplification in WDLPS has proven particularly useful in histologically challenging cases. A retrospective analysis by de Vreeze et al. found that incorporation of cytogenetic analysis in the diagnosis of lipoma and liposarcoma can change the diagnosis in up to 26% of cases [9]. Further studies have also reported that the addition of MDM2

amplification testing may lead to the reclassification of WDLPS and lipomas, which were previously diagnosed based on histology alone [7,10,11]. In the era of precision diagnostics, molecular testing has proven to be a valuable diagnostic tool.

This study interrogated the impact of MDM2 amplification testing on diagnosis of WDLPS and investigated the clinical, radiological, and histological features of lipomatous tumours that predict MDM2 amplification. Knowledge of these features and their relevance to WDLPS will allow clinicians to risk stratify lipomatous tumours and make more informed decisions about molecular testing.

Methods

A retrospective study was conducted on all patients diagnosed with lipoma or WDLPS at St Vincent's Hospital Melbourne (SVHM) and St Vincent's Private Hospital Melbourne (SVPHM). This study received ethics approval from the Research Governance at both hospitals (LRR 064/20 and P009/20). This was a retrospective analysis of institutional data without patient contact and informed consent was therefore not required.

Tumours

There were 544 consecutive tumours diagnosed as lipoma or WDLPS between 1997 and 2019 at SVHM and SVPHM. Of these, 182 tumours from 176 patients underwent FISH testing for MDM2 amplification. Local recurrences were counted as a separate diagnosis. The inclusion criteria for statistical analysis were a diagnosis of lipoma or WDLPS; and testing for MDM2 amplification by FISH. Tumours, which did not undergo MDM2 amplification testing, and local recurrences were excluded from the final analysis.

Diagnosis

SVHM is part of the Victorian Sarcoma Service, a collaborative tertiary referral service that provides comprehensive multidisciplinary bone and soft tissue cancer care to patients across Australia. All patients in this study were primarily managed in a multidisciplinary oncology team setting. Pathology specimens were examined by a specialist sarcoma pathologist and FISH testing for MDM2 amplification was performed by a cytogeneticist at the single institution. As part of the diagnostic workup, all patients underwent MRI with contrast studies and a CT-guided biopsy to obtain a pathological diagnosis. Some patients also underwent thallium scan, which was an investigative decision guided by the treating clinician. Resected tumours were also sent to pathology for confirmation of the diagnosis.

From January 2014, testing for MDM2 amplification by FISH was conducted at SVHM for lipomatous tumours suspected of malignancy to differentiate between a diagnosis of lipoma and WDLPS. The decision to test samples was guided by a senior sarcoma pathologist and was performed to (a) confirm a diagnosis of WDLPS or (b) to differentiate WDLPS from lipoma in histologically equivocal cases.

Treatment

The decision for surgical management was variable and guided by the diagnosis. Patients with a diagnosis of WDLPS in the extremities or trunk received neoadjuvant radiotherapy and excision of the tumour with wide margins. Those with WDLPS located in the head and neck or retroperitoneum received neoadjuvant radiotherapy and marginal excision of the tumour. Patients with a diagnosis of

lipoma were offered marginal excision without radiotherapy. Surgical margins were classified according to the Enneking staging system (intralesional, marginal, wide, radical) [12].

Clinical, radiological, and histological predictors

Demographic, clinical, radiological, and histological features were collected from online medical records. In classifying the site of the tumour, lower limb referred to the thigh, leg and foot; upper limb referred to the axilla, arm, forearm and hand; pelvis referred to the groin, scrotum, pelvis and buttock; and trunk referred to the chest wall and abdominal wall. The retroperitoneum and intra-abdominal site remained separate. Radiological features were collected from pre-operative, pre-radiotherapy MRI scans and thallium scan reports. Histological features were obtained from pathology reports of the resected specimen, where available, or the biopsy specimen. MDM2 amplification status was obtained from the molecular cytogenetics database. Patient follow up information was also obtained, including any local recurrence, the date of last review, and last known survival status.

Impact of MDM2 amplification on diagnosis and local recurrence

The number of diagnoses and local recurrences of lipoma and well-differentiated liposarcoma were stratified according to year. A cut off at January 2014 was used to divide cases into those before and after the introduction of MDM2 amplification testing at SVHM and SVPHM. The number of MDM2 amplification tests performed each year was also recorded.

Statistical analysis for predictors of MDM2 amplification

Categorical outcomes were summarised using frequency and percentages. Continuous variables were presented as mean and Standard Deviation (SD) or median and Interquartile Range (IQR), as appropriate. Univariable and multivariate logistic regression were used to investigate the correlation between MDM2 amplification and demographic information, clinical features, radiological features, and histological features. As individual patients were permitted to contribute multiple tumours to the analysis, the tumour was used as the statistical unit of the analysis with the logistic regression clustered at the level of the patient. Selection of baseline covariates as independent variables in the model was based on the univariate p value < 0.05 in addition to clinical relevance. Overall goodness-of-fit of the adjusted models were assessed using a Hosmer & Lemeshow model.

The relative strength of the associations between predictor variables and MDM2 amplification were measured via derivation of coefficients of determination (Pseudo-R²) for each regression model, with higher coefficients of determination representing greater correlation between an explanatory variable and the MDM2 amplification outcome. All analyses were conducted in R version 3.6.3 (R Foundation for Statistical Computing, Vienna, Austria).

Results

Between 1997 and 2019 a total 544 cases comprising of 477 lipomas and 67 WDLPS were identified. Within this group, 182 cases were tested for MDM2 amplification by FISH, resulting in a diagnosis of 134 lipomas and 48 WDLPS. 139 samples were negative, and 43 samples were positive for MDM2 amplification. Notably, 5 cases were

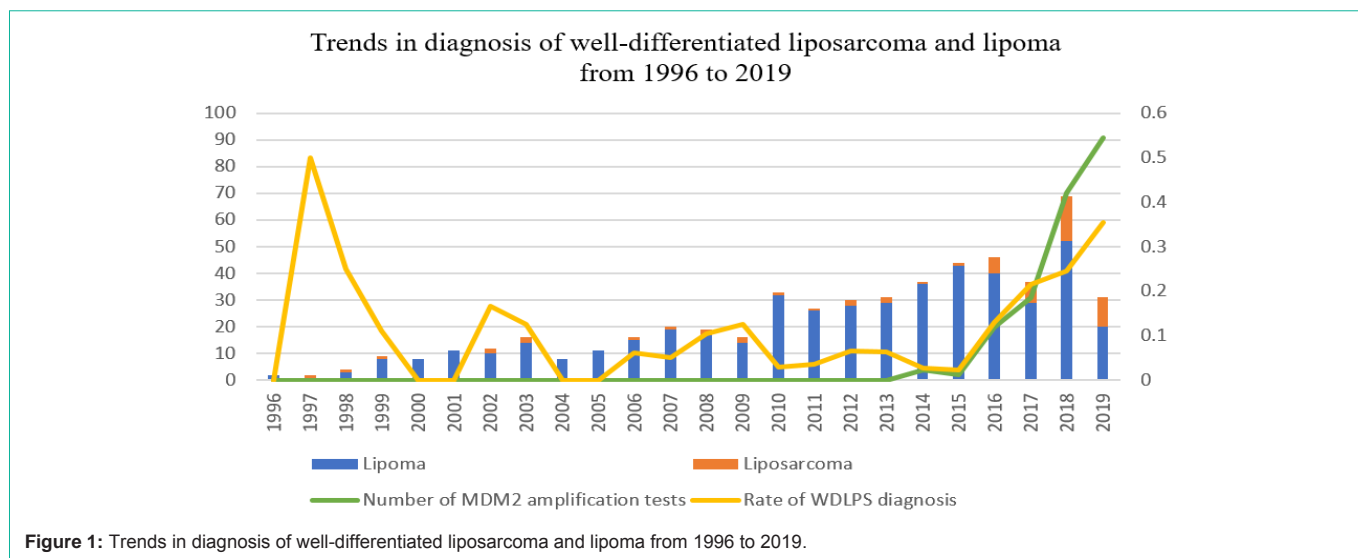


Figure 1: Trends in diagnosis of well-differentiated liposarcoma and lipoma from 1996 to 2019.

Table 1: Number of diagnoses and local recurrences before and after the introduction of MDM2 amplification testing.

	Before January 2014	After January 2014	Total
Diagnosis			
Lipoma	257	220	477
WDLPS	19	48	67
Total diagnosed	276	268	544
Local recurrences			
Lipoma	12	2	14
WDLPS	3	1	4
Total local recurrences	15	3	18

WDLPS: Well Differentiated Liposarcoma.

diagnosed as WDLPS despite a negative MDM2 amplification result.

Trend of WDLPS diagnosis and local recurrence rates

The cases were divided temporally with a cut-off on 1st January 2014, being the time point at which FISH testing for MDM2 amplification was introduced (Table 1). Prior to 2014, the rate of diagnosis of WDLPS was 19 in 276 lipomatous tumours (6.884%). This increased to 48 WDLPS in 268 lipomatous tumours (17.910%) following the introduction of MDM2 amplification testing (Figure 1). The rate of local recurrences of lipomas prior to 2014 was 12 in 256 lipomas (4.688%). This decreased to 2 in 220 lipomas (0.909%) after 2014.

MDM2 amplified tumours

173 tumours, which underwent MDM2 amplification at diagnosis, after excluding local recurrences, were excluded. There were 42 cases of MDM2 amplification (Table 2). The most common site of occurrence was the lower limb (n = 83). Imaging and histological features are detailed in Table 3. There were three local recurrences in total, of which two were lipomas and one was WDLPS. One patient died due to causes unrelated to WDLPS.

Predictors of MDM2 amplification

Multivariate logistic regression analyses were conducted based on the results of the univariate analysis (Table 4 and 5). Patients aged

Table 2: Baseline characteristics based on MDM2 amplification status.

Variable	MDM2 + (n = 42)	MDM2 - (n = 131)	Total (n = 173)
Gender			
Female	20	68	88
Male	22	63	85
Age at diagnosis (mean, SD)	52.89, 13.57	60.78, 13.05	
Site			
Head and neck	1	7	8
Trunk	3	23	26
Pelvis	0	5	5
Upper limb	3	41	44
Lower limb	32	51	83
Retroperitoneal	2	4	6
Intra-abdominal	1	0	1
Size (cm; mean, SD)	117.90, 68.52	121.07, 61.66	
Size ≥ 15cm	13	30	43
Size < 15cm	28	86	114
Compartment			
Intracompartment	33	104	137
Extracompartment	6	10	16
Depth			
Superficial	0	18	18
Deep	39	96	135
Soft tissue location			
Subcutaneous	19	50	69
Intramuscular	20	64	84

SD: Standard Deviation.

60 years or older were significantly associated with increased risk of MDM2 amplification (odds ratio (OR) = 25.71; 95% confidence interval (CI) = 4.47 - 148.02). A tumour size of 15cm or greater was associated with 11.682 times the odds of MDM2 amplification (CI = 2.70 - 50.57). On MRI, thick septation (OR = 78.13; CI = 3.23 -

Table 3: Imaging and histological characteristics stratified by MDM2 amplification status.

Variable	MDM2 + (n=43)	MDM2 - (n=139)	Total
Imaging characteristics			
Septation			
Thick	6	3	9
Thin	27	49	76
Not present	2	39	41
Nodules			
Present	8	7	15
Not present	28	89	117
Fat content			
Completely fatty	20	81	101
Heterogeneous	16	16	32
Signal intensity			
Increased	16	15	31
Not increased	19	82	101
Contrast enhancement			
Present	35	32	67
Not present	1	64	65
Thallium at 30 minutes			
Moderate-marked uptake	2	1	3
Mild uptake	2	5	7
No uptake	22	59	81
Thallium at 4 hours			
Moderate-marked uptake	0	2	2
Mild uptake	6	3	9
No uptake	20	60	80
Histology characteristics			
Cell morphology			
Variable	23	11	34
Uniform	8	101	109
Atypical nuclei			
Present	15	12	27
Not present	26	116	142
Cytologic atypia			
Present	23	7	30
Not present	11	121	132
Fibrous septa			
Present	31	45	76
Not present	11	83	94
Atypia within septa			
Present	25	5	30
Not present	17	123	140
Lipoblasts			
Present	4	2	6
Not present	38	126	164

Table 4: Univariate analysis of predictors for MDM2 amplification.

Variable	OR	95% CI	p-value
Clinical characteristics			
Age ≥ 60 years	6.06	2.603 - 14.109	< 0.001
Site (relative to lower limb)			
Head and neck	0.228	0.027 - 1.938	0.176
Trunk	0.208	0.058 - 0.749	0.016
Pelvis	*		
Upper limb	0.117	0.033 - 0.408	0.001
Lower limb	*		
Retroperitoneal	0.797	0.138 - 4.604	0.8
Intra-abdominal	*		
Size ≥ 15 cm	5.345	2.539 - 11.252	<0.001
Extracompartment (relative to intracompartment)	1.891	0.639 - 5.597	0.25
Intramuscular (relative to subcutaneous)	0.822	0.397 - 1.704	0.599
Imaging characteristics			
Septation			
Thick	49	5.358 - 283.863	<0.001
Thin	10.745	2.406 - 47.993	0.002
Nodules	3.633	1.210 - 10.910	0.022
Completely fatty (relative to solid/amorphous)	0.247	0.106 - 0.577	0.001
Contrast enhancement	70	9.170 - 534.349	<0.001
Thallium 30 minutes			
Moderate-marked uptake	5.364	0.463 - 62.148	0.179
Mild uptake	1.073	0.194 - 5.939	0.936
Thallium 4 hours			
Moderate-marked uptake	*		
Mild uptake	6	1.372 - 26.237	0.017
Histology characteristics			
Variable cell morphology	26.398	9.547 - 72.993	<0.001
Atypical nuclei	5.577	2.336 - 13.313	<0.001
Cytologic atypia	20.925	7.896 - 55.450	<0.001
Fibrous septa	5.198	2.388 - 11.313	<0.001
Atypia within septa	36.176	12.213 - 107.157	<0.001
Lipoblasts	6.632	1.169 - 37.620	0.033

OR: Odds Ratio; CI: Confidence Interval. Significant values (p < 0.05) are in bold. *Unable to derive OR due to zero cases in this group.

1890.71) was significantly associated with MDM2 amplification. Histological features that were associated with MDM2 amplification were variable cell size and shape (OR = 22.19; CI = 4.03 - 122.20) and presence of atypical cells (OR = 15.03; CI = 3.07 - 73.68) but not the presence of lipoblasts.

Strength of predictors

Pseudo-R² values were calculated for independent predictors and predictor combinations (Table 6 and 7). Cytologic atypia demonstrated the highest Pseudo-R² value (Pseudo-R² = 0.31),

Table 5: Multivariate analysis of predictors for MDM2 amplification.

Variable	OR	95% CI	p-value
Clinical characteristics			
Age ≥ 60 years	25.709	4.465-148.020	<0.001
Size ≥ 15cm	11.682	2.699 – 50.568	0.001
Imaging characteristics			
Septation			
Thick	78.125	3.228-1890.712	0.007
Thin	5.648	0.592 – 53.887	0.132
Histology characteristics			
Variable cell morphology			
Cytologic atypia	15.029	3.066 – 73.676	<0.001
Lipoblasts	2.012	0.110 – 36.696	0.637

OR: Odds Ratio; CI: Confidence Interval. Significant values ($p < 0.05$) are in bold.

Table 6: Coefficient of determination analysis for independent predictor variables.

Predictor	Pseudo-R2
Cytologic atypia	0.3054
Variable cell morphology	0.2872
Septation	0.1313
Age ≥ 60 years	0.1155
Size ≥ 15cm	0.1099

Table 7: Predictor combinations in order of descending Pseudo-R2.

Predictor combinations	OR (95% CI) p-value	Pseudo-R2
Atypia + age ≥ 60 years	38.84 (10.62, 142.00) <0.001	0.2491
Atypia + variable morphology	29.21 (7.94, 107.37) <0.001	0.1971
Atypia + thin septation	26.47 (7.18, 97.64) <0.001	0.1806
Variable morphology + size ≥ 15cm	6.87 (2.98, 15.81) <0.001	0.1059
Variable morphology + age ≥ 60 years	3.40 (1.42, 8.12) 0.006	0.0372
Thin septation + age ≥ 60 years	0.49 (0.19, 1.28) 0.146	0.0122
Thin septation + size ≥ 15cm	0.73 (0.33, 1.65) 0.454	0.003
Age ≥ 60 years + size ≥ 15cm	0.82 (0.38, 1.75) 0.605	0.0014
Atypia + size ≥ 15cm	N/A*	N/A*
Variable morphology + thin septation	N/A**	N/A**

OR: Odds Ratio; CI: Confidence Interval.

*All patients with this combination have MDM2 amplification.

**Zero patients with this combination have MDM2 amplification.

followed by variable cell morphology (Pseudo-R2 = 0.29), septation (Pseudo-R2 = 0.13), age 60 years or older (Pseudo-R2 = 0.12), and size 15cm or greater (Pseudo-R2 = 0.11). Of the predictor combinations, the presence of cytologic atypia in patients aged 60 years or older conferred the highest Pseudo-R2 value of 0.25. Tumours of 15cm or greater in patients aged 60 years or older conferred to lowest Pseudo-R2 value of 0.001.

Discussion

WDLPS are one of the most common types of soft tissue sarcoma and represent 40% to 45% of all liposarcomas [1,2]. These tumours are typically characterized by the presence of mature adipocytic cells with atypical stromal cells and a scattered lipoblasts [13]. However, these

defining malignant features are not always visualized and, conversely, atypical 'malignant' features may be seen in benign lipomas. Previous studies have shown that misdiagnoses are not infrequent and that contention amongst specialists commonly occurs [14-17]. The use of MDM2 amplification is becoming increasingly popular in the diagnosis of WDLPS. Previous studies have identified the utility of MDM2 amplification testing, especially in identifying malignancy in tumours lacking evidence of cytologic atypia [11,18]. This study sought to, firstly, characterize the impact of MDM2 amplification in diagnosis of WDLPS and patient outcomes and, secondly, identify the predictors of MDM2 amplification to further guide clinical decision-making.

Study Findings

With the introduction of MDM2 amplification testing, this study demonstrated a significant increase in WDLPS diagnoses with concurrent reduction in local recurrences of lipoma. These findings suggest that the use of testing for MDM2 amplification improves the identification of WDLPS, thereby resulting in more aggressive management of such tumours and decreasing the risk of local recurrence.

This study found that the size and site of the tumour, presence of thick septation on MRI, variable cell morphology, and cytologic atypia on histology were all predictors of MDM2 amplification in WDLPS. These histological findings are in keeping with previous studies by Zhang et al. and Thway et al., which also investigated the features of lipomatous tumours that harbour MDM2 amplification [11,18]. Of these features, the presence of cytologic atypia was shown to be the strongest independent predictor of MDM2 amplification in WDLPS, while size 15cm or greater was the least predictive. The combination of cytologic atypia with age greater than 60 years was the strongest predictor combination. These findings were interpreted from the Pseudo-R2 values calculated for independent and combination variables (Table 5 and 6).

The significance of septation on MRI has also been suggested as a feature of malignancy in other studies, which did not incorporate molecular testing [19,20]. Interestingly, this study contrasted with a study by Brisson et al., which found there was no significant association between contrast-enhancing thickened septa and MDM2 amplification [21]. Brisson et al., however, compared the presence of thick septa with thin/absent septa, while this study compared both thin and thick septa individually with absent septa. It was found that, the presence of thick septa, but not thin septa, on MRI was significantly associated with MDM2 amplification.

This study also found that lipoblasts were not associated with MDM2 amplification. Lipoblasts are considered to represent malignant immature adipocytes and are characterized by one or multiple vacuoles and an eccentric, scalloped, hyperchromatic nucleus [22]. Traditionally, these cells were considered a diagnostic hallmark of malignant lipomatous tumours and were essential for diagnosis [23,24]. Despite this, they are not always appreciated in WDLPS and are therefore not essential for its diagnosis [24]. In this study, lipoblasts were observed in only six cases. Interestingly, two cases of non-MDM2 amplified tumours displayed lipoblasts. This finding may be explained by several lipoblast mimics, which can be found in non-malignant tumours. Lockkern cells, for example, are adipocytes

found in benign tumours and even normal fat tissue, which may be confused with lipoblasts due to the presence of intranuclear vacuoles [25]. Additionally, in the context of starvation, malnutrition or local trauma, adipocytes may also demonstrate depletion of intracellular lipid content and thus may mimic lipoblasts. The results of this study suggest that MDM2 amplification is a more reliable differentiator of benign lipoma and WDLPS. Even in the presence of presumed lipoblasts, we suggest MDM2 amplification testing for definitive diagnosis.

The sample set for this study also identified twenty MDM2-amplified tumours, which lacked any evidence of cytologic atypia on histology. Of note were three cases of WDLPS, which did not demonstrate any suspicious histological features at all, including variable cell size and shape, or presence of fibrous septa, atypia, or lipoblasts. Two of these three tumours were deep, intramuscular tumours, while the third was an intra-abdominal tumour. The imaging data for the two intramuscular tumours both demonstrated thin, contrast-enhancing fibrous septa on MRI. One intramuscular tumour was not excised due to the patient's comorbidities and histology was therefore based on a biopsy sample. The MRI results for the intra-abdominal tumour were not identified.

This finding also highlights the need to recognize the inherent disadvantages of biopsy samples in the context of intra-tumoral heterogeneity. Thway et al. concluded that amongst tumours with MDM2 amplification, those that appeared benign on histology were more likely to be biopsy specimens [11]. Recent studies have also found that CT-guided biopsy provides approximately 80% accuracy in the diagnosis of bone and soft tissue sarcoma [26,27]. While biopsy samples do confer a high concordance rate with resected samples, caution should be taken with biopsies that do not demonstrate any malignant features on histology. This study is an important reminder, therefore, to consider the other features, including the size, site, and imaging features of a tumour, even in the presence of a completely histologically benign tumour.

It is also interesting to note that, of the eight tumours that were local recurrences at diagnosis, only one tumour was positive for MDM2 amplification. One other tumour was reclassified as WDLPS despite the negative FISH results. The low incidence of local recurrence of WDLPS compared with lipoma may be attributed to the differences in treatment, the former diagnosis receiving more aggressive management including neoadjuvant radiotherapy and wide local resection. Few studies, however, have interrogated the prognostic significance of MDM2 amplification. Further study would be required to fully explore the significance of this surprising observation.

Study Implications

The results of this study show that MDM2 amplification is more likely to be found in patients aged 60 years or older; in tumours of 15cm or larger; in the presence of thick septation on MRI; and in the presence of variable cell morphology or cytologic atypia on histology. This study showed that, independently, the presence of cytologic atypia on histology is the most predictive factor, followed by variable cell morphology. Based on these findings, we suggest that tumours demonstrating these features be investigated further with molecular testing to assist with the differentiation between WDLPS and lipoma.

This information allows clinicians to better risk stratify tumours, to prevent misdiagnosis of a lipomatous tumour and, ultimately, to ensure adequate management of patients. For WDLPS, the more aggressive treatment regimen involving neoadjuvant radiotherapy and wide local excision aims to reduce the local recurrence risk as well as the risk of dedifferentiation into a higher-grade subtype.

Limitations

A limitation of this study is that the data, including imaging and histology characteristics, was based on reports chart review. While the histology was reviewed and reported by a specialist sarcoma pathologist at our institution, MRI reports were generated from various sites and radiologists. Features such as 'thick' and 'thin' septa, for example, were therefore at risk of interobserver variability. A strict definition and size criteria for septal thickness, with review by one investigator, may have improved the accuracy of the study results. For this study, we chose to obtain information from the reports, as these were more readily available from institutional records and therefore minimized the burden of missing data.

The interpretation of the Pseudo-R2 values also has its limitations. The coefficient of determination represents the 'goodness-of-fit' of the multivariate regression analysis by measuring the percentage of variation in the dependent outcome variable – MDM2 amplification – explained by variation in the independent variables - predictive factors [28,29]. Its interpretation in the clinical setting, however, is ambiguous, in part due to its inability to be compared across samples [29]. This means that the discrete Pseudo-R2 value for each variable is difficult to interpret. In this study, the coefficient of determination was utilized to compare the goodness-of-fit for each independent and combination of predictor variables and thus infer the comparative predictive 'strength'.

Conclusion

The advent of molecular testing for MDM2 amplification has allowed distinction between WDLPS and lipoma. These two entities confer different prognoses and therefore require different treatment strategies, one more aggressive than the other. Prior to molecular testing, their diagnosis was often challenging due to their similar histological appearances. Testing for MDM2 amplification, however, is currently not feasible for every lipomatous tumour and is often not necessary for convincingly benign lesions. Our study sought to determine the features of lipomatous tumours that may suggest the presence of MDM2 amplification and, therefore, indicate the need to test for this molecular aberration.

This study found that MDM2 amplification in WDLPS was associated with older age (60 years or older), increasing size (15cm or larger), thick septation on MRI, variable cell morphology, and cytological atypia. The presence of cytologic atypia was determined to be the strongest predictor of MDM2 amplification. We recommend that clinicians consider further molecular testing in well-differentiated lipomatous samples displaying these features to ensure accurate diagnosis of WDLPS.

References

1. Laurino L, Furlanetto A, Orvieto E, Dei Tos AP. Well-differentiated liposarcoma (atypical lipomatous tumors). *Semin Diagn Pathol.* 2001; 18: 258-262.
2. Lucas DR, Nascimento AG, Sanjay BK, Rock MG. Well-differentiated

- liposarcoma. The Mayo Clinic experience with 58 cases. *Am J Clin Pathol*. 1994; 102: 677-683.
3. Bassett MD, Schuetze SM, Disteche C, Norwood TH, Swisshelm K, Chen X, et al. Deep-seated, well differentiated lipomatous tumors of the chest wall and extremities: the role of cytogenetics in classification and prognostication. *Cancer*. 2005; 103: 409-416.
 4. Dalal KM, Kattan MW, Antonescu CR, Brennan MF, Singer S. Subtype specific prognostic nomogram for patients with primary liposarcoma of the retroperitoneum, extremity, or trunk. *Ann Surg*. 2006; 244: 381-391.
 5. Antonescu CR. The role of genetic testing in soft tissue sarcoma. *Histopathology*. 2006; 48: 13-21.
 6. Weaver J, Rao P, Goldblum JR, Joyce MJ, Turner SL, Lazar AJ, et al. Can MDM2 analytical tests performed on core needle biopsy be relied upon to diagnose well-differentiated liposarcoma? *Modern Pathology*. 2010; 23: 1301-1306.
 7. Kashima T, Halai D, Ye H, Hing SN, Delaney D, Pollock R, et al. Sensitivity of MDM2 amplification and unexpected multiple faint alploid 12 (alpha 12 satellite sequences) signals in atypical lipomatous tumor. *Modern Pathology*. 2012; 25: 1384-1396.
 8. Kimura H, Dobashi Y, Nojima T, Nakamura H, Yamamoto N, Tsuchiya H, et al. Utility of fluorescence in situ hybridization to detect MDM2 amplification in liposarcomas and their morphological mimics. *International Journal of Clinical & Experimental Pathology*. 2013; 6: 1306-1316.
 9. de Vreeze RS, de Jong D, Nederlof PM, Ariaens A, Tielen IH, Frenken L, et al. Added Value of Molecular Biological Analysis in Diagnosis and Clinical Management of Liposarcoma: A 30-Year Single-Institution Experience. *Ann Surg Oncol*. 2010; 17: 686-693.
 10. Cho J, Lee SE, Choi YL. Diagnostic Value of MDM2 and DDIT3 Fluorescence *In Situ* Hybridization in Liposarcoma Classification: A Single-Institution Experience. *The Korean Journal of Pathology*. 2012; 46: 115-122.
 11. Thway K, Wang J, Swansbury J, Min T, Fisher C. Fluorescence *In Situ* Hybridization for MDM2 Amplification as a Routine Ancillary Diagnostic Tool for Suspected Well-Differentiated and Dedifferentiated Liposarcomas: Experience at a Tertiary Center. *Sarcoma*. 2015; 2015: 812089.
 12. Enneking WF, Spanier SS, Goodman MA. A system for the surgical staging of musculoskeletal sarcoma. *Clin Orthop Relat Res*. 1980: 106-120.
 13. Fletcher C, Bridge J, Hogendoorn P, Mertens FJ. WHO classification of tumours of soft tissue and bone (IARC WHO classification of tumours). 2013; 2.
 14. Arbiser ZK, Folpe AL, Weiss SW. Consultative (expert) second opinions in soft tissue pathology. Analysis of problem-prone diagnostic situations. *Am J Clin Pathol*. 2001; 116: 473-476.
 15. Thway K, Fisher C. Histopathological diagnostic discrepancies in soft tissue tumours referred to a specialist centre. *Sarcoma*. 2009; 2009: 741975.
 16. Erickson-Johnson MR, Seys AR, Roth CW, King AA, Hulshizer RL, Wang X, et al. Carboxypeptidase M: a biomarker for the discrimination of well-differentiated liposarcoma from lipoma. *Mod Pathol*. 2009; 22: 1541-1547.
 17. Weaver J, Goldblum JR, Turner S, Tubbs RR, Wang WL, Lazar AJ, et al. Detection of MDM2 gene amplification or protein expression distinguishes sclerosing mesenteritis and retroperitoneal fibrosis from inflammatory well-differentiated liposarcoma. *Mod Pathol*. 2009; 22: 66-70.
 18. Zhang H, Erickson-Johnson M, Wang X, Oliveira JL, Nascimento AG, Sim FH, et al. Molecular testing for lipomatous tumors: critical analysis and test recommendations based on the analysis of 405 extremity-based tumors. *Am J Surg Pathol*. 2010; 34: 1304-1311.
 19. Hosono M, Kobayashi H, Fujimoto R, Kotoura Y, Tsuboyama T, Matsusue Y, et al. Septum-like structures in lipoma and liposarcoma: MR imaging and pathologic correlation. *Skeletal Radiol*. 1997; 26: 150-154.
 20. Galant J, Marti-Bonmati L, Saez F, Soler R, Alcalá-Santaella R, Navarro M. The value of fat-suppressed T2 or STIR sequences in distinguishing lipoma from well-differentiated liposarcoma. *Eur Radiol*. 2003; 13: 337-343.
 21. Brisson M, Kashima T, Delaney D, Tirabosco R, Clarke A, Cro S, et al. MRI characteristics of lipoma and atypical lipomatous tumor/well-differentiated liposarcoma: retrospective comparison with histology and MDM2 gene amplification. *Skeletal Radiology*. 2013; 42: 635-647.
 22. Weiss SW. Lipomatous tumors. *Monogr Pathol*. 1996; 38: 207-239.
 23. Weiss SW, Goldblum JR, Folpe AL. *Enzinger and Weiss's soft tissue tumors*: Elsevier Health Sciences. 2007.
 24. Dei Tos AP. Liposarcomas: diagnostic pitfalls and new insights. *Histopathology*. 2014; 64: 38-52.
 25. Plaut A. The notched nucleus of the fat cell (Unna's lochkern). *J Mt Sinai Hosp NY*. 1957; 24: 1112-1120.
 26. Altuntas AO, Slavin J, Smith PJ, Schlicht SM, Powell GJ, Ngan S, et al. Accuracy of computed tomography guided core needle biopsy of musculoskeletal tumours. *ANZ J Surg*. 2005; 75: 187-191.
 27. Trieu J, Schlicht SM, Choong PF. Diagnosing musculoskeletal tumours: How accurate is CT-guided core needle biopsy? *Eur J Surg Oncol*. 2016; 42: 1049-1056.
 28. Anscombe FJ. Graphs in Statistical Analysis. *The American Statistician*. 1973; 27: 17-21.
 29. Achen CH. Measuring Representation: Perils of the Correlation Coefficient. *American Journal of Political Science*. 1977; 21: 805-815.