

## Case Report

# Pembrolizumab Induced Grade 4 Skin irAEs with Non-Small Cell Lung Cancer: Case Report and Review of Literature

Pengyu Zhou<sup>1,2</sup>, Jing Zhang<sup>2</sup>, Zhaohua Tan<sup>2</sup>, Jianbing Tang<sup>2</sup>, Bin Li<sup>2</sup>, Haiqin Peng<sup>2</sup>, Jing Zhang<sup>2</sup>, Rongrong Zhou<sup>2\*</sup> and Chuanyi Zhou<sup>1\*</sup>

<sup>1</sup>Department of Oncology, Yueyang People's Hospital, Yueyang, PR China

<sup>2</sup>Department of Oncology, Xiangya Hospital, Central South University, Changsha, PR China

\*Corresponding author: Rongrong Zhou, Department of Oncology, Xiangya Hospital, Central South University, Changsha, PR China

Chuanyi Zhou, Department of Oncology, Yueyang People's Hospital, Yueyang, PR China

Received: August 24, 2021; Accepted: October 30, 2021; Published: November 06, 2021

## Abstract

**Objectives:** Immune Checkpoint Inhibitors (ICIs), including pembrolizumab, have exhibited substantial benefits in the treatment of several types of cancers. However, treatment with ICIs is often accompanied by immune-related adverse events (irAEs), we report a rare case of pembrolizumab induced grade 4 skin irAEs with non-small cell lung cancer (NSCLC).

**Materials and Methods:** We report about an advanced NSCLC patient with 4 grade skin irAEs, after the treatment of pembrolizumab. We also compared statistical laboratory results and imageological examinations to discuss the relative factors of the patient's curative effect and adverse reactions.

**Results and Conclusion:** This case is the first report of a 4-degree skin reaction with the pembrolizumab in patients with NSCLC, and the patient has the characteristics of good curative effect and severe adverse reactions. The patient experienced grade 4 skin irAEs after five cycles of pembrolizumab. Increased eosinophil levels are associated with increased skin irAEs in patients. However, CEA and Cytokeratin 19 fragment changes did not show a significant correlation with their skin irAEs and efficacy. The study of this case can provide some reference for efficacy evaluation and treatment after severe skin irAEs in patients with NSCLC.

**Keywords:** Non-small-cell lung cancer; Pembrolizumab; Immune-related adverse event; Grade 4 skin irAEs

## Introduction

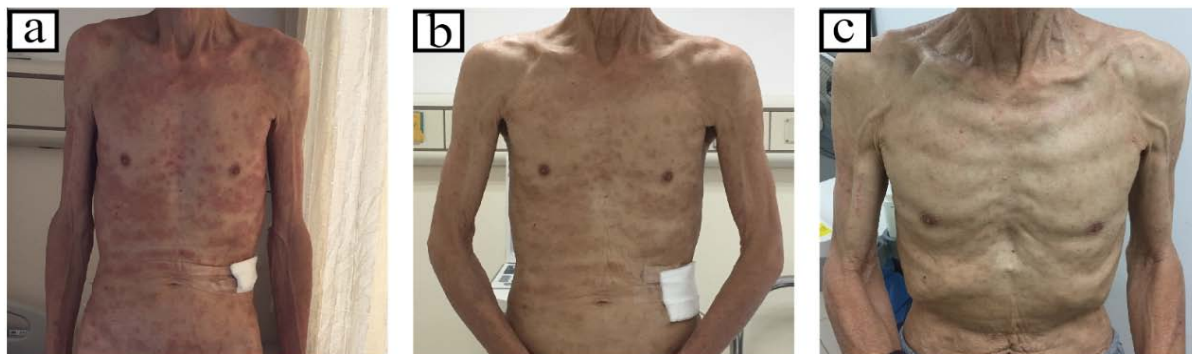At present, many clinical trials have confirmed that checkpoint inhibitors (ICPI) are a broad-spectrum, effective, long-lasting, and relatively safe anti-tumor drug [1]. It suppresses and kills tumor cells by enhancing the body's anti-tumor immune function, and has shown significant clinical efficacy in the treatment of a variety of malignant tumors. Among them, anti-programmed cell death protein 1 (PD-1) and its ligand (PD-1 ligand, PD-L1) can block the binding of PD-1 and PD-L1, and block negative regulatory signals. To restore T cell activity. Therefore, it can enhance the immune response, recognize and kill tumor tissue, and thus achieve the role of anti-tumor therapy [2, 3]. PD-1 and PD-L1 antibodies have changed the treatment of Non-Small Cell Lung Cancer (NSCLC) [4]. Anti-PD1 antibody enhancing the immune responses against carcinoma by blocking immune escape from PD-1 [5]. Pembrolizumab is a PD-1 inhibitor that approved for metastatic melanoma therapy in September 2014 and for second line treatment of NSCLC with tumors expressing PD-L1 in October 2015 [6,7]. The US FDA approved pembrolizumab as a first line therapy for metastatic NSCLC in October 2016 [8]. Increasing use of ICPI has appeared a discrete group of immune-related adverse reactions (irAEs) [9]. Various irAEs have been reported in patients with advanced melanoma after anti-PD1 antibodies therapy [10,11], but little is known about various skin irAEs associated with anti-PD1 therapy in patients with NSCLC [12]. We present a case about grade

4 Skin irAEs encountered in our hospital. It is hoped to play a role in the treatment of related skin adverse events in patients with NSCLC after anti-PD1 antibody treatment.

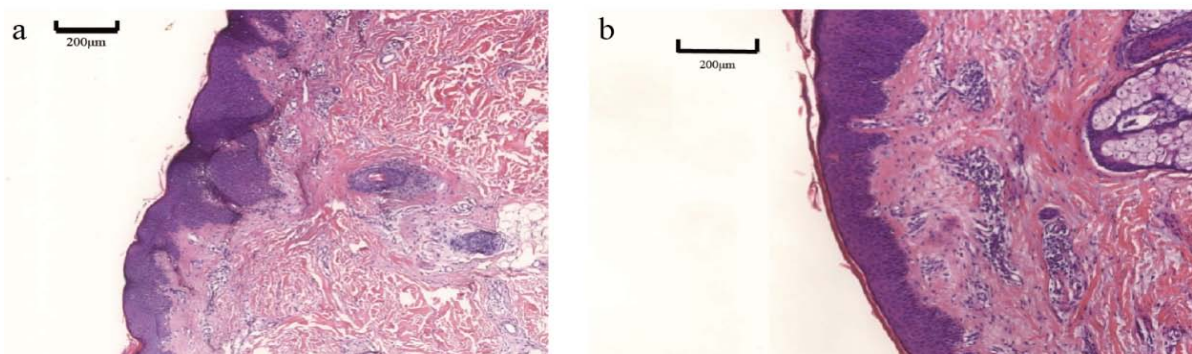
## Case Presentation

In a 69-year-old male with right lung adenocarcinoma and a history of smoking, computerized tomography (CT) in October 2018 showed that lymph nodes near the right upper trachea and right hilum were enlarged (Figure 3). He was diagnosed with right lung adenocarcinoma (T2bN2M0 stage IIIA TMB-H, MSS, PD-1: 100%) by tracheoscopic fibroscope biopsy and received pembrolizumab (100mg every 3 weeks) as therapy.

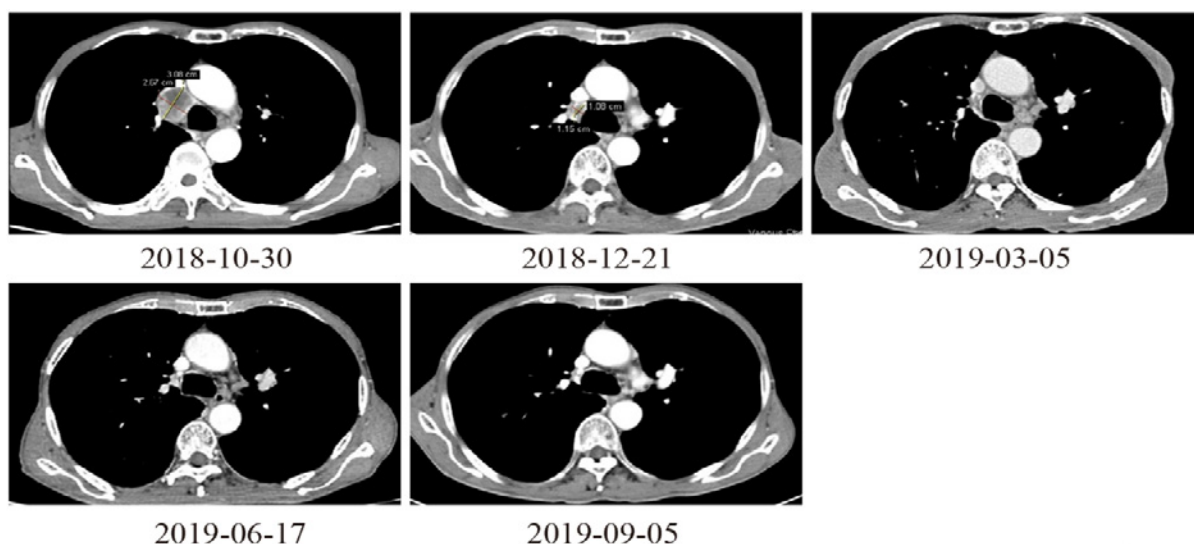
The patient developed red erythema on the left lower limb after two doses of pembrolizumab; it was not painful and did not itch, and was not treated. CT scans in December 2018 clearly indicated that the enlarged lymph nodes near the right upper trachea and right hilum were smaller than in October 2018. The treatment assessment was partial response (PR), close to complete response (CR) (Figure 3). The patient continued to receive treatment with pembrolizumab. The skin area of the patient's rash expanded to the lower extremity knee joint after three doses of pembrolizumab. Due to his short stay in our hospital, the patient was treated with traditional Chinese medicine and ointment at a local hospital, and the skin symptoms were not significantly relieved.



**Figure 1:** a) Red, painful pruritic erythema on Limbs and torso, staining around the erythema; b) Patient's skin reaction on the third day after treatment; c) When the patient came to the hospital for review in June 2019, the skin had returned to normal.



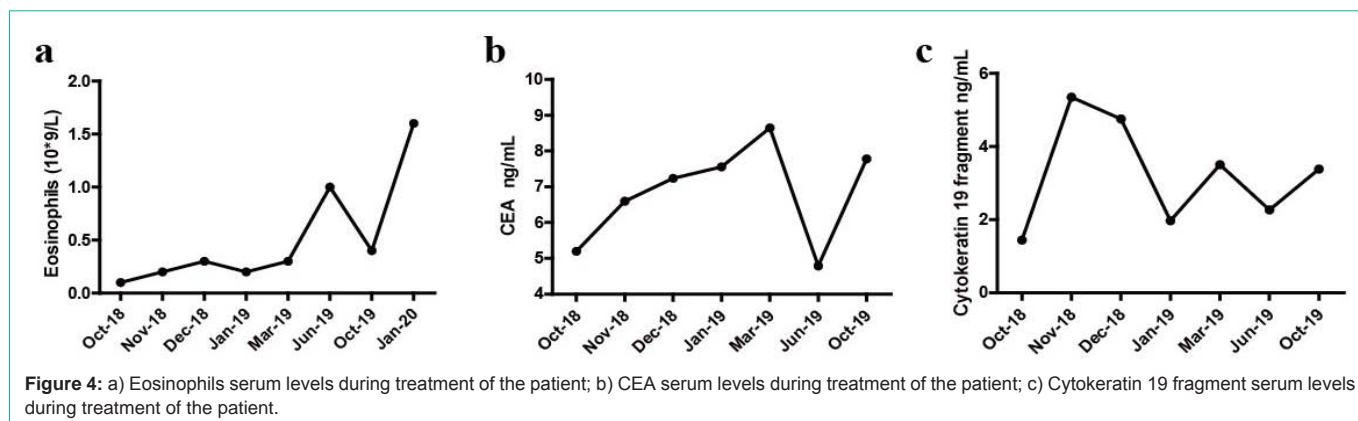
**Figure 2:** a-b) A biopsy specimen from the left abdomen, Irregular hypertrophy of the spinous layer, infiltration of lymphocytes and eosinophils around the superficial dermis, considering allergic lesions.



**Figure 3:** Lung enhanced computerized tomography scan during the patient treatment.

After five doses of pembrolizumab, the patient developed red, painful, pruritic erythema on the limbs and torso, with discoloration around the erythema (Figure 1a). Admission laboratory data indicated elevated eosinophils ( $1 \times 10^9/L$ ) and a negative skin fungal test. Histopathology showed irregular hypertrophy of the spinous

layer, with infiltration of lymphocytes and eosinophils around the superficial dermis consistent with allergic lesions (Figure 2a and 2b). CT in June 2019 confirmed that the cancer had not progressed (Figure 3). According to these composite findings, a diagnosis of grade 4 skin immune-related adverse events (irAEs) was established.



Pembrolizumab was discontinued, and the patient was treated with intravenous methylprednisolone for 3 days. At the same time, compound glycyrrhizin (80mg qd) was administered intravenously, levocetirizine (5mg qd) and bepotastine (10mg bid) were administered orally, and the itchy skin area was treated with mometasone cream. The area of epidermal desquamation was treated with urea cream. After 3 days of continuous treatment, the patient's rash almost completely subsided, although pigmentation remained (Figure 1b). The patient's rash and symptoms were significantly relieved and he was discharged.

The patient's skin returned to normal after resting at home for three months (Figure 1c). Although his immune therapy had been discontinued for six months, no progression was seen on a CT scan in September 2019. We decided to give another cycle of pembrolizumab (100mg every 3 weeks) after evaluating the patient's condition.

The patient again developed a rash after he was discharged from the hospital, and he had a grade 3 skin irAE within two months. The skin reactions manifested as systemic erythema, a small area of pimples, varying in size, with unclear borders, and scratches and scales scattered on the skin surface. The patient was treated at the dermatology department of our hospital in 2020, and received calcium aspartate, fexofenadine, levocetirizine antihistamine, gabapentin, compound glycyrrhizin, mometasone cream, kalmethasone III, and chlorogenic acid cream for topical use. The patient was discharged after symptom relief.

## Discussion

Two classes of Immune-Checkpoint Inhibitors (ICPIs) have revolutionized the treatment of metastatic Non-Small Cell Lung Cancer (NSCLC): anti PD L1 and anti PD 1. The anti PD 1 agent pembrolizumab has been defined as a new and promising therapy for NSCLC, and was approved by the US FDA as a first line treatment in October 2016 [13-15].

With the widespread use of ICPIs, irAEs have increased. In international phase III trials of pembrolizumab (KEYNOTE-024 and KEYNOTE-021), the proportion of patients who had treatment discontinued because of irAEs was 4.0–7.1% [16, 17]. Skin toxicity is the most common irAE, and can cause itching, rashes, and vitiligo. Vitiligo is frequently seen in patients with melanoma. Skin toxicities (of all grades) are observed in 30-40% of patients taking PD-1/PD-L1 inhibitors [18,19]. A systematic review showed that 13-20% of

patients receiving nivolumab or pembrolizumab developed a rash or pruritus, and 8% of patients with melanoma-developed vitiligo [20]. Hua et al. [21] suggested that vitiligo might be associated with tumor response. Although rare, some life-threatening skin conditions, such as Stevens-Johnson syndrome and drug rash with eosinophilia and systemic symptoms (DRESS), have been reported [22]. However, no cases of skin reactions above grade 3 have been reported in lung cancer patients treated with pembrolizumab.

In our case, the patient's expression levels of PD-1, TMB-H, and MSS indicated that a significant benefit could be obtained from immune therapy as first-line treatment. Unfortunately, the patient suffered from grade 4 skin irAEs after five doses of pembrolizumab treatment. His clinical symptoms were in remission after treatment with methylprednisolone, compound glycyrrhizin, levocetirizine, bepotastine, and externally used creams. Hua [20] has found that vitiligo may be a clinically observed irAE associated with the antitumor efficacy of pembrolizumab treatment. We think that the severity of skin reactions may also be positively correlated with the efficacy of immunotherapy. Our patient's tumor lesions were significantly smaller in October 2018 after three cycles of pembrolizumab treatment, and the response was evaluated as PR, close to CR. The lesions did not progress during the follow-up review, even after the drug was discontinued. Thus, the response of this patient was characterized by severe skin reactions and significant therapeutic benefit. According to the current consensus on the management of adverse reactions in immunotherapy, for maculopapular rash or pruritus, ICPIs may be considered for re-use when symptoms return to  $\leq$  grade 1. But for severe, life-threatening blistering diseases, such as Stevens-Johnson syndrome, toxic epidermal necrolysis, and DRESS, ICPI use is discontinued permanently. Our patient developed grade 4 skin irAEs, which returned to normal after treatment. Subsequently, the patient was given another cycle of immunotherapy, and he again experienced a grade 3 skin irAE. Therefore, we suggest follow-up and timely symptomatic supportive treatment for patients with grade 3 or 4 skin irAEs after repeated immunotherapy.

At the same time, we found elevated eosinophil levels in laboratory tests when the patient experienced skin reactions. In December 2019, when the patient had a grade 4 skin irAE, it peaked at  $1 \times 10^9/L$ . After symptomatic supportive treatment, including glucocorticoids, his eosinophils dropped to  $0.4 \times 10^9/L$  in October 2019. The patient experienced a grade 3-4 skin irAE after using pembrolizumab again, and his eosinophils increased to  $1.6 \times 10^9/L$ . We infer that the increased

level of eosinophils is related to the occurrence of grade 3-4 skin reactions in patients (Figure 4a). However, the patient's baseline CEA and cytokeratin 19 fragment levels did not increase significantly, and thus did not show a significant correlation with skin response or treatment efficacy (Figure 4b and 4c).

Previous studies of NSCLC patients found that an EGFR TKI-related skin rash was significantly associated with greater overall survival (OS) (hazard ratio (HR): 0.30), longer progression-free survival (PFS) (HR: 0.50), and a better objective response rate (ORR) (42 vs. 7%) [23]. A similar phenomenon has been found by researchers using ICPIs. Sanlorenzo [24] indicated that significantly longer PFS was observed in patients who developed skin irAEs, relative to those who did not. Earlier reports also found that irAEs are correlated with higher response rates to immunotherapy, but these occurrences have not usually been examined further [25-27]. Similar therapeutic efficacy was found in patients with or without irAEs in a study of ipilimumab. This analysis had some limitations, in that it was a single institution study, although relatively large, and some clinical trials data were not collected. The researchers did not evaluate tumor responses systematically, nor did they grade toxicity. The patients included may be less representative than those in some prior clinical trials and the study's findings need further verification in clinical practice [28]. At a minimum, it appears that irAEs are not necessary to obtain better response rates with immune therapy.

Certain irAEs may be more directly associated with therapy response than others. For instance, vitiligo is perhaps more closely related to immune therapy efficacy than other irAEs [29,30]. Recently, a "real-life" multicenter retrospective study found that different degrees of irAE were significantly associated with higher ORR, longer PFS, and greater OS in patients with NSCLC after anti-PD-1 immunotherapy. Their results also revealed that ECOG-PS > 2 was associated with a lower incidence rate of irAEs (all grades). Interestingly, irAEs (all grades), endocrine irAEs, skin irAEs, and "single-site" irAEs were concordantly related to a better clinical response to immune therapy (ORR, PFS, and OS), but this phenomenon was not found in patients who developed grade 3 or 4 irAEs [31]. Thus, it is possible that irAEs are more directly associated with antitumor efficacy, but additional prospective studies are needed to verify these findings.

## Conclusion

We reported a case of an NSCLC patient who developed grade 4 skin irAEs during pembrolizumab treatment, together with a review of the relevant literature. Pembrolizumab-induced skin irAEs are more likely to develop in patients with better treatment responses to ICPIs. With the introduction and increasing use of newer, more effective immunotherapies like pembrolizumab for various malignancies, including NSCLC, we should emphasize early diagnosis and effective management of irAEs, including skin irAEs. It is also necessary to pay attention to the occurrence of adverse reactions during re-use of pembrolizumab, after the relief of adverse reactions. By collecting more clinical data, it is hoped that some evidence, such as eosinophil levels, may be useful in guiding the prevention of severe skin reactions.

## Declaration

**Acknowledgment:** This study was supported by the National

Natural Science Foundation of China (81770928 to R.R.Z), Natural Science Foundation of Hunan (2018JJ2626 to R.R.Z), National Multidisciplinary Cooperative Diagnosis and Treatment Capacity Building Project for Major Diseases (Lung Cancer), Science and Technology Plan Project of Yueyang.

The English in this document has been checked by at least two professional editors, both native speakers of English. For a certificate, please see: <http://www.textcheck.com/certificate/ssqONG>.

## References

- Chen DS, Mellman I. Elements of cancer immunity and the cancer-immune set point. *Nature*. 2017; 541: 321-330.
- Bai J, Gao Z, Li X, Dong L, Han W, Nie J. Regulation of PD-1/PD-L1 pathway and resistance to PD-1/PD-L1 blockade. *Oncotarget*. 2017; 8: 110693-110707.
- Alsaab HO, Sau S, Alzhrani R, et al. PD-1 and PD-L1 Checkpoint Signaling Inhibition for Cancer Immunotherapy: Mechanism, Combinations, and Clinical Outcome. *Front Pharmacol*. 2017; 8: 561.
- Blank C, Brown I, Peterson AC, et al. PD-L1/B7H-1 inhibits the effector phase of tumor rejection by T cell receptor (TCR) transgenic CD8+ T cells. *Cancer Res*. 2004; 64: 1140-1145.
- Khagi Y, Kurzrock R, Patel SP. Next generation predictive biomarkers for immune checkpoint inhibition. *Cancer Metastasis Rev*. 2017; 36: 179-190.
- Garon EB, Rizvi NA, Hui R, et al. Pembrolizumab for the treatment of non-small-cell lung cancer. *N Engl J Med*. 2015; 372: 2018-2028.
- Hanna KS. A Rare Case of Pembrolizumab-Induced Uveitis in a Patient with Metastatic Melanoma. *Pharmacotherapy*. 2016; 36: e183-e188.
- Rihawi K, Gelsomino F, Sperandi F, et al. Pembrolizumab in the treatment of metastatic non-small cell lung cancer: a review of current evidence. *Ther Adv Respir Dis*. 2017; 11: 353-373.
- Puzanov I, Diab A, Abdallah K, et al. Managing toxicities associated with immune checkpoint inhibitors: consensus recommendations from the Society for Immunotherapy of Cancer (SITC) Toxicity Management Working Group. *J Immunother Cancer*. 2017; 5: 95.
- Hamid O, Robert C, Daud A, et al. Safety and tumor responses with lambrolizumab (anti-PD-1) in melanoma. *N Engl J Med*. 2013; 369: 134-144.
- Martin-Liberal J, Kordbacheh T, Larkin J. Safety of pembrolizumab for the treatment of melanoma. *Expert Opin Drug Saf*. 2015; 14: 957-964.
- Hwang SJ, Carlos G, Wakade D, et al. Cutaneous adverse events (AEs) of anti-programmed cell death (PD)-1 therapy in patients with metastatic melanoma: A single-institution cohort. *J Am Acad Dermatol*. 2016; 74: 455-461.e1.
- Brahmer J, Reckamp KL, Baas P, et al. Nivolumab versus Docetaxel in Advanced Squamous-Cell Non-Small-Cell Lung Cancer. *N Engl J Med*. 2015; 373: 123-135.
- Garon EB, Rizvi NA, Hui R, et al. Pembrolizumab for the treatment of non-small-cell lung cancer. *N Engl J Med*. 2015; 372: 2018-2028.
- Smit EF, Baas P. Lung cancer in 2015: Bypassing checkpoints, overcoming resistance, and honing in on new targets. *Nat Rev Clin Oncol*. 2016; 13: 75-76.
- Reck M, Rodriguez-Abreu D, Robinson AG, et al. Pembrolizumab versus Chemotherapy for PD-L1-Positive Non-Small-Cell Lung Cancer. *N Engl J Med*. 2016; 375: 1823-1833.
- Herbst RS, Baas P, Kim DW, et al. Pembrolizumab versus docetaxel for previously treated, PD-L1-positive, advanced non-small-cell lung cancer (KEYNOTE-010): a randomised controlled trial. *Lancet*. 2016; 387: 1540-1550.
- Villadolid J, Amin A. Immune checkpoint inhibitors in clinical practice: update on management of immune-related toxicities. *Transl Lung Cancer Res*. 2015;

- 4: 560-575.
19. Kumar V, Chaudhary N, Garg M, Floudas CS, Soni P, Chandra AB. Current Diagnosis and Management of Immune Related Adverse Events (irAEs) Induced by Immune Checkpoint Inhibitor Therapy. *Front Pharmacol*. 2017; 8: 49.
  20. Belum VR, Benhuri B, Postow MA, et al. Characterisation and management of dermatologic adverse events to agents targeting the PD-1 receptor. *Eur J Cancer*. 2016; 60: 12-25.
  21. Hua C, Boussemart L, Mateus C, et al. Association of Vitiligo With Tumor Response in Patients With Metastatic Melanoma Treated With Pembrolizumab. *JAMA Dermatol*. 2016; 152: 45-51.
  22. Spain L, Diem S, Larkin J. Management of toxicities of immune checkpoint inhibitors. *Cancer Treat Rev*. 2016; 44: 51-60.
  23. Petrelli F, Borgonovo K, Cabiddu M, Lonati V, Barni S. Relationship between skin rash and outcome in non-small-cell lung cancer patients treated with anti-EGFR tyrosine kinase inhibitors: a literature-based meta-analysis of 24 trials. *Lung Cancer*. 2012; 78: 8-15.
  24. Sanlorenzo M, Vujic I, Daud A, et al. Pembrolizumab Cutaneous Adverse Events and Their Association with Disease Progression. *JAMA Dermatol*. 2015; 151: 1206-1212.
  25. Weber JS, Hodi FS, Wolchok JD, et al. Safety Profile of Nivolumab Monotherapy: A Pooled Analysis of Patients with Advanced Melanoma. *J Clin Oncol*. 2017; 35: 785-792.
  26. Attia P, Phan GQ, Maker AV, et al. Autoimmunity correlates with tumor regression in patients with metastatic melanoma treated with anti-cytotoxic T-lymphocyte antigen-4. *J Clin Oncol*. 2005; 23: 6043-6053.
  27. Downey SG, Klapper JA, Smith FO, et al. Prognostic factors related to clinical response in patients with metastatic melanoma treated by CTL-associated antigen-4 blockade. *Clin Cancer Res*. 2007; 13: 6681-6688.
  28. Horvat TZ, Adel NG, Dang TO, et al. Immune-Related Adverse Events, Need for Systemic Immunosuppression, and Effects on Survival and Time to Treatment Failure in Patients With Melanoma Treated With Ipilimumab at Memorial Sloan Kettering Cancer Center. *J Clin Oncol*. 2015; 33: 3193-3198.
  29. Hua C, Boussemart L, Mateus C, et al. Association of Vitiligo With Tumor Response in Patients With Metastatic Melanoma Treated With Pembrolizumab. *JAMA Dermatol*. 2016; 152: 45-51.
  30. Teulings HE, Limpens J, Jansen SN, et al. Vitiligo-like depigmentation in patients with stage III-IV melanoma receiving immunotherapy and its association with survival: a systematic review and meta-analysis. *J Clin Oncol*. 2015; 33: 773-781.
  31. Cortellini A, Chiari R, Ricciuti B, et al. Correlations Between the Immune-related Adverse Events Spectrum and Efficacy of Anti-PD1 Immunotherapy in NSCLC Patients. *Clin Lung Cancer*. 2019; 20: 237-247.e1.