

## Review Article

# Plasmacytoid Dendritic Cell Proliferation Associated with Acute Myeloid Leukemia, Case Report and Review of Literature

Qian YW<sup>1</sup>; Shalaby K<sup>2</sup>; Griffiths EA<sup>2</sup>; Fu K<sup>1</sup>; Ali S<sup>1</sup><sup>1</sup>Department of Pathology, Roswell Park Cancer Institute, USA<sup>2</sup>Department of Medicine, Roswell Park Cancer Institute, USA**\*Corresponding author: You-Wen Qian**

Department of Pathology and Laboratory Medicine, Roswell Park Cancer Center, Basic Science Building, Room 529, Elm St and Carlton St, Buffalo, NY, 14203, USA.

Tel: 716-845-2300x5631

Email: you-wen.qian@roswellpark.org

**Received:** June 06, 2023**Accepted:** July 03, 2023**Published:** July 10, 2023**Abstract**

We present a typical case of plasmacytoid dendritic cell proliferation associated with acute myeloid leukemia (pDC-AML). The patient was a 65-year-old male admitted for new onset progressive pancytopenia over the course of three weeks. Diagnostic marrow revealed 27% myeloblasts. In addition, flow cytometry and immunohistochemistry studies identified an 18% population of immature plasmacytoid dendritic cells. Baseline next-generation sequencing identified pathogenic mutations in *ASXL1*, *EZH2*, *FLT3*, and *RUNX1*. The patient underwent induction chemotherapy for a diagnosis of pDC-AML. One month after chemotherapy, evaluation for Measurable Residual Disease (MRD) using multiparameter flow cytometry was interpreted as negative with changes related to treatment.

pDC-AML is a newly described rare subtype of acute myeloid leukemia which can impose diagnostic challenges. Clinical, pathologic, and molecular correlation are important to render an accurate final diagnosis. We review the published literature on pDC-AML cases and discuss pDC biology, and the process for differentiating the diagnosis of pDC-AML from those of blastic plasmacytoid dendritic cell neoplasm or mature plasmacytoid dendritic cell proliferations associated with other myeloid neoplasms. The AML MRD evaluation for pDC-AML is a particular challenge. To this end, additional molecular studies, including MRD tests using next-generation sequencing, can be of great help.

**Keywords:** Acute myeloid leukemia; Flow cytometry; Immunophenotyping; Measurable/minimal residual disease; Plasmacytoid dendritic cells

**Abbreviations:** AML: Acute Myeloid Leukemia; DC: Dendritic Cell; Pdc: Plasmacytoid Dendritic Cell; Cdc: Classic/Conventional DC; MFC: Multiparameter Flow Cytometry; BPDCN: Blastic Plasmacytoid Dendritic Cell Neoplasm; MRD: Measurable/Minimal Residual Disease; IRF: Interferon Regulator Factors; CBC: Complete Blood Count; WBC: White Blood Cell; NGS: Next-Generation Sequencing; RPMI: Roswell Park Memorial Institute; PBS: Phosphate-Buffered Saline; MPDCP: Mature Plasmacytoid Dendritic Cell Proliferation; ICC: International Consensus Classification; WHO: World Health Organization; HSCT: Hematopoietic Stem Cell Transplantation; LAIP: Leukemia-Associated Immunophenotype; LLOD: Low Limit Of Detection

## Introduction

Recent studies describe a subtype of Acute Myeloid Leukemia (AML) that is associated with proliferation of Plasmacytoid Dendritic Cells (pDC). These pDCs can range from 2% to 36% of bone marrow cellularity and the entity has been named pDC associated AML (pDC-AML) [1-3]. Zalmi et al [1] compared 15 cases of pDC-AML with 21 cases of Blastic Plasmacytoid Dendritic Cell Neoplasm (BPDCN) using pDCs from 11 healthy donors as comparators. They concluded that the pDCs from pDC-AML are in the pre-DC stage and are phenotypically different from those seen in BPDCN. pDCs in pDC-AML carry the same mutations as those in mature monocytes and conventional dendritic cells. They also observed a high frequency of mutations in *RUNX1* associated with these cases which are often minimally differentiated (previously described as the FAB M0-AML subtype). Xiao et al. [2] described an additional 26 cases of pDC-AML. They confirmed that the pDCs and myeloblasts are clonally related and share the same gene mutations. *RUNX1* mutations were also observed in 70% of their cases. A third group, Wang et al. [3] described 53 cases of pDC-AML. They identified cases from their cohort using a cutoff of at least 2% pDCs and compared the immunophenotypic and molecular features of pDC-AML with cases of BPDCN. The pDCs from pDC-AML are more likely to express CD34 (96% vs 0%) and less likely to express CD56 (8% vs 97%) and TCL1 (12% vs 98%) compared with pDCs from patients with BPDCN. Molecularly, *RUNX1* mutations were detected in 64% of pDC-AML cases and only rarely (2%) in patients with a diagnosis of BPDCN.

pDC-AML, as an emerging subset of AML, still has many details to be parsed out. The current WHO classification (5th edition, 2022) [4] places pDC-AML under the category of “plasmacytoid dendritic neoplasms”. However, the above-mentioned literature indicate that pDC-AML is quite distinct, both in terms of immunophenotype and molecular character, from other “plasmacytoid dendritic neoplasms.” Immunophenotyping by flow cytometry and/or immunohistochemistry plays a central role in recognizing this subtype of AML. We present here a typical case of pDC-AM, highlighting Multiparameter Flow Cytometry (MFC) routine and Measurable Residual Disease (MRD) evaluation, and Next-Generation Sequencing (NGS) findings. This case presentation and literature review aims to raise the awareness of this rare disease entity in our daily practice.

## Case Report

A 65-year-old male presented with pancytopenia for three weeks. A Complete Blood Count (CBC) showed pancytopenia with White Blood Cell (WBC):  $34 \times 10^9/L$ , Hg: 6.8 g/dl and platelets:  $36 \times 10^9/L$ . A manual differential showed blasts: 1%, neutrophils: 34%, eosinophils: 4%, monocytes: 17%; lymphocytes; 37%, large granular lymphocytes 7%. A baseline chest CT revealed scattered ground glass, with patchy opacities bilaterally suggesting pneumonitis/pneumonia, for which the patient was treated with Zosyn and azithromycin. An outside bone marrow pathology report was suspicious for BPDCN; it was noted the patient did not have the classic skin manifestations of this disease. A bone marrow aspirate and biopsy were performed. Representative histomorphology is presented in Figure 1. Following standard operating procedures, MFC was performed by an FDA-approved ClearLLab 10-color system. Flow cytometry data was collected on the Navios EX flow cytometer (Beckman Coulter Life Sciences, IN, US), and analyzed by Kaluza software (Kaluza C1.2). Intracytoplasmic staining tube was performed on an eight-color FACS Canto (Becton Dickinson, San Jose, CA) flow

cytometer using a one-tube eight-color antibody panel developed at our institution. Antibodies used are MPO-FITC; CD79a-PE; CD22-PCP; CD34-PECY7; TdT-APC; CD45-APCH7; CD3-BV421; CD10-BV510. Data were acquired with FACS Diva software (Becton Dickinson, San Jose, CA), and analyzed via WinList software. Phenotypic findings by MFC were depicted in Figure 2.

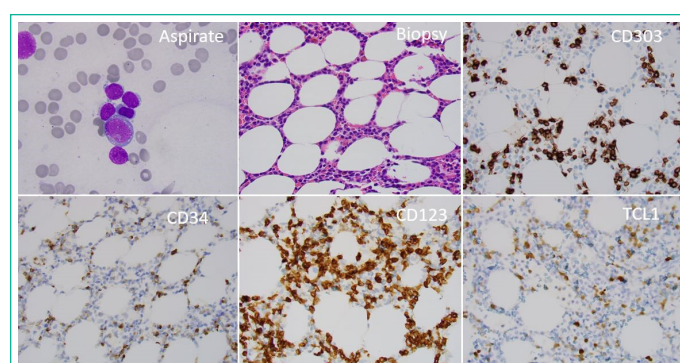
Conventional chromosome analysis showed a normal male karyotype: 46, XY in 20 metaphases.

Next generation sequencing for somatic mutations was performed on a NextSeq following the manufacturer’s recommended protocol (Illumina Inc.). The lower limit of detection (LLOD) for mutations in this panel has been validated at 5%. NGS performed on the bone marrow sample showed pathogenic mutations in *FLT3*, *EZH2*, *ASXL1* and *RUNX1* (Table 2).

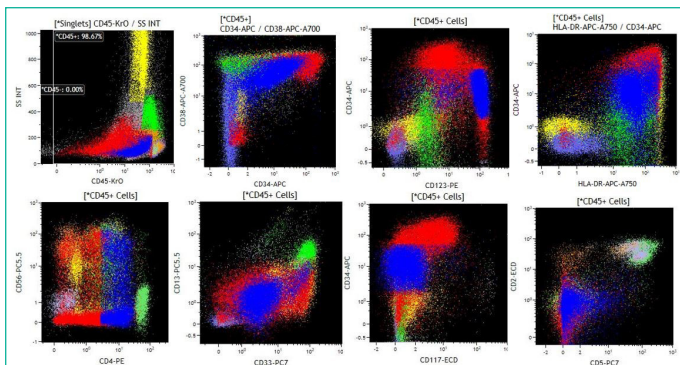
A diagnosis of pDC-AML was rendered and the patient was treated with standard cytarabine based induction chemotherapy (cytarabine 100mg/m<sup>2</sup>x7d continuous IV infusion and daunorubicin 60mg/m<sup>2</sup> daily x 3 days). A day 14 bone marrow was hypocellular (3-5%) for age, with predominantly inflammatory cells and stromal injury consistent with effective chemotherapy response. A follow up bone marrow at the time of count recovery showed a mildly hypocellular bone marrow for age (20-30% cellularity) with erythroid predominance, granulocytic hypoplasia, and 1% blasts. AML MRD flow cytometry using a five-tube-eight-color panel as shown in Table 1 was performed on an eight-color FACS Canto flow cytometer (Becton Dickinson, San Jose, CA) and was consistent with disease clearance. The AML MRD flow cytometry findings were depicted in Figure 3.

**Table 1:** Acute myeloid leukemia measurable residual disease panel.

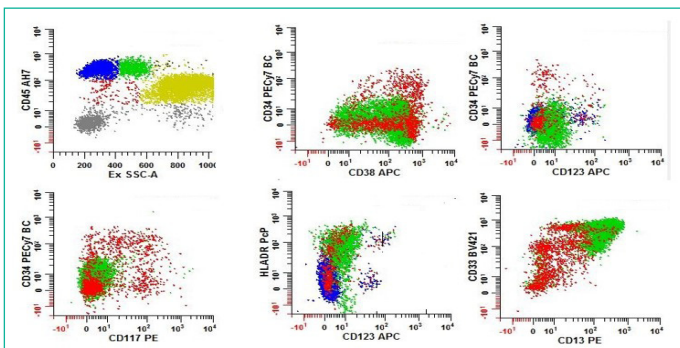
Tubes	FITC	PE	PCP	PECy7	APC	AH7	V450	BV510
1	CD3	CD14	HLADR	CD34	CD123	CD45	CD16	CD19
2	CD11b	CD13	CD10	CD34	CD38	CD45	CD33	CD19
3	HLADR	CD117	CD7	CD34	CD38	CD45	CD56	CD19
4	CD4	CD36	CD14	CD34	CD64	CD45	CD163	CD19
5	CD5	CD2	CD7	CD34	CD38	CD45	CD15	CD19



**Figure 1:** Morphologic features of a pDC-AML. The aspirate smears and touch imprints show many blasts that have round nuclear contours, fine nuclear chromatin, prominent nucleoli, and scant variably granular basophilic cytoplasm without Auer rods. There are also populations of immature cells with scanty cytoplasm, basophilic cytoplasm, with pseudopods and cytoplasmic vacuoles. Trilineage hematopoiesis is markedly reduced. The bone marrow core biopsy is mildly hypercellular with 50% cellularity. The abnormal blast population is interstitially infiltrating along the adipose and in some areas forming small aggregates. Normal trilineage hematopoiesis is suppressed. The blast population is highlighted by CD34 and dim CD123 while pDCs are positive for CD303 and TCT1 as well as bright CD123.



**Figure 2:** Routine flow cytometry panel performed by a ClearLab system detected two distinct abnormal populations. The myeloblast population, highlighted in red, expresses bright CD34, dim CD45, bright CD38, dim CD123, bright HLADR, CD4, dim CD13, heterogeneous CD33, dim CD117, small and subset CD56. This population represents approximately 27% of total cells, based upon a Boolean gating strategy. The pDC population, highlighted in blue, expresses dim CD34, moderate CD45, CD38, dim CD4, small subset CD56, dim to negative CD13, HLADR, bright CD123, and dim CD33 and is negative for CD117. This population represents approximately 18% of total cells, based upon a Boolean gating strategy. Note the fluorescence intensity differences on CD45, CD38, CD34, CD123 and CD4 between the blasts and pDCs. pDCs have continuous maturation pattern with the blasts on CD38 vs D34 and CD34 vs CD123 plots. Monocytes express aberrant CD2 and CD5. Histogram not shown but the myeloblasts also express CD200, subset CD64, dim CD11b, CD15, subset CD7, subset cytoplasmic MPO, subset cytoplasmic TdT; and is negative for CD10, CD5, CD19, CD20, CD2, CD16, CD14, cytoplasmic CD79a, and cytoplasmic CD3. pDCs express heterogeneous CD10, subset CD5, CD200, subset CD7, subset CD16, dim CD11b and is negative for CD19, CD20, CD2, CD14, cytoplasmic TdT, cytoplasmic MPO, cytoplasmic CD79a, and cytoplasmic CD3.



**Figure 3:** AML MRD study on a one-month post-chemotherapy bone marrow sample. A population of pDCs was measured at approximately 0.2% of total cells, based upon the positive CD123 and positive HLADR percentage. A subset of pDCs expresses dim CD34. Myeloblasts were present at approximately 0.4% of total cells, based upon the CD34 positive percentage. Subsets of blasts express dim CD11b, dim subset CD7, and dim CD3d (histogram not shown). Lower limit of detection: 0.01%.

**Discussion and Review of Literature**

**Plasmacytoid Dendritic Cell Development and Summary of Reported Pdc-AML Cases**

DCs are innate immune cells that initiate and control the response of the human immune system [5]. The classification of DCs has evolved from an anatomic classification based on where they reside to a lineage differentiation classification correlating with transcription factor expression. Currently, pDCs are defined primarily by expression of interferon regulator factors 8 and 4 (IRF 8 and 4), whilst classic or conventional DCs (cDC) lack either IRF4 or IRF8 including myeloid DCs and monocyte-

**Table 2:** Percentage of blasts, pDCs and monocytes determined by morphology and MFC, and the NGS findings on bone marrow samples before and after chemotherapy.

Morphology and MFC			Initial bone marrow	One month post chemotherapy,
	Blasts (%)		27%	0.40%
	Plasmacytoid dendritic cells (%)		18%	0.20%
	Monocytes		4%	5%
NGS	Gene	Variant	VAF	VAF
	ARID2	V1720L	43.30%	49.80%
	ASXL1	S554Kfs*11	40.70%	---
	BCORL1	H1180Y	100.00%	99.90%
	CEBPA	G54C	53.10%	49.50%
	CHEK2	R535H	49.60%	47.40%
	EP300	V435I	45.80%	48.70%
	EZH2	L674F	79.50%	4.90%
	FLT3	I836del	14.6%	
	IDH2	A214T	50.30%	46.50%
	JAK3	A952V	48.40%	47.30%
	NBN	T139A	47.40%	49.10%
	PIK3CA	Y644H	8.30%	5.80%
	RUNX1	Y355*	39.20%	---
	RUNX1	c.613_613+1insCCCCGAA	24.90%	---
	SETBP1	T224S	43.90%	48.30%
	TNFRSF14	A136T	48.00%	48.00%
	ZRSR2	C320R	80.70%	5.40%

derived DC (mo-DC) [5]. Historically, pDCs are thought to have a myeloid origin, but recent research argues the lymphoid origin of the pDC, based on several single-cell sequencing study results [6]. The origin of pDC and its development is still debated.

As early as 2009, Martin-Martin et al. [7] described three different maturation stages of pDCs found in normal bone marrow using markers including CD34, CD123, CD45 and HLADR. The pDC maturation stages were primarily based on the presence and absence and the expression intensities of these markers. The different pDC maturation stages were also studied by Huang et al. in 2020 on bone marrow samples from 14 patients diagnosed with pDC proliferation in myeloid neoplasm [8]. pDC proliferation in tissue in AML patients has been sporadically reported. In 2010, Dargen et al. reported pDC proliferation in the skin of a patient with AML [9]. Those pDCs did not express immature markers such as CD34. In 2012, Song et al. also reported a case of tumorous proliferation of pDC and Langerhan cells in a lymph node in a 55-year man with AML. Again, pDCs in that patient had a mature phenotype, corresponding to stage III pDCs. pDC proliferation in bone marrow was first reported by Wang et al. in 2017 [10]. It is unclear whether mature pDC proliferation in tissue and bone marrow in the context of AML are the same neoplastic process as those in pDC-AML. Reports have shown that pDCs in MPDCP associated with AML had genetic mutations and expression profiles similar to those in the associated AML blasts, including pathogenic *RUNX1* and *FLT3*-ITD mutations [11]. The following table summarizes reported cases where pDCs were increased in bone marrow with a concurrent diagnosis of AML. Cases of bone marrow mature pDC proliferation associated with AML are also included in this table.



**Table 3:** Reported AML cases with bone marrow pDC proliferation.

Author	Year	Number of cases	AML type	pDC	pDC phenotype	Karyotype	FISH	Molecular
Wang P et al.	2017	3 cases	AML-M4(1 case) AML-MRC (1 case), M4eo (1 case)	5-8%	CD4+ CD56dim CD123bri+ CD11c- CD304+ HLA-DR+ CD34- CD117- CD38-. No immature markers on all 3 cases	46XY 5q-, -18, +mar.(1 case), 48XY, +8, inv(16)(p13q22), +22(1 case). 46XY, inv(16)(p13q22) (1 case)	CBFb/MYH11 (2 case)	NA
Wang M et al.	2018	1 case	AMML	2.25%	CD123+HLA-DRst+ CD13dim+CD11bdim+ CD56+CD4+BDCA4+BDCA2-.	NA	NA	NA
Hama-dah F et al.	2019	6 cases	AMML (3 cases), AML unclassified (2 cases), mixed phenotype (1 case)	5-26%	CD123, CD303, CD304, CD22. CD34 expression dim to moderate, negative for CD56.	Trisomy 13 (1 case); Normal karyotype (2 cases), unknown (2 cases)		FLT3 ITD positive (2 cases)
Huang Y et al.	2020	13 cases	AML,un(3 cases), AML M4(6 cases), AML M5(4 cases)	>4%	myeloid blasts: CD34+/st+ CD117+/st+ BDCA2- BDCA4- CD123+ HLA-DR+/st+ CD4- CD45dim+; immature pDC: CD34dim+ CD117dim+ BDCA2-/dim+ BDCA4-/dim+ CD123st+ HLA-DR+/st+ CD4- CD45+	normal karyotype (5 cases), abnormalities in chromosome 7 (3 cases), abnormal chromosome 8 (2 cases), abnormal chromosome 20 (2 cases)	Del(20(1case), gain +8 (1 case)	FLT3-ITD mutation(3 cases), MLL-PTD (1 case)
Zhu. L et al.	2020	62 cases	AML M4/M5	2.8%	HLA-DRbri+CD123bri+ CD304+CD56+CD11c- CD33+CD15-CD14- CD64-CD34-CD117-CD38+.	NA	NA	NA
Gong. X. et al.	2021	2 cases	AML-M5(2 case),		CD123, HLA-DR, CD4, CD303, CD304, and negative for CD56, CD34, CD117, and TdT	normal karyotype (2 cases)	NA	BCOR, RUNX1, DNMT3A, NRAS
Zalmai L et al.	2021	15 cases	AML-M0 (11 cases), AML-M1 (1 case), AML-M4 (2 cases), AML-M5 (1 case)	4-36%	CD34+, CD303+, CD304+, CD4+, CD123 (low) and cTCL(low), aberrant CD22, CD5 and CD5	normal karyotype (10 cases), trisomy 13 (3 cases)		RUNX1 in all MO-AML (11 cases), not in all other AMLs
Xiao W et al.	2021	26 cases	de novo AML(12 cases), AML-MRC(12 cases), AML-T (2 cases)	2.2-35.9%	CD45(d), CD123(bright), and HLA-DR, CD303, CD4, CD123, some cases express CD56, CD34, CD5, CD13, CD2, CD33	NA	NA	Multiple mutations including RUNX1, NRAS, DNMT3, TET2 etc
Wang W. et al.	2022	53 cases	Unspecified	>2%	Heterogeneous, CD34 (96%), CD56(8%) and TCL1 (12%) and expression of CD4, CD13, CD22, CD25, CD36, CD38, CD117 and CD303 at various frequencies	NA		RUNX1 (64%), TET2 (21%), FLT3 (23%), DNMT3A (32%) and ZRSR2 (2%)

AML: acute myeloid leukemia; AML-MRC: acute myeloid leukemia with myelodysplasia-related changes; AML-T: acute myeloid leukemia related to chemotherapy; NA: Not available

### Differential Diagnosis with BPDCN and MPDCP Associated with other Myeloid Neoplasms

Our case is typical of pDC-AML with the characteristic flow cytometry immunohistochemistry phenotypic features. pDCs were readily identified by high expressions of CD123 and HLADR, and the immature nature of the pDCs was demonstrated by dim CD45 and dim CD34 expressions. CD303 expression, a specific marker for pDCs, performed by immunohistochemistry, confirmed the pDC proliferation. It is important to differentiate pDC-AML from BPDCN and Mature Plasmacytoid Dendritic Cell Proliferation (MPDCP) associated with other myeloid neoplasms since treatment for these disorders is quite distinct.

BPDCN is a distinctive entity recognized by the WHO since 2008 under plasmacytoid dendritic neoplasms [4]. The International Consensus Classification (ICC) of myeloid neoplasms and acute leukemias on BPDCN remains unchanged, while pDC-AML is not listed by the ICC. BPDCN arises from pDC precursors with a clinical presentation different from that in pDC-AML. Virtually all patients with BPDCN present with skin lesions, as well as lesions commonly involving the lymph nodes and bone marrow. Morphologically, the neoplastic cells are small or intermediate sized, often with a moderate amount of cytoplasm and an eccentric nucleus, and prominent nucleoli. Neoplastic cells in BPDCN express pDC-associated makers CD123, CD303 and TCF4.

CD123 is usually expressed at high level, compared with low-level expression in other hematologic diseases, including AML. BPDCN cells also express CD4, CD56 and TCL1 and sometimes aberrantly express CD2, CD5, CD7, CD33, CD38, CD68, CD117, HLADR and TdT [12]. Immature markers such as CD34 have not been reported in BPDCN but frequently seen in pDC-AML. pDCs in pDC-AML have maturation continuation from the myeloblasts. Gene mutations in BPDCN have been reported involving TET2, ASXL1, NRAS and ATM, while mutations in pDC-AML predominantly involve RUX1. Patients with BPDCN have historically been treated with systemic chemotherapy regimens like those used for AML, but more recently the approval of tagraxofusp [13] (a CD123-directed cytotoxin) for this population has resulted in significantly improved rates of remission success and allows many patients to transition to allogeneic transplant with curative intent. CAR-T therapy has also been used [14] to treat BPDCN, but data on pDC-AML treatment are still limited.

MPDCP associated with other myeloid neoplasms are clonal proliferations of pDCs, often seen with a nodular growth pattern in bone marrow, with low grade morphology. These mature pDCs express the normal phenotype with normal levels of CD123, CD303, CD304 expression, but without CD56 or CD34 and negative for TdT or CD2 or CD7 [15]. The associated myeloid neoplasm may be myeloproliferative CMML, MDS, MDS/MPN or AML, harboring activating RAS pathway mutations [4].

#### Implications for Flow Cytometry AML MRD

Flow cytometry AML MRD evaluation is an important part of diagnostic and prognostic evaluation. Many studies have shown that a positive flow cytometric MRD after induction and/or consolidation is correlated with an increased risk of relapse and worse survival [16]. The presence of MRD prior to allogeneic Hematopoietic Stem Cell Transplantation (HSCT) is an important predictor of relapse and survival [17]. MRD status can be used for risk stratification and clinical decision making for patients with AML. Multi-color flow cytometry, in conjunction with molecular and cytogenetic studies, are probably the most used approach to detect MRD in AML.

MRD detection by flow cytometry has a sensitivity of approximately  $10^{-3}$  to  $10^{-4}$  (0.1 to 0.01%). The interpretation of flow cytometry AML MRD, however, is still expert-based and the interpretation of AML MRD for pDC-AML is especially challenging for several reasons. Due to the rarity of pDC-AML and BPDCN, AML MRD panels currently employed in many institutions do not include pDC-specific markers, such as CD303. In addition, there is limited literature on AML MRD evaluation on BPDCN, restricting the dissemination of knowledge to experts. Wang et al. has developed an one-tube assay to evaluate MRD for BPDCN [18]. The one tube assay includes 10 CD markers: CD2, CD7, CD38, CD303, CD123, HLADR, CD64, CD4, CD45 and CD56. It has been validated to a sensitivity of 0.01%. They also reported that the differentiation between reactive pDCs and neoplastic pDCs can be challenging and largely relies on CD56 expression. Since pDCs in pDC-AML carry the same mutation as the myeloblasts (or stage 1 pDCs), one could argue that the MRD evaluation in pDC-AML should include the evaluation of both myeloblasts and the immature pDCs, rather than myeloblasts alone. Moreover, the monocytes in pDC-AML also have the same mutation as the myeloblasts and immature pDCs and are phenotypically abnormal. We observed aberrant CD2 and CD5 expressions on the monocytes in the initial bone marrow in our case. Should the evaluation of mature monocytes also be included in the AML MRD evaluation?

Detection of MRD by flow cytometry is achieved by detection of immunophenotypic aberrancies on leukemic blasts or blast equivalents by using either one or both of two partially overlapping analysis strategies: focusing on “Leukemia-Associated Immunophenotypes” (LAIP) detected at the time of diagnosis, and identifying any immunophenotypes which are “different-from-normal” in specimens submitted for MRD analysis. Like many others, we employ a strategy using a “different-from-normal” approach, in combination with the knowledge of the diagnostic LAIPs when available. In approximately 90% of AML patients, leukemic blasts at diagnosis show aberrant expression patterns of one or more LAIP antigens which differentiate them from normal myeloid precursors and other marrow cells. In our case, myeloblasts had aberrant CD7 and CD56 expressions that can serve as MRD evaluation for the follow up samples. Detecting MRD based only on LAIPs identified at the time of diagnosis can lead to some problems due to “immunophenotypic shift” at relapse that can occur in around 90% of AML [19]. The frequent antigenic drift or immunophenotypic switch during AML treatment makes LAIPs a “moving target” for MRD detection. “Different from-normal” is used to distinguish abnormal leukemic blasts from normal myeloid precursors irrespective of diagnostic LAIPs. Normal hematopoietic precursors show a tightly sequenced and predictable maturation pattern which can be visualized by flow cytometry. The knowledge of “normal expression,” usually obtained with a comprehensive control group including both normal and regenerating bone marrows, run in the same laboratory with the same MRD panel. In our case, the AML MRD performed one month post chemotherapy detected a population of immature pDCs (0.2% of total cells), based upon the CD123 positive and HLADR positive percentage, and these pDC appears to be immature with a subset expression of dim CD34. Further evaluation on these immature pDCs was limited due to the panel of CD marker selection in our AML MRD panels. The myeloblasts (0.4% of total cells) did not other display phenotypic aberrancy except dim subset CD7 and dim CD36. The determination of residual pDC-AML is difficult in this case. The minor phenotypic changes in the myeloblasts are considered likely phenotype shift related to chemotherapy.

Traditional molecular methods, such as quantitative PCR (qPCR) for AML MRD, rely on the molecular targets that can be amplified; over 40% of patients do not have an identifiable PCR target. NGS has recently been used to detect AML MRD gene mutations, and more than 90% of AML patients carry molecular alterations that serve well for NGS detection [20]. Using error corrected NGS, Thol et al. [20] and Patkar et al. [21] significantly increased the sensitivity of AML MRD detection. Press et al. [22] studied 42 AML patients using NGS method with a LLOD 0.24%. Our NGS test was validated at a LLOD at 5%, and not applicable for MRD detection. However, the pathogenic mutations of *RUNX1*, *ASXL1*, *EZH2* and *FLT3* present in the initial diagnostic marrow were suitable to track for residual and persistent disease. Presumably, the monocytes also carried these mutations in the initial diagnostic bone marrow. We found that monocytes (about 5%, around the level of our NGS LLOD) lost the phenotypic aberrancies, i.e. no expression of CD2 and CD5 at the one-month follow up bone marrow when AML MRD by flow cytometry was performed. Monocytic markers employed in our AML MRD panel (CD14, CD36, CD64, and CD163) did not display phenotypic aberrancies in the monocytes. NGS on the same follow up bone marrow sample did not detect the pathogenic gene mutations that were present in the initial bone marrow. These findings may suggest negative AML MRD results.

As pointed out by Paietta et al. in 2018 [23], the ideal AML MRD assay for each clinical situation will most likely depend on the individual patient's characteristics and the AML subtype. Our case illustrates that in pDC-AML, MFC and molecular study including NGS for MRD evaluation may be complementary. Even a NGS test without improved sensitivity or tailored for MRD detection might be useful.

### Conclusions

pDC-AML is a newly described subtype of acute myeloid leukemia, with immunophenotypic and molecular features distinct from BPDCN and MPDCP associated with other myeloid neoplasms. Flow cytometry identification of immature markers on pDCs and continuous maturation with the myeloblasts are important in the differential diagnosis. AML MRD by flow cytometry for pDC-AML may require certain considerations, such as the phenotype of pDCs and mature monocytes, but a molecular approach including NGS might be of help in the final AML MRD determination. Clinical, pathologic, and molecular correlations are important for a final diagnosis of this rare entity.

### References

- Zalmaï L, Viailly PJ, Biichle S, Cheok M, Soret L, et al. Plasmacytoid dendritic cells proliferation associated with acute myeloid leukemia: phenotype profile and mutation landscape. *Haematologica*. 2021; 106: 3056-66.
- Xiao W, Chan A, Waarts MR, Mishra T, Liu Y, et al. Plasmacytoid dendritic cell expansion defines a distinct subset of RUNX1-mutated acute myeloid leukemia. *Blood*. 2021; 137: 1377-91.
- Wang W, Xu J, Khoury JD, Pemmaraju N, Fang H, et al. Immunophenotypic and molecular features of acute myeloid leukemia with plasmacytoid dendritic cell differentiation are distinct from blastic plasmacytoid dendritic cell neoplasm. *Cancers (Basel)*. 2022; 14: 3375.
- Khoury JD, Solary E, Abla O, Akkari Y, Alaggio R, et al. The 5th edition of the World Health Organization Classification of Haematolymphoid Tumours: myeloid and Histiocytic/Dendritic Neoplasms. *Leukemia*. 2022; 36: 1703-19.
- Collin M, Bigley V. Human dendritic cell subsets: an update. *Immunology*. 2018; 154: 3-20.
- Rodrigues PF, Tussiwand R. Novel concepts in plasmacytoid dendritic cell (pDC) development and differentiation. *Mol Immunol*. 2020; 126: 25-30.
- Martín-Martín L, Almeida J, Hernández-Campo PM, Sánchez ML, Lécrevisse Q, et al. Immunophenotypic, morphologic, and functional characterization of maturation-associated plasmacytoid dendritic cell subsets in normal adult human bone marrow. *Transfusion*. 2009; 49: 1692-708.
- Huang Y, Wang Y, Chang Y, Yuan X, Hao L, et al. Myeloid neoplasms with elevated plasmacytoid dendritic cell differentiation reflect the maturation process of dendritic cells. *Cytometry A*. 2020; 97: 61-9.
- Dargent JL, Henne S, Pranger D, Balzarini P, Sartenaer D, et al. Tumor-forming plasmacytoid dendritic cells associated with myeloid neoplasms. Report of a peculiar case with histopathologic features masquerading as lupus erythematosus. *J Cutan Pathol*. 2016; 43: 280-6.
- Wang P, Feng Y, Deng X, Liu S, Qiang X, et al. Tumor-forming plasmacytoid dendritic cells in acute myelocytic leukemia: a report of three cases and literature review. *Int J Clin Exp Pathol*. 2017; 10: 7285-91.
- Gong X, Li C, Wang Y, Rao Q, Mi Y, Wang M, et al. Mature plasmacytoid dendritic cells associated with acute myeloid leukemia show similar genetic mutations and expression profiles to leukemia cells. *Blood Sci*. 2022; 4: 38-43.
- Khoury JD. Blastic plasmacytoid dendritic cell neoplasm. *Curr Hematol Malig Rep*. 2018; 13: 477-83.
- Pemmaraju N, Konopleva M. Approval of tagraxofusp-erzs for blastic plasmacytoid dendritic cell neoplasm. *Blood Adv*. 2020; 4: 4020-7.
- Adimora IJ, Wilson NR, Pemmaraju N. Blastic plasmacytoid dendritic cell neoplasm (BPDCN): A promising future in the era of targeted therapeutics. *Cancer*. 2022; 128: 3019-26.
- Hamadeh F, Awadallah A, Meyerson HJ, Beck RC. Flow cytometry identifies a spectrum of maturation in myeloid neoplasms having plasmacytoid dendritic cell differentiation. *Cytom B*. 2020; 98: 43-51.
- Qian Y, Wallace P, Maguire O, Minderman H. Flow cytometry for hematopoietic and lymphoid neoplasms. *Precision medicine: where are we and where are we going?* by Rina Kansal, MD 2023.
- Dix C, Lo TH, Clark G, Abadir E. Measurable residual disease in acute myeloid leukemia using flow cytometry: a review of where we are and where we are going. *J Clin Med*. 2020; 9: 1714.
- Wang W, Khoury JD, Miranda RN, Jorgensen JL, Xu J, et al. Immunophenotypic characterization of reactive and neoplastic plasmacytoid dendritic cells permits establishment of a 10-color flow cytometric panel for initial workup and residual disease evaluation of blastic plasmacytoid dendritic cell neoplasm. *Haematologica*. 2021; 106: 1047-55.
- Baer MR, Stewart CC, Dodge RK, Leget G, Sulé N, et al. High frequency of immunophenotype changes in acute myeloid leukemia at relapse: implications for residual disease detection (Cancer and Leukemia Group B Study 8361). *Blood*. 2001; 97: 3574-80.
- Thol F, Gabdoulline R, Liebich A, Klement P, Schiller J, et al. Measurable residual disease monitoring by NGS before allogeneic hematopoietic cell transplantation in AML. *Blood*. 2018; 132: 1703-13.
- Patkar N, Kakirde C, Shaikh AF, Salve R, Bhanshe P, et al. Clinical impact of panel-based error-corrected next generation sequencing versus flow cytometry to detect measurable residual disease (MRD) in acute myeloid leukemia (AML). *Leukemia*. 2021; 35: 1392-404.
- Press RD, Eickelberg G, Froman A, Yang F, Stentz A, et al. Next-generation sequencing-defined minimal residual disease before stem cell transplantation predicts acute myeloid leukemia relapse. *Am J Hematol*. 2019; 94: 902-12.
- Paietta E. Consensus on MRD in AML? *Blood*. 2018; 131: 1265-6.