

## Case Report

# Enormous Unilateral Primary Ovarian Leiomyoma Mimicking Ovarian Cancer with High Levels of Serum CA-125 and Ascites

Antovska V, Belchovska SE\*, Malahova Gjoreska I and Dabeski D

Univerzity Clinic for Gynecology and Obstetrics, Medical Faculty I Skopje, R. North Macedonia

\*Corresponding author: Sozovska Belchovska E, Univerzity Clinic for Gynecology and Obstetrics, Medical Faculty I Skopje, R. North Macedonia

Received: April 27, 2022; Accepted: May 23, 2022;

Published: May 30, 2022

## Abstract

Primary ovarian leiomyoma is a very rare benign tumor. We report a case of 61-year-old woman presenting with a large solid abdominal tumor and moderate ascites, as well as highly elevated serum CA-125. The patient was highly suspected for ovarian malignancy. This enormous ovarian tumor which was clinically diagnosed as a malignant ovarian mass, at surgery was presented as large ovarian fibroma, but on histology it was diagnosed as ovarian leiomyoma.

**Keywords:** Ascites; CA-125; Leiomyoma; Ovary

## Introduction

Leiomyoma is a benign smooth muscle tumor that most commonly affects the uterus, cervix and broad ligaments. [1]. The incidence of primary ovarian leiomyomas is particularly low. At present, less than 70 cases of primary ovarian leiomyomas have been reported worldwide [2]. These tumors account for 0.5-1 % of all benign ovarian tumors [3]. Because of their rarity, ovarian leiomyomas are not typically suspected before surgery or even during surgery. Accordingly, in several cases, surgeons have misdiagnosed ovarian leiomyomas as uterine myomas or even as malignant ovarian tumors. However, ovarian leiomyomas exhibit a benign nature pathology and have an excellent clinical prognosis.

Even more rarely, the ovarian leiomyoma can be accompanied with ascites, and then this finding strongly suggests that the ovarian tumor itself had either produced or induced the ascites. This rare symptom of massive ascites without peritoneal implants, is similar to that of Meigs' and pseudo-Meigs' syndromes, although such a case falls outside of their syndrome criteria because they lacked hydrothorax (pleural effusion).

True Meigs' syndrome is characterized by a triad of symptoms: abdominal ascites and right-sided pleural effusion associated with a benign ovarian tumor, most commonly a fibroma, but occasionally a fibroma-like Brenner or granulosa cell tumor [4,5]. A condition is termed "pseudo" Meigs' syndrome when it is associated with any other type of ovarian tumor, such as a mature teratoma, struma ovarii, metastatic ovarian tumor, or leiomyoma [6]. A rare "atypical" form of Meigs' syndrome can also occur; it is characterized by a benign pelvic mass with right-sided pleural effusion, but without ascites [7].

Infrequently, the tumor can be associated with increased CA-125 levels. The CA-125 antigen is a tumor marker produced by many tissues, such as: epithelium of the fallopian tubes, endometrium, endocervix, ovaries, and mesothelial cells of the pleura, pericardium and peritoneum. It can be elevated during some physiologic conditions such as menstruation or pregnancy and in some benign conditions such as endometriosis, peritonitis, cirrhosis with ascites,

PID, uterine leiomyoma, pleuritis, pericarditis and peritonitis, but also in malignant ovarian tumors due to inflammation associated with malignancy [8].

We report an interesting case of an enormous ovarian leiomyoma with presence of ascites and highly elevated CA-125 that simulated ovarian malignancy.

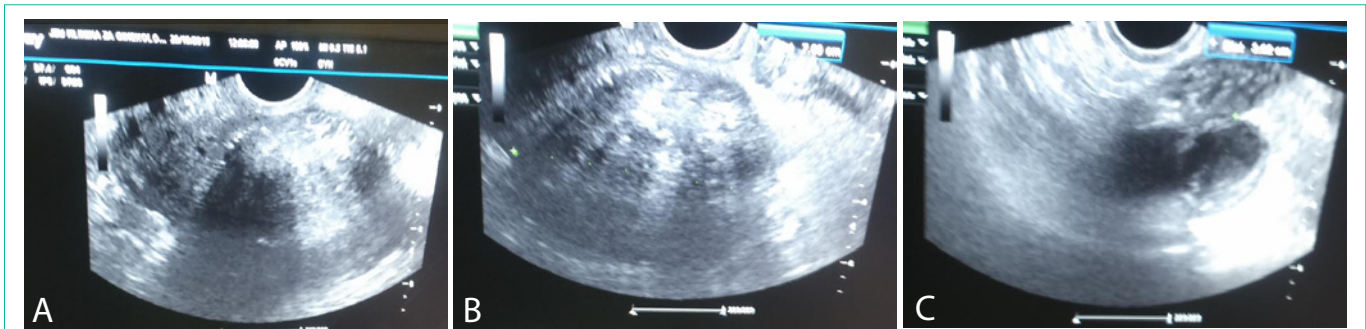
## Case Presentation

A 61-year-old postmenopausal woman referred to the hospital with abdominal pain and previously diagnosed abdominal solid mass.

Gynecological exam had shown a uterine cervix without abnormalities. However, a big, solid pelvic mass, behind the uterus, in central position was palpated. Ultrasonography revealed an enormous solid mass in pelvic midline with dimension of 100×109 mm, as well as ascites. The tumor marker CA-125 was highly elevated (>500 IU/mL), but other tumor markers were within the normal range. Liver function, thyroid and kidney tests were normal. Chest x-ray (CXR) excluded a pleural effusion.

The scoring system ROMI showed low risk for ovarian carcinoma, e.g., ROMI =10 points: age of senium (1 point), tumor size ≥6cm (1 point), solid tumor (0 point), serum levels of CA-125 >130 U/ml (5 points), presence of the ascites only within pelvis cavity (3 points) [9]. Doppler examination showed Resistance Index (RI) = 0,71 did not indicated malignant nature of the tumor. So, the suspicion for benign pathology and big uterine myoma or ovarian fibroma was made.

The patient was submitted to exploratory laparotomy. Firstly, the ascites was drained, which was clear, yellowish. Afterwards, 100×110 cm solid, yellow mass was detected in the place of her right ovary, which was attached loosely to bowel, colon and the bottom of pelvis. The tumor was gently removed and sent, alongside the peritoneal fluid to pathology examination. The mass was occupying pelvic and abdominal cavities and did not show infiltration to the adjoining structures. Uterus and left adnexa, as well as the peritoneum were macroscopically without any pathological deposits and no pelvic and paraaortic lymphadenopathy was detected. Hysterectomy with



**Figure 1:** Ultrasound of the patient with enormous ovarian myoma: slide A and B present big solid tumor into the pelvis; slide C presents the ascites.

bilateral adnexectomy was performed. (Figure1A)

Postoperative histology confirmed benign ovarian leiomyoma and normal cytology from peritoneal fluid sampling. Cut surfaces of the specimen showed multiloculated cysts containing haemorrhage and blood clots, and there was also a small solid part that appeared whorled and myxoid (Figure1B). Haematoxylin and Eosin (H&E) - stained sections of the tumour tissue showed multiple pseudocystic spaces, surrounded by spindle cells of variable cellularity (Figure 1C). The pseudocystic spaces lacked a true epithelial lining and contained edema fluid and red cells in the lumina. In highly cellular areas, spindle cells were arranged in interlacing fascicles whereas this arrangement was lost in more edematous, degenerated and hypocellular areas. The spindle-shaped cells had regular, elongated, blunt-ended nuclei and eosinophilic cytoplasm, resembling leiomyoma. Significant nuclear atypia, nuclear pleomorphism and mitotic activity were absent. Considerable part of the tumour showed degenerative changes viz., cystic degeneration, myxoid degeneration with multiple foci of hemorrhage, thrombosis and necrosis. Multiple sections examined from the mass did not show remnant ovarian tissue. Omental fat and attached fallopian tube did not show any significant pathological changes. Immunohistochemistry performed on few tumor sections showed moderate to strong diffuse cytoplasmic positivity for desmin and Smooth Muscle Actin (SMA).

After surgery, all symptoms disappeared, ascites resolved and the patient was discharged from the hospital on the 7<sup>th</sup> postoperative day. One month after surgery, CA-125 level decreased within the normal range ( $\leq 35$  IU/mL).

## Discussion

Ovarian leiomyoma can be classified into 2 types: primary and secondary. Primary ovarian leiomyoma, the type that was found in our case is mainly derived from ovarian tissues, and most certainly from smooth muscle cells in the walls of ovarian vessels [10]. Other theories have shown that its origin can also be from smooth muscle cells in the ovarian ligament, or the ovarian stroma, the undifferentiated reproductive cells and cortical smooth muscle cells, or the smooth muscle cells in the smooth muscle metaplasia or ovarian endometriosis [11-15].

The tumor usually has no clinical symptoms, and patients visit a doctor generally due to the discovery of lower abdominal masses during physical examination, or in our case because of abdominal pain [10].

Due to the rare nature and variability of ovarian leiomyoma, preoperative imaging diagnosis is often difficult, and the diagnosis depends on postoperative pathology and immunohistochemistry. Typical imaging methods include ultrasonography, CT, and magnetic resonance imaging (MRI) [10]. In our case, only ultrasonography was performed. We were pretty sure of its benign nature due to the low-score ROMI in spite that the tumor resembled as ovarian cancer with presence of pseudo-Meigs syndrome and high levels of CA-125.

The pathogenesis of ascites and pleural effusion in patients with Meigs syndrome or pseudo-Meigs syndrome remains uncertain. Meigs suggested that irritation of the peritoneal surfaces by a solid ovarian tumor could stimulate ascites production [16]. Some authors reported that peritoneal fluid might be secreted by the tumor itself, since observing that large tumors ( $>10$ cm) containing a myxoid component within the stroma, were often associated with ascites [17]. Other mechanisms, such as inflammatory reactions, hormonal stimulation, toxin release, and low serum protein levels, have also been suggested [18]. In addition, release of various mediators from tumors might promote capillary permeability, leading to ascites such as VEGF and Interleukin (IL)-1 beta, IL-6, IL-8, and Tumor Necrosis Factor (TNF)-alpha [19,20].

Because CA-125 is expressed in various tissues and an increase in CA-125 serum levels is present in a variety of clinical conditions, its high levels do not necessarily indicate malignancy. Peritoneal mechanical stimulation exerted by the uterine myoma or by the presence of substantial ascites also increases CA-125 [21]. Finally, cytokines released from necrotic or degenerative tissues can cause peritoneal inflammation and increase CA-125 [22-24]. This was also shown in our patient, where after removal of ascites and myoma, serum CA-125 level rapidly decreased.

## Conclusion

Benign ovarian tumor is a rare cause of pleural effusion, ascites, and pelvic mass associated with elevated CA-125 levels. This condition suggests malignant ovarian tumor, particularly in menopausal women. Nevertheless, in every patient presenting with abovementioned symptoms, Meigs' or pseudo-Meigs' syndrome should be considered, since this condition is easily treated only by removing the tumor. After complete resection, ovarian leiomyoma rarely recurs, postoperative adjuvant therapy is not required, and the prognosis is good.

## References

1. Robboy SJ, Mutter GL, Prat J, Bentley RC, Russell P, Anderson MC.

- Robboy's pathology of the female reproductive tract. 2nd Ed. New York: Churchill Livingstone Elsevier. 2009.
2. Yoshitake T, Asayama Y, Yoshimitsu K, Irie H, Aibe H, Tajima T, et al. Bilateral ovarian leiomyomas: CT and MRI features. *Abdom Imaging*. 2005; 30: 117-119.
  3. Doss BJ, Wanek SM, Jacques SM, Qureshi F, Ramirez NC, Lawrence WD. Ovarian leiomyomas: clinicopathologic features in fifteen cases. *Int J Gynecol Pathol*. 1999; 18: 63-68.
  4. Meigs JV. Fibroma of the ovary with ascites and hydrothorax-Meigs' syndrome. *Amer J Obstet Gyn* 1954; 67: 962-987.
  5. Rowlands BC, Garrett JV, King PA. "Meigs' syndrome: a brief review of the condition and report of a case associated with a Brenner tumour." *British J Surg*. 1954; 41: 645-648.
  6. Meigs JV. Pelvic tumors other than fibromas of the ovary with ascites and hydrothorax. *Obstet Gyn*. 1954; 3: 471-486.
  7. Thaker DA, Stride PJ, Detrick A. A pseudo case of atypical pseudo-Meigs syndrome. *Indian J Cancer* 2011; 48: 364-366.
  8. Jiang W, Lu X, Zhu ZL, Liu XS, Xu CJ. Struma ovarii associated with pseudo-Meigs' syndrome and elevated serum CA 125: a case report and review of the literature. *J Ovarian Res*. 2010; 3:18.
  9. Antovska V, Trajanova M. An original risk of ovarian malignancy index and its predictive value in evaluating the nature of ovarian tumour. *SAJGO*. 2015; 7: 52-59.
  10. Wang QM, Zhao Y, Ma Y, Yao LT, Han X. One case report of giant atypical leiomyoma of the ovary. *Medicine (Baltimore)*. 2018; 97: e12526.
  11. Wei C, LilićN, Shorter N, Garrow E. Primary ovarian leiomyoma: a rare cause of ovarian tumor in adolescence. *J Pediatr Adolesc Gynecol*. 2008; 21: 33-36.
  12. Sanverdi I, Vural F, Temizkan O, Temel O, Ayvaci H, Gunes P. Primary ovarian leiomyoma in a postmenopausal woman: a case report. *North Clin Istanb*. 2016; 3: 222-224.
  13. Lerwill MF, Sung R, Oliva E, Prat J, Young RH. Smooth muscle tumors of the ovary: a clinicopathologic study of 54 cases emphasizing prognostic criteria, histologic variants, and differential diagnosis. *Am J Surg Pathol*. 2004; 28: 1436-1451.
  14. Hsiao CH, Wang HC, Chang SL. Ovarian leiomyoma in a pregnant woman. *Taiwanese J Obstetr Gynecol*. 2007; 46: 311-313.
  15. Blue NR, Felix JC, Jaque J. Primary ovarian leiomyoma in a premenarchal adolescent: first reported case. *J Pediatr Adolesc Gynecol*. 2014; 27: 87-88.
  16. Yaguchi A, Ban K, Koshida Y, Fujikami Y, Ogura E, Terada A, et al. Pseudo-Meigs Syndrome Caused by a Giant Uterine Leiomyoma with Cystic Degeneration: A Case Report. *J Nippon Med Sch*. 2020; 87: 80-86.
  17. Samanth KK, Black WC 3<sup>rd</sup>. Benign ovarian stromal tumors associated with free peritoneal fluid. *Am J Obstet Gynecol*. 1970; 107: 538-545.
  18. Rubin IC, Novak J, Squire JJ. Ovarian fibromas and theca-cell tumors: report of 78 cases with special reference to production of ascites and hydrothorax (Meigs' Syndrome). *Am J Obstet Gynecol*. 1944; 48: 601-661.
  19. Ishiko O, Yoshida H, Sumi T, Hirai K, Ogita S. Vascular endothelial growth factor levels in pleural and peritoneal fluid in Meigs syndrome. *Eur J Obstet Gynecol Report Biol*. 2001; 98: 129-130.
  20. Abramov Y, Anteby SO, Fasouliotis SJ, Barak V. Markedly elevated levels of vascular endothelial growth factor, fibroblast growth factor, and interleukin 6 in Meigs syndrome. *Am J Obstet Gynecol*. 2001; 184: 354-355.
  21. Amant F, Gabriel C, Timmerman D, Vergote I. Pseudo-Meigs' syndrome caused by a hydropic degenerating uterine leiomyoma with elevated CA125. *Gynecol Oncol*. 2001; 83:153-157.
  22. Abramov Y, Anteby SO, Fasouliotis SJ, Barak V. The role of inflammatory cytokines in Meigs' syndrome. *ObstetGynecol*. 2002; 99: 917-919.
  23. Mitrou S, Manek S, Kehoe S. Cystic struma ovarii presenting as pseudo-Meigs' syndrome with elevated CA125 levels. A case report and review of the literature. *Int J Gynecol Cancer*. 2008; 18: 372-375.
  24. Chhavi K, Akhila P, Yashvant S, Baruah BP. Case series: Cystic degeneration in uterine leiomyomas. *Indian J Radiol Imag*. 2008; 18: 69-72.