

## Case Report

# Urethral Condylomata Five-Year-Old Child: A Case Report

Boudoux SQSB<sup>1</sup>, Jesus RVS<sup>1</sup>, Sarno M<sup>2</sup>, Passos I<sup>3</sup> and Britto RL<sup>2,3\*</sup>

<sup>1</sup>University of Salvador, Argentina

<sup>2</sup>Federal University of Bahia, Brazil

<sup>3</sup>University Hospital, UFBA, Brazil

\*Corresponding author: Renata Britto, Federal University of Bahia, Physician at the University Hospital, Professor Edgard Santos, UFBA3, Brazil

Received: June 10, 2016; Accepted: July 13, 2016;

Published: July 15, 2016

## Abstract

**Introduction:** Condyloma Acuminata (CA) is the current most prevalent sexually transmitted disease by Human Papillomavirus type 1. Brazil does not have statistics on the prevalence of HPV infection in the sexually active population; however the Adolfo Lutz Institute in São Paulo recorded a rate of 16.4% of HPV infection by Polymerase Chain Reaction in asymptomatic women.

**Case:** Five-year-old girl, met at University Hospital Professor Edgar Santos (HUPES) in April, 2015 complaining of tumor in vulva for three months. The examination showed vegetating lesion externalizing up through the urethra, with intact hymen. The patient was referred to urology and the lesions were biopsied, with further diagnostic of Condyloma.

**Discussion:** Care services for children and adolescents have reported a large number of Condyloma lesions in three to six-year-old girls, which coincide with other published reports claiming that anogenital warts caused by HPV infection are not commonly diagnosed in children. However, when these lesions are seen they usually result from non-sexual transmission and may be the most common mode of transmission among children under three years of age.

**Conclusion:** Although sexual abuse should be considered, caution is advised in interpreting the implications of genital or anal warts in cases beyond the neonatal period. The diagnosis is based on the appearance of lesions along with histological study and identification of suggestive HPV infection changes, as long as other possible injuries that is part of the differential diagnosis with inflammatory lesions.

**Keywords:** Condyloma; HPV; Genital injury; Child

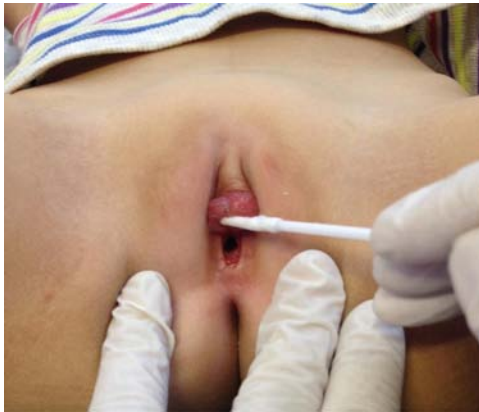## Introduction

Condyloma Acuminata (CA) is the current most prevalent sexually transmitted disease by Human Papillomavirus type 1. Until 1976, Condyloma acuminata was rarely diagnosed, except for the presence of warty lesions on the external genitals which are easily identified [7]. Spontaneous remission is observed in approximately 30% of cases of Condyloma but the flat lesions, most often found in the cervix, may regress, persist or progress, in low percentage, to invasive cancer.

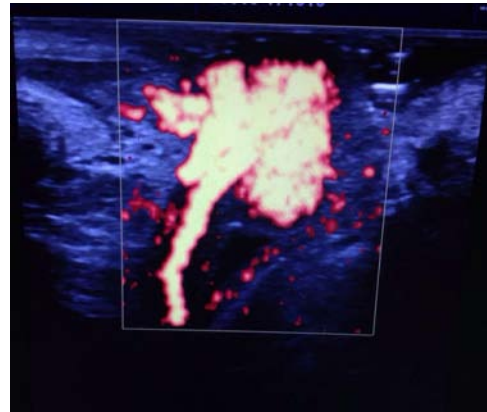
The remission rates depend on the viral type and oncogenic potential. The infection has various clinical presentations, most often asymptomatic and transient and only 2% of cases progress to intraepithelial neoplasia and cancer. In this scenario, the susceptibility factors for neoplastic transformation such as the presence of oncogenic HPV, particularly types 16 and 18, are relevant to the formation of vegetating lesions [1]. The Human Papilloma Virus (HPV) is ranked among the most potent carcinogens in humans, accounting for 5% of all cancers in the world, a rate that could reach 15% of cancers in women. It is estimated that 80% of women will get some form of HPV up to 50 years of age [1]. Brazil does not have statistics on the prevalence of HPV infection in the sexually active population; however the Adolfo Lutz Institute in São Paulo recorded a rate of 16.4% of HPV infection by Polymerase Chain Reaction in

asymptomatic women [3]. Children and adolescents infected are potentially at risk to develop consequences such as ectopic pregnancy and tubal infertility, as well as Cervical Intraepithelial Neoplasia (CIN), Vulvar Intraepithelial Neoplasia (VIN), and Vaginal Intraepithelial Neoplasia (VAIN), Immunodeficiency Syndrome (AIDS) and tertiary syphilis, and in the end tubal infertility. Regarding the last consequence listed, we must emphasize that the present therapeutic methods involving chemical destruction (ATA 50% or podophyllin 25%) or mechanical destruction (criocauterization, electrocautery or diathermy handle) of the lesions provide the disadvantage of being painful and leaving consequences such as cervical Isthmus or cervical stenosis which can lead to infertility [1].

Several authors have shown the presence of HPV in amniotic fluid, skin and oropharynx of newborns at up to 73% of cases. Despite the high rates, is not observed large proportion of children with injuries as would be expected if all contamination resulted in injury. However, these cases are sporadic and are reflected by the presence of warts on the external genitals of babies and preschoolers, and recurrent juvenile papillomatosis characterized by lesions in oropharynx [4]. A study of 42 prepubertal children with anogenital Condyloma found that 28, 6% have acquired HPV by vertical transmission, 7.1% of autoinoculation warts located on the hands, and only 4.8% were associated with sexual abuse. The HPV transmission mode was inconclusive in 59.5% of the children studied. Thus, it is not possible



**Figure 1:** Tumor occupying Urethral Meatus.



**Figure 2:** Doppler showing tumor pedicle in urethra, hypervascularised.

to relate the infection with sexual abuse [2].

## Case Presentation

Five-year-old girl, treated at the University Hospital Professor Edgard Santos in April 2015 with complaint of tumor in vulva for three months. At the examination, it was identified a vegetating lesion externalizing from the urethra, with an intact hymen. The vaginal opening gynecological examination did not show any injury and the urethral opening was fully occupied with the output of the tumor that had aspect of a 'bunch of grapes' with approximately 2.5 cm in diameter (Figure 1). The ultrasound Doppler showed vegetating lesion, pedunculated in the urethra with the Doppler blood flow (Figure 2). A lesion fragment was removed and the material was sent for pathological studies, as well as the collection of material for hybrid capture and identification of the subgroup of the Human Papilloma virus (HPV). The biopsy was compatible with Condyloma Acuminado and the result of the hybrid capture was positive for HPV: Group A and Group B 40.2 Positive, Negative 0.2. Facing the HPV positivity the child protection agency was notified to rule out any possibility of sexual abuse. The children lived with their grandparents and there was no evidence or history of sexual abuse.

## Discussion

Sexual abuse has been considered the main mode of transmission and some authors consider that the mere presence of Condyloma in children may be an indication that there is sexual abuse [10]. There is also consistent evidence in the literature associating HPV infection with situations involving sexual crimes [2]. However, most studies argue that HPV infection does not necessarily result from sexual contact and that other forms of contamination must be considered [9]. Child and adolescent services have reported a large number of Condyloma lesions in girls between the ages of 3-6 years old. This phenomenon coincides with other published reports claiming that anogenital warts caused by HPV infection are not commonly diagnosed in children. The most common form of transmission among children under 3 years old is not sexual, eventually may correspond to cases of abuse. Knowledge about the natural history of HPV infection and its transmission mechanisms, as well as factors related to the sexual abuse of children, are necessary for the proper management of these cases. In addition to the contamination through sexual abuse, transmission of HPV can also occur vertically - Maternal

history of vulvar Condyloma or squamous intraepithelial cervical lesions at delivery was observed in 50.3% of children under nine years old that presented different clinical forms of the disease [8] - or by self-inoculation of warts located on the hands for example. Given that HPV has a long period of latency in cases of vertical transmission, the discovery of anogenital warts happens early in life and not soon after birth which confirms the initial suspicion of sexual abuse.

Regarding HPV infection, several authors have demonstrated the presence of HPV in amniotic fluid and the skin and oropharyngeal newborns at up to 73% of cases. Despite the high rates, is not observed large proportion of children with injuries as would be expected if all contamination resulted in injury. However, these cases are sporadic and are reflected by the presence of warts on the external genitals of babies and preschoolers, and recurrent juvenile papillomatosis characterized by oropharyngeal lesions [4]. A study of 42 prepubertal children with anogenital Condyloma found that 28.6% have acquired HPV by vertical transmission, 7.1% of autoinoculation warts located on the hands, and only 4.8% were associated with sexual abuse. The HPV transmission mode was inconclusive in 59.5% of the children studied. Thus it is not possible to relate the infection with sexual abuse [2].

Regarding the relation between sexual abuse and HPV infection, the outcome is variable, occurring in 0.1% to 70% of children with genital warts [10]. The most common site of the appearance of Condyloma in children is the perianal region and may extend to the anal canal. Particularly in girls, it can be found periurethral injuries, hymenal and vaginal wishbone performing irregularly or as multiple small papules, extending to large and small vaginallips. The differential diagnosis includes Condyloma plan of secondary syphilis, molluscumcontagiosum, pemphigus Chronic benign, histiocytosis X, neurofibromatosis, rhabdomyosarcoma (botryoid sarcoma) [2].

## Conclusion

The association between the displayed studies and presented case showed that although the HPV virus is strongly connected to horizontal transmission by direct sexual contact, other modes of contamination are being studied worldwide. Although sexual abuse should be considered, caution is recommended in interpreting the implications of genital or anal warts in cases beyond the neonatal period.

The incidence of anogenital Condyloma acuminado in children has increased significantly over the past two decades, as well as the interest in its association with sexual abuse [6]. A study with prepubertal children with anogenital Condyloma found that 28.6% have acquired HPV by vertical transmission, 7.1% resulted from autoinoculation of verugas located in hand and 4.8% associated with sexual abuse [6]. The rest of the results were inconclusive not making it possible to rule out its relationship to sexual violence.

Thus, when talking about HPV infection in children and the onset of warty lesions being proven the absence of sexual abuse of the infant, other types of HPV transmission should be considered. In infants who already have important vegetating lesion vertical transmission mode should be investigated for having contact with virus long enough for the growth of condylomatous wart. Injuries of any kind resulting from sexually transmitted diseases should not be neglected in the presence of any injury or infectious disease which the identified transmission agent is the same that causes STDs. In these cases, it is necessary to trigger available social work and investigate the situation in which the infant is exposed to discard the possible abuse.

The diagnosis is based on the appearance of lesions along with histological study and identification of suggestive HPV infection changes, as long as other possible injuries that are part of the differential diagnosis with inflammatory lesions. None of the currently available treatments can eradicate the virus, eliminate the warts, or prevent recurrence. However, there is a high spontaneous resolution rate over two years.

## References

1. Prevalência do Vírus Papiloma Humano e Outras Doenças Sexualmente Transmissíveis no Ambulatório de Ginecologia Infanto-Puberal Na Santa Casa da Misericórdia do RJ. *Revista Oficial Do Núcleo De Estudos Da Saúde Do Adolescente / UERJ*. 2011; 8.
2. Jefferson Drezzette et al. Transmissão De Verrugas Anogenitais Em Crianças E Associação Com Abuso Sexual. *Journal of Human Growth and Development*. 2012; 22: 1-11.
3. Charles Rosenblatt, Antonio Marmo, Lucon Eric Roger Wroclawski. HPV Livro: 3. Patogênese e a Importância do Homem Como Transmissor. Disponível em.
4. José Aristodemo Pinotti, Marcos Desidério Ricci. HPV Livro: 19. Panorama do HPV no Brasil e no Mercosul. Disponível em.
5. Nita Jain. Sexually transmitted diseases in the pediatric patient Issue: *BCMJ*. 2004; 46: 133-138.
6. de Sanjose S, Diaz M, Castellsague X, Clifford G, Bruni L, Munoz N et al. Worldwide prevalence and genotype distribution of cervical human papillomavirus DNA in women with normal cytology: a meta-analysis. *Lancet Infect Dis*. 2007; 7: 453-459.
7. Gerson Botacini das Dores. HPV Livro: 1. Epidemiologia do HPV. Disponível em.
8. Jones V, Smith SJ, Omar HA. Nonsexual transmission of anogenital warts in children: a retrospective analysis. *Scientific World Journal*. 2007; 7: 1896-1899.
9. Vanhootheghem O, Müller G, de la Brassinne M. Anogenitalcondylomata in the children. Practice guidelines for a medical expertise. *Rev Med Liege*. 2007; 62: 151-154.
10. Wright CA, Taylor L, Cooper K. HPV typing of vulvovaginal condylomata in children. *S Afr Med J*. 1995; 85: 1096-1101.