

Case Report

Sister Mary Joseph Nodule: A Presenting Sign of Pancreatic Cancer

Davis WD*, Reddy SP and Collier RC

Department of Internal Medicine, Medstar Georgetown University Hospital, USA

*Corresponding author: Davis WD, Department of Internal Medicine, Medstar Georgetown University Hospital, 3800 Reservoir Rd NW, Washington, DC 20007, USA

Received: December 04, 2020; Accepted: December 26, 2020; Published: December 31, 2020

Abstract

Pancreatic cancer is associated with a poor prognosis, as it is often not diagnosed until advanced disease. Common manifestations of pancreatic cancer include abdominal pain, weight loss, jaundice, pruritus, and acholic stools. A rare clinical sign of advanced pancreatic cancer is a periumbilical mass known as Sister Mary Joseph Nodule; SMJN. In this case, we describe a 51-year-old female with abdominal pain and weight loss found to have a periumbilical mass that was proven to be metastatic pancreatic adenocarcinoma upon *in vivo* biopsy.

Keywords: Pancreatic Adenocarcinoma; Sister Mary Joseph Nodule; Periumbilical Mass

Introduction

Pancreatic cancer is the fourth leading cause of cancer-related deaths in the United States. Common manifestations include weight loss, jaundice, pruritus and acholic stool. Here we present a rare finding of a periumbilical mass otherwise known as a SMJN in the setting of newly diagnosed metastatic pancreatic adenocarcinoma.

Case Report

A 51-year-old woman with a history of hypertension, diabetes, and hyperlipidemia presented with worsening abdominal pain and 85 lb weight loss over the last 7 months. She also described a worsening painful “lump” in her abdomen over a similar period that progressively increased in size and pain. She admitted fatigue, intermittent night sweats, and reduced oral intake. Two days prior to presentation, the patient experienced diffuse, burning, pleuritic chest pain. On admission, her vitals were stable. EKG and troponins were negative for ischemic heart disease. Significant labs were alkaline phosphatase 391u/L, white blood cell count 12.6k/ul, hemoglobin A1c of 13.6%, alpha-fetoprotein 5.7ng/ml, carcinoembryonic antigen level of 227ng/ml, and cancer antigen 19-9 over 980,000 IU/ml. Computer Tomography; CT of the abdomen and pelvis with contrast demonstrated a 4x4 cm pancreatic mass within the distal body and tail along with diffuse liver lesions (Figure 1), enlarged porta hepatis lymph nodes and an abdominal wall mass concerning for metastatic disease (Figure 2). Lower extremity duplex ultrasound showed a deep venous thrombosis in the left gastrocnemius vein and CT chest with contrast showed subsegmental pulmonary emboli involving right middle lobe and bilateral lower lobes along with few subcentimeter pulmonary nodules concerning for further metastatic disease.

The patient was placed on heparin infusion for new findings of pulmonary embolism and interventional radiology was consulted for tissue samples of umbilical lesion concerning for metastatic pancreatic cancer based on CT findings. Biopsy was completed and demonstrated metastatic adenocarcinoma, consistent with pancreatic origin. Patient was discharged with low molecular weight heparin for pulmonary embolism treatment and has since followed up with Oncology as an outpatient with plans to initiate chemotherapy with

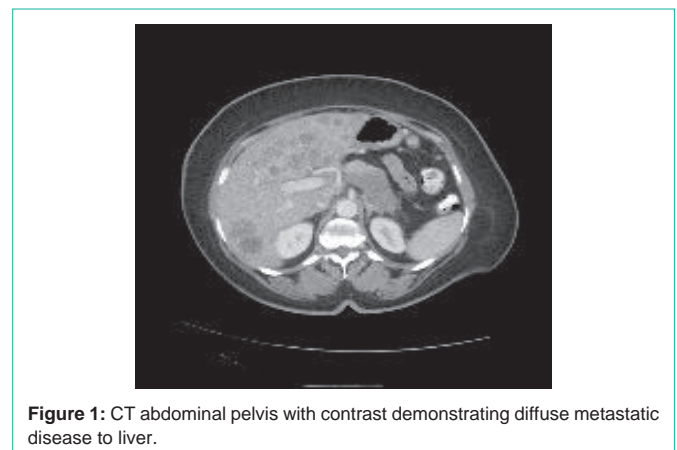


Figure 1: CT abdominal pelvis with contrast demonstrating diffuse metastatic disease to liver.

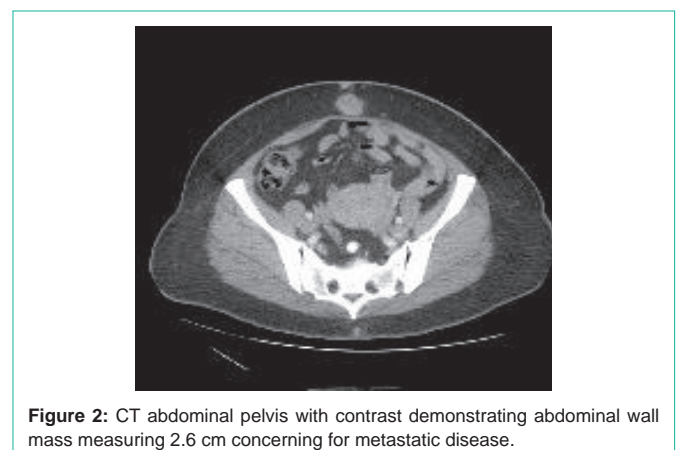


Figure 2: CT abdominal pelvis with contrast demonstrating abdominal wall mass measuring 2.6 cm concerning for metastatic disease.

gemcitabine and abraxane.

Discussion

Here we discussed the physical finding of a SMJN; a rare and clinically significant exam finding of pancreatic cancer. SMJN can present as umbilical or periumbilical nodules and range widely in size from 0.5 to 15 cm. These nodules typically are firm and can

occasionally be painful and fluid-containing [1]. An umbilical mass may represent many different underlying pathologies such as dermoid cysts, polyps and benign tumors [2]. Though incidence is low (rate of cancers leading to SMJN is 1-3%), malignant tumors must also be considered [3]. Primary and secondary malignant lesions account for more than a third of umbilical tumors with the majority of secondary cancers arising from a primary gastrointestinal tract malignancy [2,4]. Pancreatic cancer accounts for approximately 6% [5].

Umbilical metastasis can arise from multiple modalities including lymphatic spread, hematologic spread, or direct extension [5]. In patients this may be the only presenting symptom as early stages of pancreatic cancer are typically clinically silent and thus approximately 50% of patients are found to have advanced disease at diagnosis [6,7]. This symbolizes a poor prognostic factor in an already extremely deadly cancer with a median survival of 3-6 months [8]. Management of advanced disease is limited and depends on the functional status of the individual emphasizing the significance of early diagnosis [6]. In those with good functional status, chemotherapy is the mainstay of treatment [6]. In one particular study, SMJN patients that received more aggressive surgery and chemotherapy had better survival outcomes than SMJN patients who did not receive this treatment course [9].

An umbilical nodule in itself is an ambiguous exam finding and clinical context is warranted in distinguishing whether it is associated with benign or malignant disease. In this case, this patient had accompanying weight loss, significant abdominal pain, night sweats, and reduced oral intake, making malignancy more likely. CT imaging and fine needle aspiration of the umbilical nodule were necessary tools for SMJN diagnosis [10]. In the setting of advanced disease and good functional status, chemotherapy was offered to the patient with gemcitabine and abraxane. This case reinforces the importance of history taking and physical exam to help aid in identifying early

symptoms and findings of pancreatic cancer. As pancreatic cancer is often diagnosed in an advanced state, any tool that may enhance one's clinical suspicion and elicit a prompt diagnosis is invaluable as early diagnosis and timely initiation of surgery/chemotherapy has proven to lead to improved patient outcomes [9].

References

1. Tso S, Brockley J, Recica H, Ilchysyn A. Sister Mary Joseph's nodule: An unusual but important physical finding characteristic of widespread internal malignancy. *Br J Gen Pract.* 2013; 63: 551-552.
2. Prabhu R, Krishna S, Shenoy R, Natarajan A. Pancreatic cancer presenting as a Sister Mary Joseph's nodule. *BMJ Case Rep.* 2013: 4-6.
3. Ota S, Haruyama T, Ishihara M, Natsume M, Fukasawa Y, Sakamoto T, et al. A Patient with Advanced Gastric Cancer Who Achieved a Long-Term Prognosis by Early Diagnosis of Sister Mary Joseph's Nodule. *Case Rep Oncol.* 2018; 11: 11-16.
4. Bai XL, Zhang Q, Masood W, Masood N, Tang Y, Cao CH, et al. Sister Mary Joseph's nodule as a first sign of pancreatic cancer. *World J Gastroenterol.* 2012; 18: 6686-6689.
5. Crescentini F, Deutsch F, Sobrado CW, Araujo S de. Umbilical mass as the sole presenting symptom of pancreatic cancer: a case report. *Rev Hosp Clin Fac Med Sao Paulo.* 2004; 59: 198-202.
6. Hidalgo M. Pancreatic Cancer : Overview. *Lancet.* 2010; 362: 1605-1617.
7. Ansari D, Tingstedt B, Andersson B, Holmquist F, Stureson C, Williamsson C, et al. Pancreatic cancer: Yesterday, today and tomorrow. *Futur Oncol.* 2016; 12: 1929-1946.
8. Freelove R, Walling AD. Pancreatic cancer: Diagnosis and management. *Am Fam Physician.* 2006; 73: 485-492.
9. Majmudar B, Wiskind AK, Croft BN, Dudley AG. The Sister (Mary) Joseph nodule: Its significance in gynecology. *Gynecol Oncol.* 1991; 40: 152-159.
10. Dar IH, Kamili MA, Dar SH, Kuchhai FA. Sister Mary Joseph Nodule: An unusual case report with review of literature. *Internet J Dermatology.* 2009; 7: 385-387.