

Clinical Image

Complications due to Biliary Stent Deviation

Kinoshita K^{1*}, Fukuchi S^{1,2} and Murakami K¹

¹Department of Gastroenterology, Oita University, Oita, Japan

²Department of Gastroenterology, Almeida Memorial Hospital, Oita, Japan

*Corresponding author: Keisuke Kinoshita, Department of Gastroenterology, Oita University, 1-1 Idaigaoka, Hasama, Yufu, Oita 879-5593, Japan

Received: April 14, 2021; Accepted: May 04, 2021;

Published: May 11, 2021

Clinical Image

We often encounter complications from biliary stents used as a treatment for obstructive jaundice and acute cholangitis. Early complications after stent placement include pancreatitis, bleeding, and duodenal perforation [1].

Stent deviation is also a complication. This is particularly prominent for plastic stents, where stent deviation is observed in 6-18.7 % of cases [2]. Stent deviation is more common among patients who have undergone endoscopic sphincterotomy (Figure

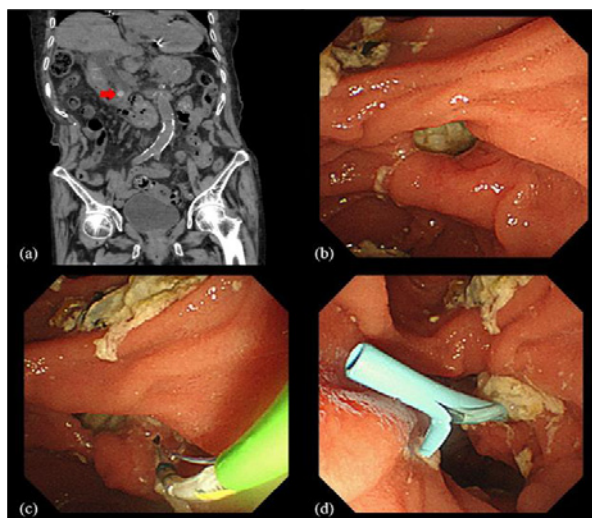


Figure 1: EST was performed and plastic stent was placed for choledocholithiasis.

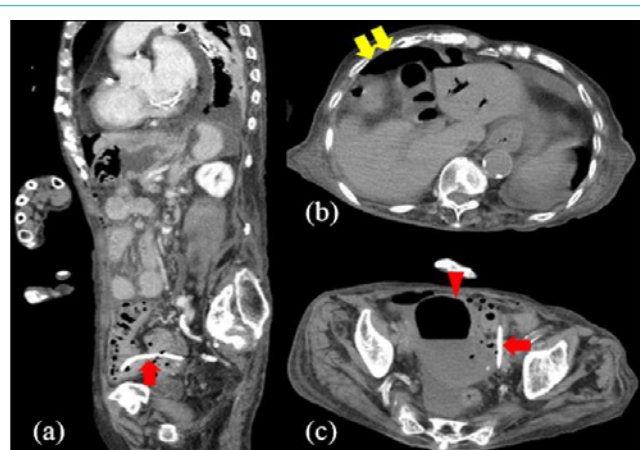


Figure 2: Perforation of the sigmoid colon due to deviated stent.

1). Most deviated biliary plastic stents are excreted in stool or collected endoscopically, but, very rarely, complications causing gastrointestinal perforation have been reported. We have described deviated biliary plastic stents causing sigmoid colon diverticulum perforation and even uterine appendage penetration (Figure 2). Diagnosis can be made from clinical symptoms and abdominal computed tomography. Treatment is basically surgery. Biliary stent-related complications are inevitable, and sometimes become serious. On suspicion of such complications, the most important issue is to accurately and rapidly diagnose complications and conduct appropriate management.

Authors' Contributions

All authors were involved in preparation and writing of the manuscript, and approved the final version of the manuscript for submission.

References

1. Saranga Bharathi R, Rao P, Ghosh K. Iatrogenic duodenal perforations caused by endoscopic biliary stenting and stent migration: an update. *Endoscopy*. 2006; 38: 1271-1274.
2. Johanson JF, Schmalz MJ, Geenen JE. Incidence and risk factors for biliary and pancreatic stent migration. *Gastrointest Endosc*. 1992; 38: 341-346.