

Review Article

A Review of the Management of the Common Acute Biliary Presentations

Abdalla S* and Sinha P¹Specialist Registrar in General Surgery, Princess Royal University Hospital, UK²Consultant Oncoplastic Breast, Princess Royal University Hospital, UK***Corresponding author:** Abdalla S, Specialist Registrar in General Surgery, Princess Royal University Hospital, King's College NHS Foundation Trust, Orpington, England**Received:** February 16, 2018; **Accepted:** April 04, 2018; **Published:** April 25, 2018**Abstract**

Conditions of the biliary tree are frequently encountered on surgical wards and in surgical outpatients. The spectrum of biliary diseases is broad and ranges from mild biliary colic that can be treated on outpatient basis, to cholangitis and severe pancreatitis which can be life-threatening. The majority of conditions are related to gallstones, although most individuals with gallstones are asymptomatic. This review aims to summarize the presentation and management of the most common emergent biliary conditions that the surgical junior doctor will encounter and it draws evidence from the most up-to-date guidelines.

Keywords: Gallstones; Emergencies; Surgical; Doctor; Guidelines**Introduction**

Gallstones are composed of cholesterol, bile pigment or a mixture of the two. Seventy-five percent of gallstones are a mixture of both cholesterol and pigment. Pure pigment stones are rare, accounting for 5% of all types, and are found in individuals with hemolytic disorders such as hereditary spherocytosis and Sickle-cell disease. Pure cholesterol stones account for the remaining 20% and may result from bile which is supersaturated in cholesterol [1,2]. Up to 90% of gallstones are radiolucent, which means that they are more detectable on ultrasound scanning (USS) (Figure 1) than computed tomography (CT). Ultrasound is therefore the screening modality of choice for detecting gallstones.

The main risk factors for development of gallstones are increasing age, female sex, obesity, hemolytic disorders and hyperlipidemia. Other risk factors include family history, pregnancy, rapid weight-loss and use of the combined contraceptive pill. Patients with Crohn's disease who have had terminal ileum resections are also at risk of developing gallstones due to interruption of the enterohepatic circulation of bile salts.

The primary investigations in acute biliary presentations are blood tests, which include full liver function tests, USS, CT and magnetic resonance cholangiopancreatography (MRCP). An additional test is an ERCP (endoscopic retrograde cholangiopancreatography) which involves the passage of a specialized endoscope into the second part of the duodenum where the Ampulla of Vater is cannulated (Figure 2). Contrast media is then injected through it and X-rays are taken in order to highlight the anatomy of the biliary tree (Figure 3). ERCP offers the additional benefit of being therapeutic since it enables sphincterotomy to be carried out and this man oeuvre facilitates ductal stone extraction and biliary stent insertion (Figure 1). Below is a discussion of the common acute biliary presentations and their management.

Biliary colic

This may be the first presentation of gallstones. It occurs when the gallbladder contracts against an obstruction, usually a gallstone in

Hartmann's pouch or in the cystic duct. The gallbladder contraction is stimulated by the hormone cholecystokinin, produced by the duodenum in response to the ingestion of fat [2].

The pain is colicky in nature and is felt in the epigastrium and right subcostal regions radiating to the back or right shoulder tip. It may become continuous and may be accompanied by nausea and vomiting. There may be a history of previous similar bouts of pain. However, the patient is generally systemically well with no features of sepsis. Blood tests which include inflammatory markers, liver function tests and amylase are frequently normal.

The confirmation of gallstones is made with an USS, although radio-opaque gallstones may also be detected on CT (Figure 2). The treatment of biliary colic is with adequate analgesia and antiemetics. Definitively the patient requires cholecystectomy, which is nowadays routinely performed laparoscopically. Earlier surgery is warranted in order to prevent recurrent attacks.

Acute cholecystitis

If a gallstone is not dislodged and remains impacted, the gallbladder becomes inflamed from the irritation induced by the static bile leading to a chemical cholecystitis. Bacterial colonization of the static bile will lead to suppurative infection and an empyema of the gallbladder.

In mild cases the patient is normally systemically well. Examination of the abdomen will reveal tenderness to deep palpation in the right upper quadrant of the abdomen around the tip of the 9th costal cartilage. This is more pronounced when the patient takes in a deep breath and is known as 'Murphy's' sign, the result of an inflamed gallbladder causing peritoneal irritation.

Blood results commonly reveal raised inflammatory markers. Liver function tests are not commonly deranged in acute cholecystitis, unless the inflamed gallbladder or the impacted stone in Hartmann's pouch compresses the common hepatic or the common bile duct, a condition known as 'Mirizzi' syndrome. Ultrasound scanning is the imaging modality of choice and it will confirm the presence of gallstones along with evidence of cholecystitis as demonstrated

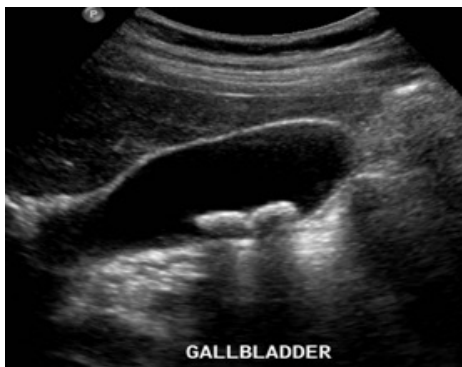

Figure 1: Abdominal USS demonstrating gallstones in the gallbladder. Gallstones are differentiated from gallbladder polyps in that they cast an acoustic shadow and move when the patient alters position.

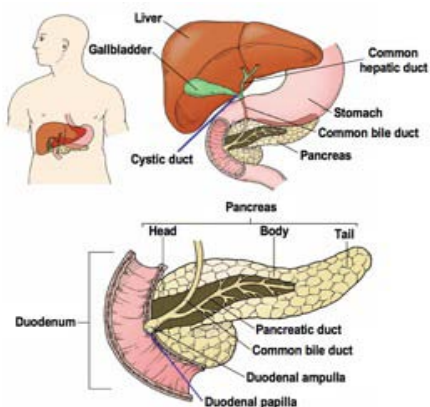


Figure 2: Anatomy of the gallbladder, pancreas and biliary tree.

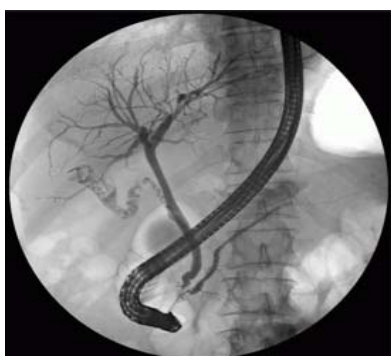

Figure 3: ERCP: the image demonstrates the endoscope cannulating the second part of the duodenum and contrast material highlighting the gallbladder, which contains gallstones, and the biliary tree.

by a thickened gallbladder wall with pericholecystitis fluid. Computed tomography scanning will also demonstrate these signs of cholecystitis, including surrounding fat stranding consistent with inflammation (Figure 4).

The management of cholecystitis consists of good analgesia, oral or intra-venous antibiotics depending on the severity, and cholecystectomy during the index admission or at a later date. Early surgery offers definitive treatment but if it is undertaken after 48

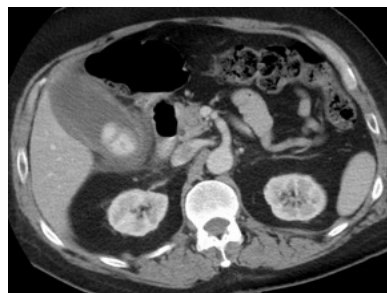

Figure 4: Acute cholecystitis on an axial slice of a CT scan demonstrating a thick gallbladder containing a calcified stone, pericholecystic fluid and fat stranding indicative of surrounding inflammation.

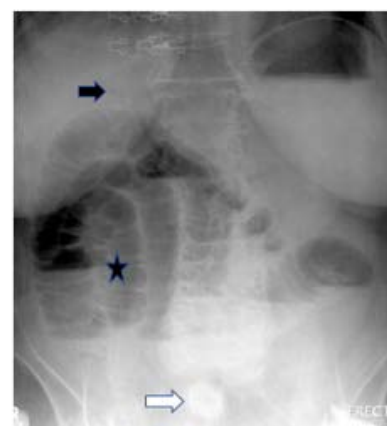

Figure 5: Rigler's triad: pneumobilia (black arrow), gallstone in the right lower quadrant (white arrow), dilated small bowel loops (star).

hours from the onset of symptoms it may be technically difficult due to the presence of inflammatory obscuring the normal anatomy [3].

Traditionally surgery used to be deferred for 8-12 weeks until the inflammation from the acute episode settles. However, patients can get recurrent symptoms and admissions during the waiting period. Recent studies comparing early versus late laparoscopic cholecystectomy have confirmed that early laparoscopic surgery is safe and feasible [4-8].

In patients with cholecystitis not resolving with conservative treatment who have medical comorbidities, or not fit for surgery, USS-guided percutaneous cholecystostomy is the recommended course of treatment [3]. After draining the gallbladder, the drainage tube should be left in situ until a mature fistula tract is formed which can take up to 6 weeks. Contrast is injected through the drainage tube to confirm that the biliary tree distal to the tube is patent before the tube is removed. If medical comorbidities can be optimized, the patient can then proceed to cholecystectomy. If surgery is contraindicated then the cholecystostomy tube can be left in situ for a longer duration to drain the gallbladder.

Gangrene and perforation of the gallbladder

A gangrenous gallbladder develops in cases of acute cholecystitis where the gallbladder distends and the rise in intraluminal pressure compromises the blood supply to the gallbladder wall, leading to necrosis of the gallbladder wall. It can occur in 2-20% of cases of acute

cholecystitis, and risk factors include advanced age, cardiovascular disease and diabetes mellitus [9].

Clinically, the patient may exhibit signs of localised peritonism. It is diagnosed on contrast-enhanced CT scanning which will typically demonstrate lack of gallbladder wall enhancement with irregularity, gallbladder wall thickening and pericholecystic fluid. These cases will require emergency surgery. If left untreated, gangrene of the gallbladder can progress to gallbladder perforation. Perforation of an acutely inflamed gallbladder is associated with high mortality rates and requires emergency surgery.

Cholecyst-duodenal fistula and gallstone ileus

A cholecyst-duodenal fistula is a fistula between the gallbladder and the duodenum which results from recurrent cholecystitis. In an inflamed gallbladder, an impacted gallstone may put pressure on adjacent structures which is typically the duodenum. Through pressure necrosis the stone will then erode through the gallbladder wall and pass into the duodenum. Small gallstones that are less than 2cm will pass spontaneously through the gastrointestinal tract. However, larger stones will become impacted in the terminal ileum or ileocaecal region, causing a small bowel obstruction or gallstone ileus [10]. The term ileus is a misnomer since gallstone ileus is a mechanical obstruction. Gallstones account for less than 1 % of cases of small bowel obstruction and occurs in 0.3 - 0.5% of patients with gallstones [10-12]. The largest gallstone to be removed from the gastrointestinal tract was 17.5 cm and it was removed from the transverse colon! [13].

A typical patient with this presentation is elderly and may have had recurrent attacks of cholecystitis. The acute presentation will be with features of small bowel obstruction. A plain abdominal radiograph will reveal dilated loops of small bowel and pneumobilia or air bubbles in the biliary tree. A calcified, radio-opaque gallstone might be visible in the region of the right iliac fossa.

The triad of small bowel dilatation, pneumobilia and a calcified stone outside of the biliary tree is known as 'Rigler's' triad (figure 5) [14].

Contrast-enhanced CT scanning is the most sensitive imaging modality for diagnosing gallstone ileus, and has the added advantage of demonstrating any related complication. Resuscitative management of the small bowel obstruction and surgery are the mainstay treatment options. The main aim of surgery is to remove the obstructing gallstone. The surgical options are removal of the gallstone alone (enter lithotomy), removal of the gallstone with cholecystectomy and closure of the fistula as a one-stage procedure, or a two-stage procedure with enter lithotomy in the first operation followed by delayed cholecystectomy [15].

Cholecystectomy and repair of the fistula prevents the risk of recurrent gallstone ileus and infective episodes such as cholecystitis and cholangitis. However, undertaking a prolonged procedure in an elderly patient with multiple co-morbidities may carry a higher rate of morbidity and mortality and therefore the choice of surgery depends on the general condition of the patient. The general Consensus is that enter lithotomy is the primary surgical management, and that concomitant cholecystectomy and fistula repair should only be carried out in highly selected cases [15].

Acute acalculous cholecystitis

This is inflammation of the gallbladder in the absence of gallstones. It is postulated to be due to microvascular ischaemia resulting in gallbladder inflammation. It is uncommon and typically seen in critically ill patients and diabetics. It is difficult to diagnose, although US and CT scanning will reveal features of gallbladder inflammation such as thickened gallbladder wall and pericholecystic fluid. Treatment consists of antibiotics and cholecystostomy or cholecystectomy depending on the fitness of the patient.

Acute cholangitis

This is a life-threatening infection of the biliary tree arising from infection of an obstructed biliary system. It is a common sequela of gallstones impacted in the distal common bile duct, although strictures, masses and external compression can also obstruct the distal common bile duct. Biliary stasis followed by superadded infection from bacteria such as Gram negative bacilli (*Escherichia coli*, *Klebsiella*, and *Pseudomonas*) gives rise to the features of this condition.

The classic features of this condition are abdominal pain, jaundice and fever or rigors (Charcot's triad) but it must be remembered that these are present in fewer than 25% of patients [1-3]. Reynold's pentad, which is even more uncommon, includes shock and altered mental status. The presentation may be atypical and more subtle in the elderly.

Blood results typically reveal obstructive liver function tests and raised inflammatory markers. The serum amylase may also be raised. The clotting profile is often deranged as a result of Vitamin K deficiency from prolonged obstruction of the biliary tree.

USS is the first line imaging investigation and this will demonstrate a dilated biliary tree and will provide information about the caliber of the common bile duct. CT can also identify biliary dilatation as well as the level and cause of obstruction [16].

The management of acute cholangitis is with good resuscitation, intra-venous antibiotics and urgent drainage of the obstructed biliary system through ERCP or percutaneous transhepatic cholangiography (PTC). Management of these patients in the high dependency unit may be necessary as patients can deteriorate rapidly. After resolution of the acute episode, in cases that are due to gallstones, cholecystectomy should be carried out.

Obstructive jaundice

Obstructive jaundice arises from obstruction of the distal common bile duct by a variety of causes, classified typically as intra-luminal, extra-luminal and mural. When it is due to an obstructing gallstone, there may be a history of abdominal pain or attacks of biliary colic associated with pallor of stools and darkening of the urine. The obstruction may be relieved if a small gallstone passes.

CT is the primary imaging modality whenever malignancy is suspected as the cause of biliary obstruction. Ultrasound confirms the presence of gallstones but is less effective than CT in determining the site of obstruction. MRCP is the most sensitive non-invasive imaging tool to detect ductal stones or choledocholithiasis.

Obstructing distal common bile duct (CBD) stones are

removed using a Balloon or Dormia basket at ERCP. Subsequent cholecystectomy is required. Other options of management depending on the aetiology may include CBD stenting or PTC.

Acute pancreatitis

This is an inflammation of the pancreas which may involve the whole pancreas or a focal portion.

Gallstones and excess alcohol consumption account for approximately 80% of causes [1-3]. The acronym GETSMASHED serves as a good reminder for the recognized causes of pancreatitis (Gallstones, Ethanol, trauma, steroids, Mumps, autoimmune, Scorpion bite, hyperlipidemia/hypercalcemia/hypothermia, ERCP-related, Drugs (commonly Azathioprine, Thiazide diuretics and anti-psychotics). According to recent UK guidelines, no more than 20% of patients with pancreatitis should be labelled as having idiopathic pancreatitis [17].

It is unclear as to how each of these aetiological agents directly results in pancreatic cellular injury and inflammation. However, once inflammation occurs, it triggers off a systemic inflammatory response which may progress to end organ dysfunction.

Patients typically present with central or epigastric abdominal pain radiating through to the back with or without nausea and vomiting. There may be a history of known gallstones, recurrent attacks of abdominal pain or alcohol excess. A detailed drug history is important.

Examination will typically reveal tenderness localised to the centre of the abdomen or epigastrium. Grey-Turner (flank bruising) and Cullen signs (periumbilical bruising) occur in severe acute pancreatitis secondary to retroperitoneal or intra-abdominal hemorrhage from the acute inflammation.

A diagnostic biochemical finding is a serum amylase which is more than three times the upper limit of normal. However, an elevated serum amylase is not specific to acute pancreatitis and may occur in perforated peptic ulcer, mesenteric ischaemia, acute cholecystitis, ruptured abdominal aortic aneurysm and diabetic ketoacidosis. The serum amylase may be normal in instances where the history is prolonged or if there is a history of chronic pancreatitis. It is important to remember that there is no correlation between serum amylase levels and disease severity. A more sensitive and specific marker for acute pancreatitis is serum lipase which is produced exclusively by the pancreas. However, it is an expensive test and therefore not widely available in UK hospitals. Additionally, like amylase, it does not correlate with disease severity.

The first line imaging modality in acute pancreatitis is USS to look for gallstones. In equivocal cases where the diagnosis is unclear, CT scanning is recommended to confirm the diagnosis and exclude other conditions.

The management of acute pancreatitis consists of confirmation of diagnosis alongside resuscitative measures, and severity stratification in order to determine the degree of supportive and monitoring care required. A number of scoring systems are available for determining the prognosis of the disease. Glasgow score is most widely used and was designed for use in a British population with gallstones-predominant disease. Ransom is used to grade the severity of alcohol

induced pancreatitis. Raised CRP over 150 is another prognostic indicator. It is recommended that patients with prognostically severe disease are managed in high dependency units and should have a contrast-enhanced CT between the 3rd and 10th day of admission to exclude pancreatic necrosis [3].

The treatment entails optimization of oxygenation, intravenous fluids, adequate analgesia, and correction of metabolic abnormalities such as hyperlipidemia and hypercalcemia and thrombo prophylaxis. Proton pump inhibitors are recommended against UGI hemorrhage in patients with severe disease [3].

Early ERCP is advocated in patients with gallstone pancreatitis to remove the obstructing gallstone. The role of antibiotics and antifungals in acute pancreatitis is still not fully clear as there have been a number of conflicting studies. The consensus is that antibiotics should be given in patients with evidence of pancreatic necrosis and features of sepsis.

Patients with acute pancreatitis should no longer be kept nil by mouth (NBM). The NBM regime prevents nutrients from reaching the intestinal luminal cells. This can lead to intestinal luminal dysfunction which can progress to bacterial translocation and exacerbation of the systemic inflammatory response. Enteral nutrition is safe and feasible in acute pancreatitis [3].

Conclusion

The British Society of Gastroenterology recommends that patients with gallstones-induced mild pancreatitis should undergo laparoscopic cholecystectomy within the index admission or within two weeks. Patients with severe pancreatitis can have the cholecystectomy delayed until clinical resolution. Definitive treatment in the form of endoscopic sphincterotomy is reserved for those who are unfit for surgery.

References

1. McLatchie G, Borley N, Chikwe J. Oxford handbook of clinical surgery. Oxford University press. 2013: 300-302.
2. Henry M, Thompson J. Clinical Surgery second edition. Elsevier Saunders. 2001: 331-332.
3. Paterson-Brown. Core topics in General and emergency surgery. Fourth Edition. Elsevier Saunders. 2012: 125-146.
4. Lo CM, Liu CL, Fan ST, E C Lai, J Wong. Prospective randomized study of early versus delayed laparoscopic cholecystectomy for acute cholecystitis. *Ann Surg.* 1998; 227:461-467.
5. Lai PB, Kwong KH, Leung KL, Kwok SP, Chan AC, Chung SC et al. Randomized trial of early versus delayed laparoscopic cholecystectomy for acute cholecystitis. *Br J Surg.* 1998; 85: 764 -767.
6. Johansson m, Thune A, Blomqvist A, Nelvin L, Lundell L. Management of acute cholecystitis in the laparoscopic era: results of a prospective randomized clinical trial. *J Gastrointest Surg.* 2003; 7: 642-645.
7. Kolla SB, Aggarwal S, Kumar A, Kumar R, Chumber S, Parshad R. Early vs delayed laparoscopic cholecystectomy for acute cholecystitis. *Surg Endosc.* 2004; 18: 1323-1327.
8. Kiviluoto T, Siren J, Luukkonen P, Kivilaakso E. Randomized trial of laparoscopic versus open cholecystectomy for acute gangrenous cholecystitis. *Lancet.* 1998; 351: 321-325.
9. Fagan SP, Awad SS, Rahwan K, Hira K, Aoiki N, Itani KMF, et al. Prognostic factors for the development of gangrenous cholecystitis. *Am J Surg.* 2003; 186: 481-485.

10. Delabrousse E, Bartholomot B, Sohm O, Wallerand H, Kastler B. Gallstone ileus: CT findings. *Eur Radiol.* 2000; 10: 938-940.
11. Windham TC, Rascoe PA, Madrid A. Image of the month-diagnosis. Gallstone ileus. *Arch Surg.* 2003; 138: 807-808.
12. Clavien PA, Richon J, Burgan S, Rohner A. Gallstone ileus. *Br J Surg.* 1990; 77: 737-742.
13. VanLandingham SB, Broders CW. Gallstone ileus. *Surg Clin North Am.* 1982; 62: 241-247.
14. Swift SE, Spencer JA. Gallstone ileus: CT findings. *Clin Radiol.* 1998; 53: 451-454.
15. Carlos M Nuño-Guzmán, María Eugenia Marín-Contreras, Mauricio Figueroa-Sánchez, Jorge L Corona. Gallstone ileus, clinical presentation, diagnostic and treatment approach. *World J Gastrointest Surg.* 2016; 8: 65-76.
16. Balthazar EJ, Birnbaum BA, Naidich M. Acute cholangitis: CT evaluation. *J Comput Assist Tomogr.* 1993; 17: 283-289.
17. UK working party on acute pancreatitis. Uk guidelines for the management of acute pancreatitis. *Gut.* 2005; 54: iii 1-9.