

Research Article

The Role of Oral Endoscope during Laparoscopic Intra-gastric Surgery of Gastric Submucosal Tumor

Tagaya N*, Hakozaiki Y, Yamaguchi N, Shimada M, Oya M, Matsunaga Y, Tatsuoka T, Kubota Y, Hirano K, Suzuki A, Saito K, Yamagata Y, Koketsu S, Okuyama T, Sugamata Y, Sameshima S and Oya M

Department of Surgery, Dokkyo Medical University Koshigaya Hospital, Japan

*Corresponding author: Nobumi Tagaya, Department of Surgery, Dokkyo Medical University Koshigaya Hospital, Japan

Received: July 14, 2015; Accepted: September 09, 2015; Published: September 11, 2015

Abstract

Introduction: Recently the surgical resection of Gastric Submucosal Tumor (GST) has been adapted to laparoscopic approaches. The use of an oral endoscope is required to accomplish a feasible and safe intra-gastric approach. Here we report the role of oral endoscope during laparoscopic intra-gastric surgery of GSTs.

Patients and Methods: We performed laparoscopic intra-gastric resection of GSTs in 20 patients. We selected two approaches; 1) Two or three ports were directly inserted into the stomach, or 2) The stomach was directly opened through a 2.5-cm single skin incision at umbilicus. Both approaches were completed under the guidance of oral endoscope.

Results: Laparoscopic intra-gastric resection was successful in all patients. The mean maximum tumor diameter, operation time and blood loss were 27.1 mm 155 min and 14ml, respectively. One patient required a gastrostomy to remove the tumor. There was one postoperative bleeding. The mean postoperative hospital stay was 7.7 days. There were no recurrences during a mean follow-up period of 97.4 months. The use of an oral endoscope lead a determination of the port placement in the stomach, a visual supplement of laparoscopic intra-gastric resection, a retrieval of the specimen via the mouth, and a final check of the presence of air leakage or bleeding from after re-inflation of the stomach.

Conclusion: Intra-gastric surgery using oral endoscopy can be considerably beneficial for patients with GSTs located in the upper and middle part of the stomach. The significance of oral endoscopy during laparoscopic procedures was emphasized from the viewpoint of minimal surgical invasiveness.

Keywords: Laparoscopic treatment; Intra-gastric resection; Gastric submucosal tumor; Oral endoscope; Stomach

Introduction

Recently the surgical resection of Gastric Submucosal Tumor (GST) has been adapted to a laparoscopic approach as a result of similar surgical outcomes of open procedure [1]. The selection of several laparoscopic approaches greatly depends on the characteristics of the tumor, including its size or location, and also the experience and skill of the surgeon. We have previously described our technique and results of intra-gastric resection of GSTs [2-7], and recently we introduced single incision intra-gastric surgery for GSTs. To accomplish a feasible and safe intra-gastric approach requires the use of an oral endoscope. Here we report the role of oral endoscope during laparoscopic intra-gastric surgery of GSTs.

Patients and Methods

During the past 18 years, we have performed laparoscopic intra-gastric resection of GST for 26 tumors in 20 patients (8 men and 12 women) with a mean age of 61.5 years (range, 34-75 years). The tumor of the stomach was located on the anterior wall of the upper third in 2 patients, the posterior wall of the upper third in 8, the lesser curvature of the upper third in 5, the greater curvature of the upper third in 1, the anterior wall of the middle third in 1, and the posterior

wall of the middle third in 1 and the lesser curvature of the middle third in 2, respectively (Table 1). All patients were preoperatively investigated by means of an upper gastrointestinal radiological series and endoscopy with ultrasound to assess the distance between the Esophago Gastric Junction (EGJ) and the proximal side of the tumor and evaluate the size and location of the tumor within the stomach wall layers. Computed tomography with contrast medium was added to clarify whether there were any abdominal findings influencing

Table 1: Patient characteristics (n=20).

Age (yrs): mean (range)	61.5 (3475)
Gender (M:F)	8:12
Tumor Location	
Fornix anterior	2
Posterior	2
Lesser curvature	3
Body anterior	1
Posterior	7
Lesser curvature	4
Greater curvature	1

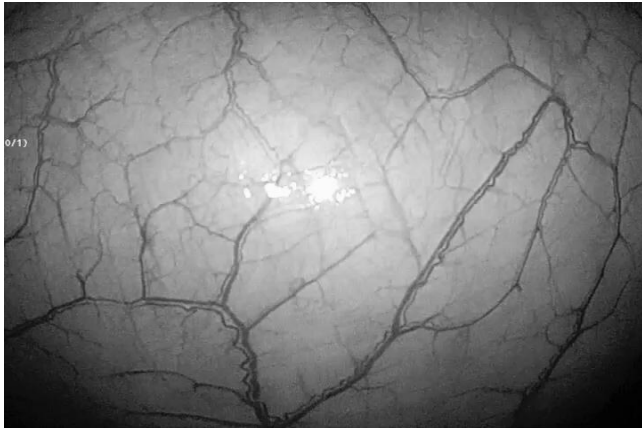


Figure 1: The stomach was brought out through a skin incision of the umbilicus after the infiltration of stomach.

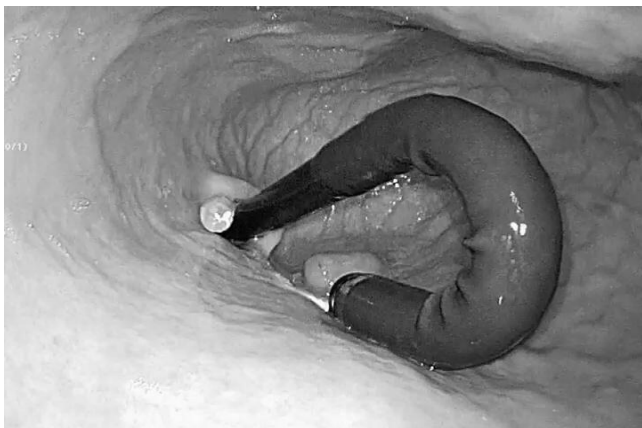

Figure 2: The tumor was identified and resected with an adequate margin in all directions using linear staplers under the guidance of oral endoscope.

to the treatment strategy. The indication criteria for this procedure were a tumor locating in the upper and middle stomach or near the esophagogastric junction with an endophytic growth, and a tumor less than 5 cm in diameter and 8 cm² in cross-section for the specimen removal from the mouth.

We selected two approaches consisting of standard technique and single site one depending on the condition of the individual stomach. The latter approach was applied to the patient whose stomach was easily transferred to the umbilical site.

Standard technique [4, 6]

The patient was placed in the supine position under general anesthesia, and a 12-mm port was initially introduced into the umbilicus. A pneumoperitoneum was established by Carbon Dioxide (CO₂) insufflation, and the intra-abdominal pressure was maintained at 10 mmHg. The stomach was inflated by airflow through an oral endoscope. Initially, the abdominal wall and the anterior wall of the stomach were fixed using a double-straight needle device (Ideal Lifting; Olympus Medical Systems Co., Tokyo, Japan) to follow the port insertion easily. After this preparation, two or three ports (one 12-mm and one or two 5-mm ports) were directly inserted into the stomach from the left upper quadrant of the abdominal wall,

depending on the tumor location, under oral endoscopic guidance. Partial resection of the stomach including the tumor and an adequate margin in all directions was performed using a linear stapler so as not to cause any deformity or stenosis of the stomach and EGJ. The linear stapler was first fired on the normal gastric wall near the distal side of the tumor. The direction of the cut line was modified so that it remained clear of the EGJ. The resected specimen was retrieved orally using a plastic bag. If the tumor could not be removed orally depending on its size, a gastrostomy was created by enlarging one of the port sites. The resected specimen was investigated immediately to ensure pathologically free margins. The two or three portholes in the stomach were closed using extracorporeal suture or intracorporeally using an Endo-GIA or hand sewing. After repair of the portholes, the stomach was re-inflated to confirm hemostasis and exclude stenosis at the EGJ. The laparoscope was used to check for leakage from the closed sites. All skin incisions were closed without drainage.

In a modified technique, after establishing a pneumoperitoneum and inflating the stomach by an oral endoscope, the stomach was brought out through the umbilical incision and a 12-mm gastric opening was made. This hole was used for insertion of an Endo-GIA linear stapler or a 10-mm laparoscope. Subsequently a 3-mm port was directly inserted into the stomach at the left upper quadrant without any fixation. After manipulating the normal gastric mucosa near the tumor by 3-mm instruments, the tumor was resected using a linear stapler under oral endoscopic guidance. The specimen was retrieved through the mouth. The entry hole in the stomach was directly closed extracorporeally, and a 3-mm hole was closed by clipping from the mucosal side using an oral endoscope. The skin was only closed at the umbilicus.

Single-site technique [6,7]

Under general anesthesia the patient was placed in the supine position. Initially a 2.5-cm umbilical incision was made, and an extra small wound retractor (Applied Medical, Rancho Santa Margarita, CA, and USA) was applied to that incision. The stomach was brought out through a skin incision of the umbilicus after the infiltration of stomach (Figure 1), and a 2-cm opening was made in the anterior wall of the stomach. A single port device or surgical glove with 2 or 3 working ports (one 12-mm and one or two 5-mm ports) was applied to the gastric opening. The stomach was inflated with CO₂, and intragastric pressure was maintained between 8 and 10 mmHg. The tumor was identified (Figure 2) and resected with an adequate margin in all directions using linear staplers under the guidance of oral endoscope. The specimen was retrieved from the single port site. After the single port device or surgical glove had been removed, the gastric opening was closed using absorbable sutures from the skin incision. The stomach was re-inflated to check for hemostasis on the stapled line and leakage from the closed site. The umbilical wound was closed without drainage.

Results

Laparoscopic Intra-gastric Resection of the GST with the assistance of oral endoscope was successful in all cases. One of them was changed from single-site technique to standard one due to the difficulty of displacement of the stomach under the umbilicus. There were standard technique in 17 patients and single site technique in 3. The surgical results are shown in Table 2. The mean maximum

Table 2: Surgical Results (n=20).

	Standard (n=17)	Single site (n=3)	Total (n=20)
Tumor size (mm)*	25.9 (9-65)	29 (15-40)	27.1 (9-65)
Operation time (ml)*	168.3 (89-248)	79.7 (61-113)	155 (61-248)
Blood loss(ml)*	15.5 (3-170)	7 (3-15)	14 (3-170)
Pathology			
GIST (low/intermediate/high)	13/1/1	0/3/0	13/4/1
Leiomyoma	4	0	4
NET	1	0	1
Enterogeneous cyst	1	0	1
Postoperative complication	Bleeding:1	none	
POHS (day)*	7.8 (4-12)	7.7 (6-11)	7.7 (4-12)
Follow-up (month)*	114.2 (1-218)	3 (0-6)	97.4 (0-218)

*mean (range), POHS: Postoperative hospital stay.

diameter of the tumor, operation time and intraoperative blood loss in total, standard and single site techniques were 27.1 mm (range, 9-65), 25.9 mm (range, 9-65) and 29 mm (range, 15-40), 155 min (range, 61-248), 168.3 min (range, 89-248) and 79.7 min (range, 61-113), and 14 ml (range, 3-170), 15.5 ml (range, 3-170) and 7 ml (range, 3-15), respectively. One patient in standard technique needed a gastrostomy and enlargement of one of the port sites in order to remove the tumor. There was one postoperative bleeding from a resected staple line in a standard technique; hemostasis was obtained by clipping of oral endoscope. Oral intake was re-commenced between the first and third postoperative day in all cases. The mean postoperative hospital stay in total, standard and single site techniques was 7.7 days (4-12), 7.8 days (range, 4-12) and 7.7 days (range 6-11). The diagnosis after pathological examination of the tumor was Gastro Intestinal Stromal Tumor (GIST) in 14 patients, leiomyoma in 4, and a cyst and neuroendocrine tumor in one, respectively. There was no evidence of EGJ stenosis at the 6-monthly follow-up examinations, although there was mild deformity of the stomach in cases where the resected tumor had been more than 5 cm in diameter. The mean follow-up period in total, standard and single site techniques was 97.4 months (range, 0-218), 114.2 months (range, 1-218) and 3 months (range, 0-6), and there were no recurrences during those periods in our series. The use of an oral endoscope lead a determination of the port placement site in the stomach, a visual supplement of laparoscopic intragastric resection, a retrieval of the specimen via the mouth, and a final check of the presence of any air leakage or bleeding from the resected area after re-inflation of the stomach.

Discussion

The selection of the surgical procedures for GSTs depends on the characteristics of the tumor, including its size, location and growth condition consisting of endophytic, intramural, or exophytic types; however, laparoscopic approaches are often adopted from the consideration of minimal surgical invasiveness. In particular, laparoscopic intragastric resection is suitable for tumors located near the EGJ or pyloric ring, in order to avoid gastrectomy or stomach deformity after resection. Recently the role of oral endoscopy during intragastric resection of GSTs has been emphasized to accomplish the safe and reliable removal of the tumor.

Initially our indication of intragastric procedure is 2-5 cm in diameter and located on the posterior side of the upper and middle stomach, or near the EGJ [2]. After several experiences, tumors larger than 5 cm in diameter or 8 cm₂ in cross-sectional area require an additional gastrostomy for removal of the tumor from the stomach because of the difficult passing of EGJ using an oral endoscope [3-5]. Therefore, we introduced an intragastric resection via single-site of umbilical incision to facilitate the removal of resected specimen that could not pass the EGJ [7].

Single-site laparoscopic surgery via the umbilicus was introduced in 2007 and attracted to laparoscopic surgeons. We have also started single-site laparoscopic local resection of the stomach for GSTs showing an exophytic growth of the stomach from May 2011. There are several reports [8-11] describing single-site access for the GSTs showing an endophytic growth of the stomach. Na et al. [8] reported that a single-incision intragastric approach did not require the use of intraoperative oral endoscopy or pneumoperitoneum. In comparison with conventional intragastric approach, the operation time was reduced because of the use of a single gastrostomy and an extracorporeal repair, the specimen was easily retrieved from the gastric opening, and a better cosmesis at the umbilicus was achieved. However, this procedure requires multiple linear staplers to resect the tumor; the indication is limited in the cases that the stomach is possible to pull down to the navel level. In fact, we experienced a case that the stomach could not pull down to the navel level. Choi et al. [11] also reported that meticulous intragastric resections without intraoperative endoscope under the good laparoscopic view were performed. This approach has the limitations due to the size and location of the tumor; however, it is one of good treatment option for GST. From above findings, the single-site approach at the umbilicus avoids multiple punctures of the stomach regarding a cosmetic result, and allows retrieval of larger specimens comparing with a transoral route using an oral endoscope.

For a steady intragastric resection of GSTs, the use of an

Table 3: Basic data of literature.

Author	(Year)	Case	Gender (M:F)	Age (Mean)	Location (u/M/L)	Size (mm)
Choi & Oh	2000	9	NA	NA	9/0/0	NA
Matthews et al	2002	3	NA	NA	3/0/0	NA
Walsh et al	2003	11	NA	NA	11/0/0	24-85
Pross et al	2003	5	NA	NA	5/0/0	34 (28-41)
Uchikoshi et al	2004	7	NA	NA	7/0/0	27-75
Li et al	2008	3	0:3	77	2/1/0	28 (20-40)
Na et al	2011	7	3:4	65	6/1/0	27 (23-38)
Sahm et al	2011	7	NA	NA	NA	38 (28-48)
Shim et al	2011	6	3:3	48	7/0/0	27 (15-40)
DE Vogelaere et al	2013	3	NA	68	3/0/0	38 (27-68)
Dong et al	2014	8	3:5	51	6/2/0	28 (15-45)
Lamm et al	2014			3		NA
NA	1/0/2			24	(21-26)	
Choi et al	(2014)	21	9:12	52	15/3/2	24 (10-44)
Tagaya et al	(2015)	20	8:12	62	14/6/0	27 (9-65)

Table 4: Clinical data of the literature.

Author	Year	Operation Time(min)	Complication (Day)	POHS	Recurrence	Follow-up (month)
Choi & Oh	2000	100-140	Open conversion:1	5:9	None	Up to 42
Matthews et al	2002	NA	NA	NA	NA	NA
Walsh et al	2003	186 (120-320)	None	3-8	None	16.2 (1-32)
Pross et al	2003	85-105	None	4.7	None	NA
Uchikoshi et al	2004	141 (95-200)	Open conversion: 1	7.6	1 case	14-99
Li et al	2008	192 (140-240)	Staple line bleeding: 1	7.7	None	8-57
Na et al	2011	86 (70-105)	Wound bleeding: 1	5.7	None	8.5 (1-23.3)
Sahm et al	2011	NA	None	6.1	NA	NA
Shim et al	2011	128 (105-145)	None	4.3	NA	NA
DE Vogelaere et al	2013	75 (67-82)	None	5.0	None	NA
Dong et al	2014	85 (60-130)	None	7.4	None	NA
Lamm et al	2014	NA	None	NA	None	NA
Choi et al	(2014)	68.6	Staple line bleeding:2	4.9	None	19
Tagaya et al	(2015)	156 (61-248)	Staple line bleeding: 1	7:8	None	94.7 (1-218)

POHS: Postoperative Hospital Stay.

oral endoscope is mandatory. Schubert et al. [12] reported that intraoperative oral flexible endoscopy has several advantages including trans-illumination, which facilitates visualization of the gastric lesion in laparoscopic view, elimination of preoperative tattooing of the lesion, and evaluation of the stapled or sutured gastric closure for any leakage after resection. We also recognized that oral endoscope during procedure facilitated a precise definition of the tumor location, a determination of the port placement site in the stomach, a assistance of intragastric resection, a confirmation of hemostasis at the staple line, a retrieval of the specimen via the mouth, and a checking of the presence of any air leakage from the resected area after re-inflation of the stomach [6,7]. Recently, Hiki et al. [13] introduced Laparoscopic and Endoscopic Cooperative Surgery (LECS) for resection of GISTs, and it requires the similar technique of endoscopic submucosal dissection. This method provides with obtaining an adequate cutting line independently of tumor location, eliminating any excessive resection of the normal gastric wall, and minimizing any deformity of the stomach after resection. However, its indications are limited to the inside growth tumors less than 5 cm in size, with no direct tumor exposure and ulceration in an avoidance of the risk of dissemination. Recently, Lamm et al. [14] reported a transoral specimen removal using a transoral gastric tube that eliminated the need for gastroscope. However, its indication is limited for smaller tumors. In any case, we suppose that oral endoscopy during laparoscopic procedures will make an important role to achieve minimal surgical invasiveness and adequate radical effects.

In laparoscopic intragastric resections for GSTs, there are 19 reports [7-12, 14-26] published between 2000 and 2015. Five of them were excluded due to a single case and unclear contents to analyze, 14 reports [7-26]re reviewed regarding tumor characteristics and operative outcomes (Table 3 and 4). The mean number of cases and age are 8 cases (range, 3-21) and 60 years (range, 48-77), respectively. The location of tumor was distributed in the upper stomach in 96 cases (85.0%), the middle in 13 (11.5%) and the lower in 4 (3.5%). The mean size of the tumor was 29.5 mm (range, 24-38). In general,

the indication of intragastric resection for GST was a tumor location in the upper third of the stomach, endophytic growth and less than 5 cm in diameter. The mean operation time was 124.2 min (range, 68.6-192). There were 7 complications (6.2%), including conversion to open laparotomy in 2 cases, and bleeding from the staple line in 4 and wound in one, respectively. We have carefully to check the bleeding from a stapled line after resection of the tumor, and recommend the re-infiltration of stomach using an oral endoscope at the last time of procedure to minimize the postoperative bleeding from the stapled line. The mean postoperative hospital stay was 6.2 days (range, 4.3-7.8). The follow-up period ranged from 1 to 192 months, and only one case of tumor recurrence was recorded. The recurrence of tumor greatly depends on the size of the tumor. A half of reviewed literature was not showed the observation period after resection of the tumor. Nakamori et al. [21] reported that the recurrence rate increased with tumor size, and that the average period until recurrence was 23.6 months. A follow-up period of more than 2 years is necessary to evaluate the recurrence of GSTs.

In conclusion, intragastric surgery using laparoscopy and oral endoscopy can be considerably beneficial for patients with GSTs located in the upper and middle part of the stomach. The significance of oral endoscopy during laparoscopic procedures was emphasized from the viewpoint of minimal surgical invasiveness.

Reference

1. Tagaya N, Mikami H, Igarashi A, Ishikawa K, Kogure H, Ohyama O, et al. Laparoscopic local resection for benign non-epithelial gastric tumors. *J Laparoendosc Adv Surg Tech A* 1997; 7: 53-58.
2. Tagaya N, Kita J, Kogure H, Kubota K. Laparoscopic intragastric resection of gastric leiomyoma using needlescopic instruments. *Case report. Surg Endosc* 2001; 15: 414.
3. Tagaya N, Mikami H, Kogure H, Kubota K, Hosoya Y, Nagai H, et al. Laparoscopic intragastric stapled resection of gastric submucosal tumors located near the esophagogastric junction. *Surg Endosc* 2002; 16: 177-179.
4. Tagaya N, Mikami H, Kubota K. Laparoscopic resection of gastrointestinal mesenchymal tumors located in the upper stomach. *Surg Endosc* 2004; 18: 1469-1474.

5. Tagaya N, Kubota K. Laparoscopic resection of gastrointestinal mesenchymal tumors in the upper stomach. Marilyn B. Tompkins, editor, In: Gastric Cancer Research Trends. Nova Science Publishers, Inc., 2007; 259-272.
6. Tagaya N, Kubota Y, Makino N, Takegami M, Saito K, Okuyama T, et al. Gastrointestinal Endoscopy: Laparoscopic intra-gastric resection of gastric sub-mucosal tumors under oral endoscopic guidance. *J Gastrointestinal Digestive System*. 2013; S2,
7. Na JU, Lee SI, Noh SM. The single incision laparoscopic intragastric wedge resection of gastric submucosal tumor. *J Gastric Cancer* 2011; 11: 225-229.
8. Morales-Conde S, Alarcon I, Ortiz-Moyano C, Barranco A, Padillo FJ, Socas M, et al. Intra-gastric endoscopic assisted single incision surgery for gastric leiomyoma of the esophagogastric junction. *Case Res Gastrointest Med*. 2013. doi:10.1155/2013/391430. PMID: 24416603.
9. De Vogelaere K, Van De Winkel N, Simonds C, Delvaux G. Intra-gastric SILS for GIST, a new challenges in oncologic surgery: First experience. *Anticancer Research*, 2013; 33: 3359-3363.
10. Choi CI, Lee SH, Hwang SH, Kim DH, Jeon TY, Kim DH, et al. Single-incision intragastric resection for upper and mid gastric submucosal tumors: a case-series study. *Ann Surg Treat Research* 2014; 87: 304-310.
11. Schubert D, Kuhn R, Nestler G, Kahl S, Ebert MP, Malfertheiner P, et al. Laparoscopic-endoscopic rendezvous resection of upper gastrointestinal tumors. *Dig Dis* 2005; 23: 106-112.
12. Hiki N, Yamamoto Y, Fukunaga T, Yamaguchi T, Nunobe S, Tokunaga M, et al. Laparoscopic and endoscopic cooperative surgery for gastrointestinal stromal tumor dissection. *Surg Endosc* 2008; 22: 1729-1735.
13. Lamm SH, Steinemann DC, Linke G, Eucker D, Simon T, Zerz A, et al. Total inverse transgastric resection with transoral specimen removal. *Surg Endosc* 25 December 2014 DOI 10.1007/s00464-014-4037-1.
14. Choi YB, Oh ST. laparoscopy in the management of gastric submucosal tumors. *Surg Endosc* 2000; 14: 741-745.
15. Matthews BD, Walsh RM, Kercher KW, Sing RF, Pratt BL, Answini GA, et al. Laparoscopic vs open resection of gastric stromal tumors. *Surg Endosc* 2002; 16: 803-807.
16. Walsh RM, Ponsky J, Brody F, Matthews BD, Haniford BT. Combined endoscopic/laparoscopic resection of gastric stromal tumours. *J Gastrointest Surg* 2003; 7: 386-392.
17. Pross M, Wolff S, Nestler G, Schubert D, Kahl S, Lippert H. A technique for endo-organ resection of gastric wall tumors using one intragastric trocar. *Endoscopy* 2003; 35: 613-615.
18. Ludwig K, Weiner R, Bernhardt J. Minimally invasive resections of gastric tumors. *Chirurg* 2003; 74: 632-637.
19. Uchikoshi F, Ito T, Nishida T, Kitagawa T, Endo S, Matsuda H. Laparoscopic intragastric resection of gastric stromal tumor located at the esophago-cardiac junction. *Surg Laparosc Endosc Percutan Tech* 2004; 14: 1-4.
20. Li VK, Hung WK, Chung CK, Ying MW, Lam BY, Kan DM, et al. Laparoscopic intragastric approach for stromal tumours located at the posterior gastric wall. *Asian J Surg* 2008; 31: 6-10.
21. Nakamori M, Iwashita M, Nakamura M, Tabuse K, Mori K, Taniguchi K, et al. Laparoscopic resection for gastrointestinal stromal tumor of the stomach. *Am J Surg* 2008; 196: 425-429.
22. Sahm M, Pross M, Lippert H. Intraluminal resection of gastric tumors using intragastric trocar technique. *Surg Laparosc Endosc Percutan Tech* 2011; 21: 169-172.
23. Shim JH, Lee HH, Yoo HM, Jeon HM, Park CH, Kim JG, et al. Intra-gastric approach for submucosal tumor located at the Z-line: A hybrid laparoscopic and endoscopic technique. *J Surg Oncol* 2011; 104: 312-315.
24. Vecchio R, Marchese S, Amore FF, La Corte F, Ferla F, Spataro L, et al. Laparoscopic –endoscopic rendez-vous resection of juxta-cardial gastric GIST. *G Chir* 2013; 34: 145-148.
25. Dong HY, Wang YL, Jia XY, Li J, Li GD, Li YQ, et al. Modified laparoscopic intragastric surgery and endoscopic full-thickness resection for gastric stromal tumor originating from the muscularis propria. *Surg Endosc* 2014; 28: 1447-1453.