

## Special Article - Stomach (Gastric) Cancer

# Palliative Extended Multi organ Resection with Total Gastrectomy in A Patient with Gastric Outlet Obstruction. Is There Any Sense?

De Tomás J\*, Cuadrado M, Monturiol JM and Turégano F

Department of General Surgery, University General Hospital Gregorio Marañón, Madrid, Spain

\*Corresponding author: De Tomás J, Department of General Surgery, University General Hospital Gregorio Marañón, Calle Fuencarral 22 2º interior C 28004 Madrid, Spain, Tel: 0034 619545785; Email: jdetomaspal@hotmail.com

Received: September 23, 2014; Accepted: September 25, 2014; Published: September 27, 2014

## Dear Editor:

Multiorgan resection associated with total gastrectomy has been accepted in cases of T4 gastric adenocarcinomas when a R0 resection could be completed [1-3]. These procedures are very complex and have high morbidity and mortality rates. Therefore, in cases of Gastric Outlet Obstruction (GOO) in gastric adenocarcinomas stage IV patients, endoscopic stents are perhaps a more appropriate therapeutic choice [4,5].

Intraluminal stents are extremely useful for bypassing tumors of the antropyloric region with GOO. However, in rare situations of scirrhous gastric adenocarcinomas with narrowing of long segments of the gastric lumen, those devices have a low rate of success.

We presented the case of a 65 year old male smoker who was treated with FOLFOX (folinic acid, fluorouracil and oxaliplatin) during a 2 month period due to a large T4 gastric tumor. After a lack of improvement with this therapeutic approach, a palliative procedure was considered to ameliorate vomiting in this patient. The post chemotherapy CT scan (Figure 1) disclosed a scirrhous type gastric cancer affecting the entire organ, pancreas, liver, and splenic hilum, with a partial splenic infarction. There was local lymph nodes enlargement without signs of peritoneal carcinomatosis. A barium swallow confirmed a long narrowing of the gastric lumen. Thus, gastric stenting was judged not to be useful in this particular case, and laparotomy was offered to the patient. After preoperative total parenteral nutrition for 14 days, the serum albumin level was 3.2 g/dL.

During laparotomy, carcinomatosis with a peritoneal carcinomatosis index (PCI)=11 was discovered. Total gastrectomy with en-bloc distal pancreateo splenectomy and partial II-III segmentectomy was carried out. The patient experienced intra-abdominal bleeding on the second postoperative day was treated conservatively and was discharged on the fifteenth postoperative day with an excellent oral intake. Forty five days after the surgical procedure, he started a second-line of chemotherapy with paclitaxel.

This case illustrates the difficulty in treating a patient with a stage IV gastric cancer with GOO [6]. There are some factors that increase the rate of complications in patients with multiorgan resection associated a gastrectomy in T4 gastric adenocarcinomas, such as age > 70 years, serum albumin level < 3 g/dL, peritoneal dissemination, and resection of two or more additional organs [2,3]. Our patient had two independent poor prognostic factors that were confirmed during the operation. Other surgical technical solutions were evaluated during the procedure, but total gastrectomy was deemed the only solution that permitted us to connect the distal esophagus with the small bowel. Histopathological results confirmed a poorly differentiated T4 adenocarcinoma with direct liver, pancreatic, and splenic artery invasion.

The first step of our approach was successful because the patient could eat again and recover his active life. The second step is controversial: could it offered any improved outlook for survival, and if so, for how long?

The impact of postoperative chemotherapy is very important in these cases [7,8], but the histological type and the previous failure with first-line chemotherapy were negative prognostic factors in our patient. However, there are other chemotherapy schemes which could offer benefits and should be used as a second-line treatment [9]. In 2006, Saidi and colleagues found a significant difference in mean survival time (16.3 months versus 5.9 months) among stage IV gastric cancer patients who underwent chemotherapy with or without gastric resection [10].

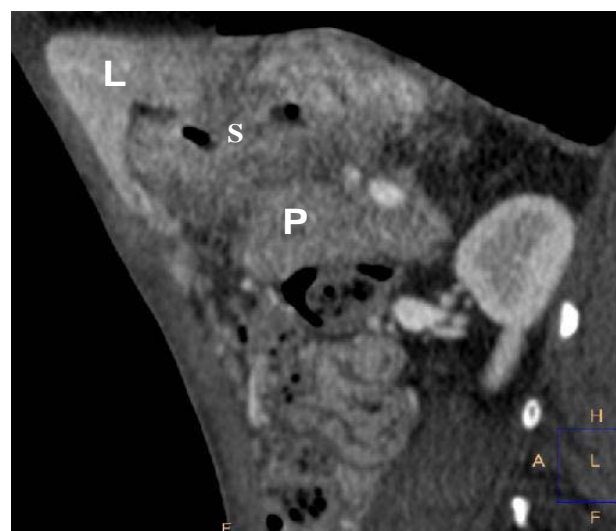


Figure 1: Post-chemotherapy abdominal CT scan disclosed a scirrhous gastric cancer (s) with invasion of liver (L) and pancreas (P).

In summary, aggressive multiorgan resections are usually contraindicated in stage IV gastric adenocarcinomas but should be considered in specific situations.

## References

1. Martin RC 2nd, Jaques DP, Brennan MF, Karpeh M. Extended local resection for advanced gastric cancer: increased survival versus increased morbidity. *Ann Surg.* 2002; 236: 159-165.
2. Ozer I, Bostanci EB, Orug T, Ozogul YB, Ulas M, Ercan M, et al. Surgical outcomes and survival after multiorgan resection for locally advanced gastric cancer. *Am J Surg.* 2009; 198: 25-30.
3. Mita K, Ito H, Fukumoto M, Murabayashi R, Koizumi K, Hayashi T, et al. Surgical outcomes and survival after extended multiorgan resection for T4 gastric cancer. *Am J Surg.* 2012; 203: 107-111.
4. Alonso-Lagarra JO, Álvaro-Villegas JC, Sobrino-Cossio S, Hernández-Guerrero A, de la Mora-Levy G, Figueroa-Barojas P. Self-expanding metal stents versus antrectomy for the palliative treatment of obstructive adenocarcinoma of the gastric antrum. *Rev Esp Enferm Dig.* 2012;104:185-189.
5. Fiori E, Lamazza A, Demasi E, Decesare A, Schillaci A, Sterpetti AV. Endoscopic stenting for gastric outlet obstruction in patients with unresectable antro pyloric cancer. Systematic review of the literature and final results of a prospective study. The point of view of a surgical group. *Am j Surg.* 2013; 206: 201-207.
6. Lasithiotakis K, Antoniou SA, Antoniou GA, Kaklamanos I, Zoras O. Gastrectomy for stage IV gastric cancer. a systematic review and meta-analysis. *Anticancer Res.* 2014; 34: 2079-2085.
7. Kokkola A, Louhimo J, Puolakkainen P. Does non-curative gastrectomy improve survival in patients with metastatic gastric cancer? *J Surg Oncol.* 2012; 106: 193-196.
8. Ko KJ, Shim JH, Yoo HM, O SI, Jeon HM, Park CH, et al. The clinical value of non-curative resection followed by chemotherapy for incurable gastric cancer. *World J Surg.* 2012; 36: 1800-1805.
9. Wilke H, Van Cutsem E, Cheul Oh S, Bodoky G, Shimada Y, Hironaka, et al. RAINBOW: a global, phase III, randomized, double-blind study of ramucirumab plus paclitaxel versus placebo plus paclitaxel in the treatment of metastatic gastroesophageal junction (GEJ) and gastric adenocarcinoma following disease progression on first-line platinum and fluoropyrimidine containing combination therapy rainbow IMCL CP12-0922 (14T-IE-JVBE). *J Clin Oncol.* 2014; 32: abstr LBA7.
10. Saidi RF, ReMine SG, Dudrick PS, Hanna NN. Is there a role for palliative gastrectomy in patients with stage IV gastric cancer? *World J Surg.* 2006; 30: 21-27.