

Clinical Image

Laparoscopic Hand-Assisted Extraperitoneal Colostomy via a Perineal Incision

Yamashita K*, Yoshida R, Waki N, Hirayama S, Kawai H, Nishi H and Ishizaki M

Department of Surgery, Okayama Rosai Hospital, Japan

*Corresponding author: Yamashita K, Department of Surgery, Okayama Rosai Hospital, 1-10-25 Chokkou-Midori-Machi, Okayama-City, 702-8055, Japan, Telephone: +81-86-262-0131; Fax: +81-86-262-3391; Email: kazukiyutoya@gmail.com

Received: May 27, 2014; Accepted: June 09, 2014;

Published: June 11, 2014

Keywords

Abdominoperineal resection; Extraperitoneal colostomy; Hand-assisted technique; Laparoscopy; Perineal incision

Headings: hand-assisted technique via perineal incision

Although an extraperitoneal colostomy is often performed to prevent postoperative parastomal hernia formation after an open abdominoperineal resection for rectal neoplasm's, it is not typically conducted via a laparoscopic approach because of the difficulty associated with the extraperitoneal route [1]. We describe a simple hand-assisted laparoscopic extraperitoneal sigmoid colostomy technique performed via a perineal incision. After the laparoscopic abdominoperineal resection, the surgeon inserted his left hand into the pelvis via a perineal incision (Figure 1). Then, under laparoscopic guidance, gently separated the peritoneum from the posterior aponeurotic plane to create an extraperitoneal tunnel using the fingers (Figure 2), just as in open methods. We performed the peritoneal separation from the previously dissected paracolic gutter toward the proposed stoma site in the left flank. The pneumoperitoneal pressure was maintained within the normal range during entire procedure. This surgical technique is easy, and helps to prevent the development

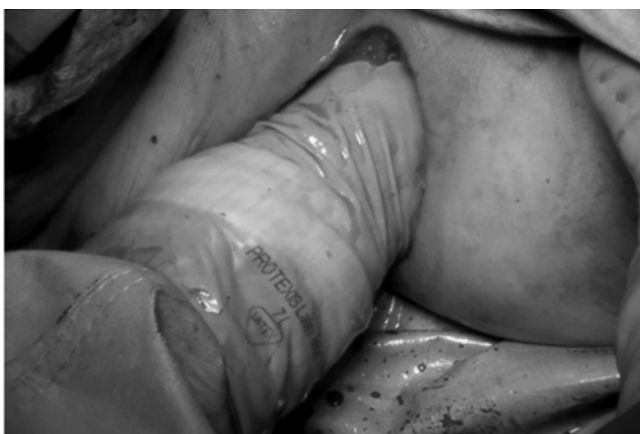

Figure 1: Left hand insertion.

The surgeon inserts his left hand into pelvic space via perineal incision. The surgeon's hand size is regular.

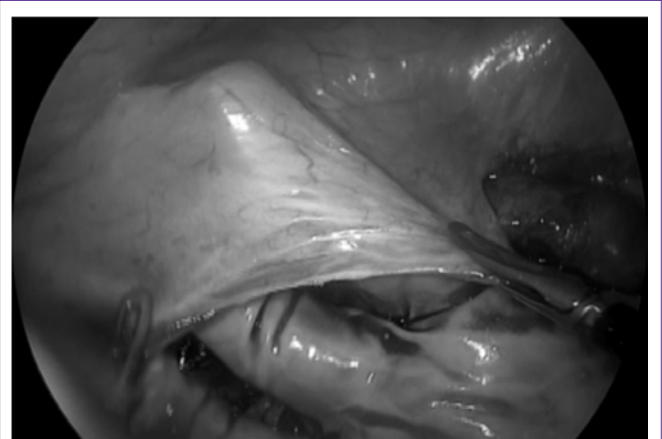


Figure 2: Separation of peritoneum.

Under laparoscopic guidance, a creation of an extraperitoneal tunnel using the fingers is easy.

of parastomal hernias.

Reference

1. Lian L, Wu XR, He XS, Zou YF, Wu XJ, Lan P, et al. Extraperitoneal vs. intraperitoneal route for permanent colostomy: a meta-analysis of 1,071 patients. *Int J Colorectal Dis.* 2012; 27: 59-64.