

Case Report

# Unusual Death in Garbage Recycling Site: A Study of Seven Cases

Gholamzadeh S<sup>1</sup>, Bahrani M<sup>1</sup>, Zarenezhad M<sup>1\*</sup>, Malekpour A<sup>1</sup>, Mortazavi M<sup>2</sup> and Kazemi B<sup>3</sup>

<sup>1</sup>Legal Medicine Research Center, Legal Medicine Organization of Iran, Iran

<sup>2</sup>Department of Biotechnology, Institute of Science and High Technology and Environmental Science, Graduate University of Advanced Technology, Iran

<sup>3</sup>Azad Islamic University, Kazeroon Branch, Iran

\*Corresponding author: Mohammad Zarenezhad, Legal Medicine Research Center, Legal Medicine Organization of Iran, Tehran, Iran

Received: June 07, 2017; Accepted: July 19, 2017;

Published: August 02, 2017

## Abstract

A landslide occurred in garbage recycling site, near Shiraz, Fars province, south Iran on 11th April 2014 around 8:30 am and seven municipal personnel were buried beneath the burning garbage for 1 and 2 days. All of occupants died and they were discovered one day and two days after the event. The cases were referred to legal medicine organization for Post Mortem Examination (PME) and determination of the cause of death. Gross examination of the victims showed grade 1 to 3 burning in different parts of the victims' bodies as well as stench odor, swelling body, progressive putrefaction of the body, bruise and postmortem peeled skin and postmortem rupture of the skin. Although the victims were trapped under the garbage, no foreign body was found in their pharynx, trachea and lung. Autopsy findings of the bodies showed sever transmutation of the brain, petechial hemorrhage between lung lobes, edema and congestion of the lung as well as color change of the liver and spleen in favor of cooked tissues. Accumulation of semi liquid fat in pleural and peritoneal spaces was unique finding caused by high temperature of the condition that the bodies were trapped in. The amount of the accumulated fat was different considering the Body Mass Index (BMI) of the victims; more fat was accumulated in pleural and peritoneal area of the victims with more values of the BMI. Defect burning of the garbage led to grade 1 to 3 burnings and indirect heat exposure to the bodies resulted in melting the body fats and accumulation in mentioned cavities.

**Keywords:** Asphyxia; Burning; Melting fat; Iran

## Introduction

Asphyxia is a condition presenting with cervicofacial cyanosis and edema, subconjunctival hemorrhage, and petechial hemorrhages of the lung, face, neck, and upper chest that occurs [1]. Asphyxial deaths can occur in variety of situations, such as motor vehicle accidents, railway-related fatalities, elevator accidents, buildings collapse, landslides and stampede. However, motor vehicle accidents are the most common cause of traumatic asphyxial deaths [2,3].

The external as well as the internal findings in burned bodies depend on the temperature actually the body has been exposed to, the time for which it is applied, the kind of transmission of the heat to the body, and other prevailing conditions [4-6]. On the other hand, morphological findings in burned bodies may cover a broad spectrum. They can range from minor, local, superficial burns of the skin to calcined skeletal remains without any soft tissue left [7].

Here, we aim to report unusual mortality of seven victims died in garbage recycling site suffered asphyxia and high temperature conditions.

## Case Presentation

In an observational study, we reported autopsy findings in bodies buried beneath a mountain of dump. A landslide occurred in burning garbage recycling site, near Shiraz, Fars province, south Iran on 11<sup>th</sup> April 2014 around 8:30 a.m. and seven municipal personnel were buried beneath the burning garbage for 1 day and 2 days. All of occupants died and they were discovered one day and two days after

the event. The cases were referred to forensic medicine administration for Post Mortem Examination (PME) and determination of the cause of death two and three days after the event. Body weight, height and body mass index of the victims were measured and calculated and gross and autopsy examinations were performed.

## Results

Table 1 shows demographic data as well as general and autopsy findings of the victims. Seven male municipal personnel 27 to 47 years old were buried beneath the burning garbage and discovered one and two days after the event. All of occupants died and they were discovered one day and two days after the event. Their body weight ranged from 39 to 89 kg and their height was 160 to 180 cm. Minimum and maximum BMI were 14.5 and 28.0 respectively.

## Gross examination

Gross examination of the victims showed grade 1 to 3 burning in different parts of the victims' bodies as well as stench odor, swelling body, progressive putrefaction of the body, bruise and postmortem peeled skin and postmortem rupture of the skin. Although the victims were trapped and buried under the garbage, no foreign body was found in their pharynx, trachea and lung. All of the victims were not capable for fingerprinting. In one of the victims broken tarsal bone of the left leg was observed. One other victim had several broken ribs related to the time that he was alive. Laxation of the neck vertebrae was observed in an individual related to after the death. A fracture and bruise were observed in the base of the skull in one of the individuals related to the lifetime.

**Table 1:** Demographic data, general and autopsy findings of the victims of mortality in garbage recycling site (Ht: Height in cm, Wt.: Weight in kg, BMI: Body Mass Index).

Case	Age	Ht.	Wt.	BMI	Gross Examination Findings	Autopsy Findings
1	43	168	41	14.5	Progressive putrefaction of the body, Stench odor, Post mortem peeled skin, swelled body, Color change of the body skin, bruise, Grade 2 burning of the face and left leg, rupture of left scrotum and protrusion of the left testicle, Non-finger printing.	Sever transmutation of brain, Petechial hemorrhage between lung lobe, edema and congestion of the lung, Color change of the liver and spleen in favor of cooking, 250 ml Semiliquid melted fat in pleural cavity and 200 ml in peritoneal space.
2	41	175	55	18.0	Progressive putrefaction of the body, Stench odor, Post mortem peeled skin, swelled body, Color change of the body skin, bruise, Grade 1 and 2 burning of face, neck and chest, postmortem rupture of the skin on mandible, Non-finger printing.	Sever transmutation of brain, Postmortem laxation of the neck vertebrates, Petechial hemorrhage between lung lobe, edema and congestion of the lung, lung collapse, Color change of the liver and spleen in favor of cooking, 1000 ml Semiliquid melted fat in pleural cavity and 150 ml in peritoneal space.
3	37	180	58	17.9	Progressive putrefaction of the body, Stench odor, Post mortem peeled skin, swelled body, Color change of the body skin, bruise, Grade 1, 2 and 3 burning of the face, neck, chest and lower and upper extremity, postmortem rupture of the skin on mandible, broken left tarsal bone, Non-finger printing.	Sever transmutation of brain, Petechial hemorrhage between lung lobe, edema and congestion of the lung, lung collapse, Color change of the liver and spleen in favor of cooking, 300 ml Semiliquid melted fat in pleural cavity, 50 ml in peritoneal space and 30 ml in pericardial space.
4	47	172	50	16.9	Body Putrefaction, Stench odor, Post mortem peeled skin, swelled body, Color change of the body skin, bruise, Grade 1, 2 and 3 burning of the face, neck and chest, Non-finger printing.	Sever transmutation of brain, Petechial hemorrhage between lung lobe, edema and congestion of the lung, lung collapse, Color change of the liver and spleen in favor of cooking, 50 ml Semiliquid melted fat in pleural cavity and 40 ml in peritoneal space
5	27	171	53	17.9	Sever Body Putrefaction, Post mortem peeled skin, Stench odor, swelled body, Color change of the body skin, bruise, Grade 1 and, 2burning of the face, neck and, chest, bruise on different parts of the body, Non-finger printing.	Sever transmutation of brain, Petechial hemorrhage between lung lobe, edema and congestion of the lung, left lung collapse, Color change of the liver and spleen in favor of cooking, 50 ml Semiliquid melted fat under the body skin, in pleural cavity and 20 ml around of the spleen
6	43	170	81	28.0	Sever Body Putrefaction, Post mortem peeled skin, Stench odor, swelled body, Color change of the body skin, bruise, Grade 1 and 2burning of the face, neck and, chest, bruise on different parts of the body, several spine and rib fractures, 5 cm rupture of the skin at temporal region, Non-finger printing.	Sever transmutation of brain, Petechial hemorrhage between lung lobe, edema and congestion of the lung, lung collapse, Color change of the liver and spleen in favor of cooking, 250 ml Semiliquid melted fat under the body skin, 500 ml in pleural cavity and 1000ml in peritoneal space, semiliquid fat in pericardial space, broken right clavicle, broken and detached ribs, protrusion of the spinal cord
7	39	160	39	15.2	Sever Body Putrefaction, Post mortem peeled skin, Stench odor, swelled body, Color change of the body skin, bruise, Grade 1 and, 2burning the face, neck and, chest, bruise on different parts of the body, several spine and rib fractures, postmortem rupture of the abdomen, Non-finger printing.	Sever transmutation of brain, fracture of the base of the skull in lifetime, fracture of right clavicle, sternum, and ribs Petechial hemorrhage between lung lobe, edema and congestion of the lung, right and left lung collapse, Color change of the liver and spleen in favor of cooking, Semiliquid melted fat in pleural cavity and in peritoneal space, semiliquid fat in pericardial space

### Autopsy findings

Autopsy findings of the bodies showed sever transmutation of the brain, petechial hemorrhage between lung lobes, edema and congestion of the lung as well as color change of the liver and spleen in favor of cooked tissues. Accumulation of semiliquid fat in pleural and peritoneal spaces was unique finding caused by high temperature of the condition that the bodies were trapped in. The amount of the accumulated fat was different considering the Body Mass Index (BMI) of the victims; more fat was accumulated in pleural and peritoneal area of the victims with more values of the BMI. Defect burning of the garbage had also led to grade 1 to 3 burnings and indirect heat exposure to the bodies resulted in melting the body fats and accumulation in mentioned cavities. In one of individuals (case No.3), 30 ml semiliquid fat was observed in pericardial space (Figure 1).

### Discussion

In forensic assessment of burned bodies, the question of whether the victim was directly or indirectly exposed to the fire before or after the death is of crucial importance [8,9]. Recently, several external signs have been used to indicate heat exposure prior to the death of the victim. The internal signs of heat exposure are generally regarded as much more important than those observed externally. No one factor has been found to be totally reliable [10]. In our cases, the bodies of the victims were not exposed to fire flames but they had been trapped

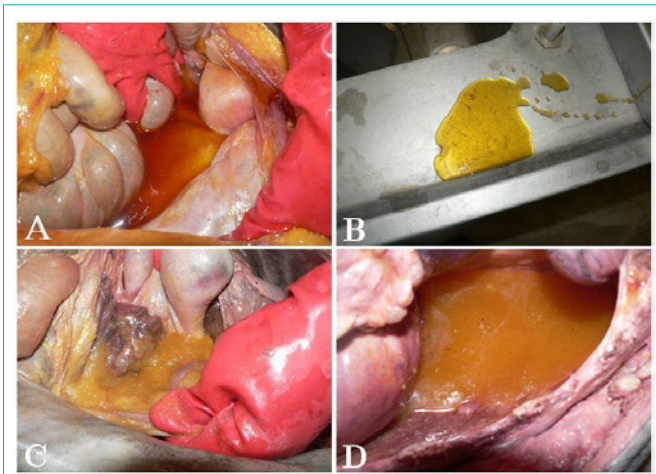
in high temperature conditions and high temperature had led to melting the body fats and accumulation of them in body cavities. As a very rare finding, the amount of melted and semiliquid accumulated fats in peritoneal and pleural cavities was relatively related to values of victims' BMI. Also, in bodies with more BMI, semiliquid fats were also observed in pericardial space and subcutaneous.

In fact, the cause of death for most of the victims (71.42%) was asphyxia as a result of trapping in oxygen less area. On the other hand, considering defect burning of the garbage, grade 1 to 3 burning had occurred at the time of death or a little after that.

Lung, conjunctival and facial petechiae, are nonspecific findings in asphyxial deaths [11]. In our study, petechial hemorrhage was observed between lung lobes of all cases.

Several fractures were also found in some of the victims caused by landslide and pressure of garbage materials leading to asphyxia. Differential diagnosis between peri-mortal fresh bone fractures and dry bone fractures for example in trauma by decomposition, displacement, or compression is critically important in determination of cause of death [12]. In two cases of this study (case No. 6 and 7), injuries were diagnosed to be peri-mortal and the cause of death was determined several injuries and fractures.

The association of petechial hemorrhages with asphyxia is well known [13,14]. In all of our cases, petechial hemorrhage was observed



**Figure 1:** Autopsy findings of the death in Garbage Recycling Site, A: Accumulated liquid body fat in peritoneal cavity, B: liquid body fat, C: Accumulated Semiliquid body fat in peritoneal cavity, D: Accumulated liquid body fat in pleural cavity.

between the lung lobes. The lungs in all of the victims were severely edematous and congested presenting nature of asphyxia [15,16].

Decomposition or putrefaction is the final post-mortem stage [17]. High temperature and putrefactive nature of the environment bodies trapped in had led to rapid putrefaction of the bodies, more soon than it was expected. Not being capable for finger printing and sever transmutation of the brain in all of the cases were because of rapid and severe putrefaction resulted from high temperature and putrefactive bacterial load. Postmortem peeling and rupture of the body skin as well as color change and swelled body were other signs of rapid and sever putrefactive events. Other literature also mentions that bodies in fire and high temperature deaths decompose quickly due to the high ambient temperatures [18]. Elevated ambient temperatures also enhance the odor of putrefying bodies [19].

Unique findings of this report can be considered as import guidance in forensic medicine and be used in determination of the cause of death in similar events.

## Acknowledgment

Here, we thank personnel of Autopsy ward, Forensic Medicine administration of Fars province, Iran for their kind cooperation.

## References

- Sah B, Yadav B, Jha S. A case report of Traumatic Asphyxia. *Journal of College of Medical Sciences-Nepal*. 2015; 10: 51-55.
- Conroy C, Stanley C, Eastman AB, Vaughan T, Vilke GM, Hoyt DB, et al. Asphyxia: a rare cause of death for motor vehicle crash occupants. *Am J Forensic Med Pathol*. 2008; 29: 14-18.
- Zanjad N, Bhosle S, Dake M, Godbole HV. Study of Violent Asphyxial Deaths: a 10-Year Retrospective Study. *Medico-Legal Update*. 2015; 15: 43-48.
- Bohnert M. Morphological findings in burned bodies. *Forensic pathology reviews: Springer*. 2004; 3-27.
- Tümer AR, Akçan R, Karacaoğlu E, Balseven-Odabaşı A, Keten A, Kanburoğlu Ç, et al. Postmortem burning of the corpses following homicide. *J Forensic Leg Med*. 2012; 19: 223-228.
- Peranantham S, Manigandan G, Shanmugam K. Forensic approach to a case of death due to burn injury: a case report. *International Journal of Research in Medical Sciences*. 2014; 2: 1214.
- Bohnert M, Werner CR, Pollak S. Problems associated with the diagnosis of vitality in burned bodies. *Forensic Sci Int*. 2003; 135: 197-205.
- Bernitz H, van Staden P, Cronjé C, Sutherland R. Tongue protrusion as an indicator of vital burning. *Int J Legal Med*. 2014; 128: 309-312.
- Dirkmaat DC, Olson GO, Klaes AR, Getz S. The role of forensic anthropology in the recovery and interpretation of the fatal-fire victim. A companion to forensic anthropology. 2012; 10: 113.
- Vij K. *Textbook of Forensic Medicine & Toxicology: Principles & Practice*: Elsevier Health Sciences; 2014.
- Ely SF, Hirsch CS. Asphyxial deaths and petechiae: a review. *Journal of Forensic Science*. 2000; 45: 1274-1277.
- Jordana F, Colat-Parros J, Bénézech M. Breakage patterns in human cranial bones. *Romanian J Leg Med*. 2013; 21: 287-292.
- Kumar GP, Manjunatha B, Rani S, Balaraj B, Babu YR. Traumatic asphyxial deaths. *Elective Medicine Journal*. 2014; 2: 319-320.
- Dettmeyer RB, Verhoff MA, Schütz HF. *Asphyxia*. Forensic Medicine: Springer; 2014. p. 227-41.
- Cao Y, Yu Y, Gao X, Jin H, Lu M, Gong D, et al. Asphyxia death caused by epiglottic abscess rupture in an adult: A case report. *Rom J Leg Med*. 2014; 22: 233-236.
- Pan H, Lv Y, Zhang H, Xue A, Chen L. Death from a special mechanical asphyxia during suspect restraint: A case report. *Rom J Leg Med*. 2014; 22:81-84.
- Wilkinson C. A review of the changing culture and social context relating to forensic facial depiction of the dead. *Forensic Science International*. 2014; 245: 95-100.
- Zhou C, Byard RW. Factors and processes causing accelerated decomposition in human cadavers—an overview. *Journal of forensic and legal medicine*. 2011; 18: 6-9.
- Sims DN, Langlois NE, Byard RW. An approach to peer review in forensic pathology. *Journal of forensic and legal medicine*. 2013; 20: 402-403.