

Special Article - Forensic Medicine

Public Order Disturbance: Is the use of Non/Less - Lethal Weapon always Adapted? A French Case Report

Grenier F^{1*}, Chiron F¹, Eysseric H², Paysant F¹,
Peoc'h M³ and Scolan V¹

¹Département de Médecine Légale, Université Grenoble Alpes, France

²Département de Pharmacologie et Toxocologie, Université Grenoble Alpes, France

³Département de Anatomie Pathologique, Université Grenoble Alpes, France

*Corresponding author: Grenier F, Département de Médecine Légale, Université Grenoble Alpes, Médecine Légale, Chu Grenoble, Boulevard de la Chantourne, 38700 La Tronche, France

Received: September 20, 2016; Accepted: October 27, 2016; Published: October 31, 2016

Abstract

The scientific literature describes many injuries secondary to the use of non-lethal weapons such as Taser® or Flashball® devices. We relate here the cases of a woman and a man presenting a psychomotor agitation, victims of multiple Taser® or Flashball® firing. The man died. Based on these cases, we discuss the use of these non-lethal weapons in case of psychomotor agitation, disturbance of public order and Excited Delirium syndrome. Although the causality can't be proven in the death of the man, these devices seem not adapted in these situations, exposing the target to wounds and possible sequelae. The training of the police officers or security agents to recognize these situations and use other solutions than the force and the non-lethal weapons should be promoted.

Keywords: Non-lethal weapons; Psychomotor agitation; Excited delirium syndrome; Flashball®; Taser®

Introduction

According to the scientific literature, non-lethal weapons have been developed in most countries since the 1960s [1-3]. They have been used by the French police for about almost 20 years including Flash ball® and Taser®. French police is equipped by Flash ball® which fires a rubber ball (caliber 44 mm, weight 28 g) with a kinetic energy close to 200 J, causing blunt impact, and Taser X26 propelling two electrodes linked by two cables, causing an electric shock of 2 mA for 50 000 V.

As a remainder, those weapons were designed to incapacitate a violent and/or dangerous individual while minimizing the risk of permanent injuries or death: thus must be a temporary means to neutralize, not fatal in normal use. Several articles [3-5] have already been published about the potential risk of death by these less-lethal weapons.

In this article, we want to draw attention to the lack of response from people with psychomotor agitation and aggressive behavior, which gives rise to more Taser® and Flash ball® shots, increasing the risks of secondary effects.

Case Presentation

Case 1

The police was called because of a woman yelling at her window and threatening to cut herself with a knife. She was a 52 year-old, overweight woman, without treatment but formerly treated with Risperidone.

When police arrived (5 men plus 5 enforcements), she was extremely violent, trying to attack officers with a knife and a hatchet. She pushed them to the ground, cutting their protection shield.

She was shot by Taser® with one electrode in the chest and one in the right thigh, receiving a total 3 electric shocks and 4 times by Flash ball®, but she continued to threaten the police. An officer had to shoot with a real weapon, on the ground, behind her to stop her and permit

to his colleagues to catch and after 5 minutes, they arrested her. She was brought to the emergency. She had the following wounds:

- 1 longitudinal, 20 x 10 cm hematoma extending over the inferior third of the dorsal left forearm to the dorsal side of the left hand (Figure 1A)
- 2 adjacent, oval-shaped skin abrasions of 5 cm of diameter each, of the superior third, lateral side of the left thigh (Figure 1A)
- 1 hematoma of 15 cm of diameter of the left hypochondrium, with inside a novel-shaped skin abrasion, of 5 cm of diameter (Figure 1B)
- 2 oval-shaped skin abrasions, of 0.5 cm of diameter:
 1. 1 in the middle third of the sternum (Figure 1C)
 2. 1 in the inferior third of the left thigh (Figure 1D)
- Multiples self-inflicted superficial erosions around her neck and her left fore-arm.

The blood analysis found a rhabdomyolysis with increased creatine kinase 486 UI/l (26-192). Ionogram and hemogram were normal.

She stayed one night in medical supervision in emergency and she was hospitalized in psychiatric hospital.

The police officers described a woman impossible to reason with, tireless, with an increased strength increased, insensitive to pain with a hot skin temperature.

Case 2

A 42 year old man presented a psychomotor agitation in the tramway. He insulted people around and he finally left the public transport to try to enter in a shop. Two security officers stopped him, but he became physically violent. They had lot of difficulties to control him, and one of the officers used a "Shocker" (a non-lethal device producing 50 000 V between two electrodes, only used in direct melee).

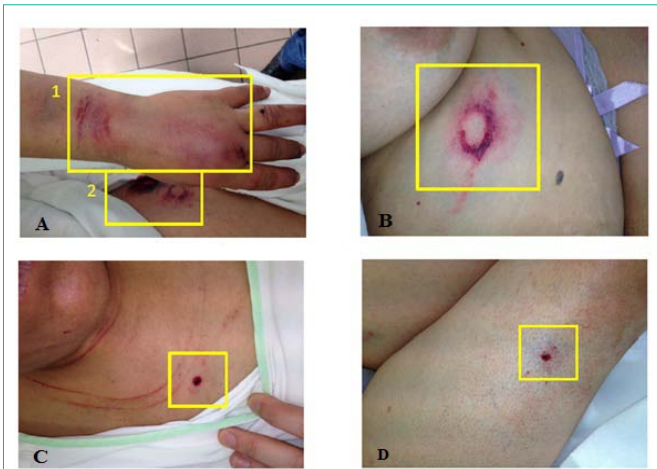


Figure 1A: Flashbater®
1-1 longitudinal, 20 x 10 cm hematoma extending over the inferior third of the dorsal left forearm to the dorsal side of the left hand. 2- 2 adjacent, oval-shaped skin abrasions of 5 cm of diameter each, of the superior third, lateral side of the left thigh.

Figure 1B: Flashball®
1 hematoma of 15 cm of diameter of the left hypochondrium, with inside an oval-shaped skin abrasion, of 5 cm of diameter.

Figure 1C: Taser® oval-shaped skin abrasion of 0.5 cm of diameter, in the middle third of the sternum.

Figure 1D: Taser® oval-shaped skin abrasion of 0.5 cm of diameter, in the inferior third of the left thigh.

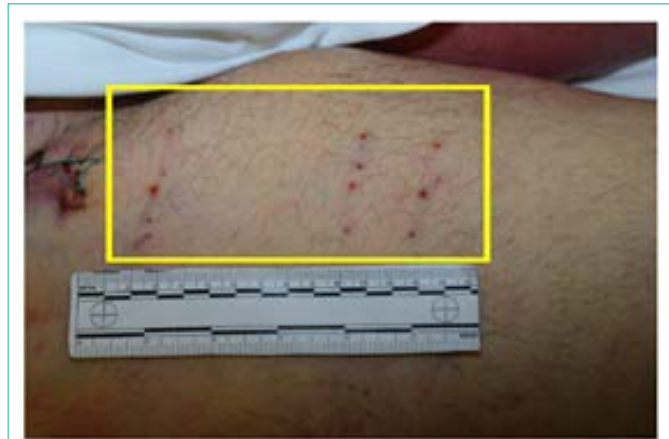

Figure 2: Taser® Three linear roughly parallel wounds, anterior face of the right thigh, with four dots shaped wounds in each.

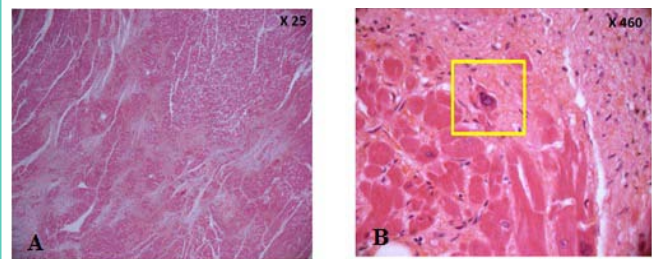


Figure 3A: Haematoxylin Eosin Safran staining: myocardial infarct with fibrosis X 25: Scar tissue, fibrosis, rare cardiomyocytes with irregular and hypochromic nucleus.

Figure 3B: X 460: dystrophic nucleus.

He was shocked three times in the right thigh without effect and after few minutes, he had a cardiac arrest and died despite the work of the emergency services.

On the corpse, we noted:

- Signs of Medical care
- Signs of blunt trauma
 1. Bruises on both arms
 2. Hematoma under the left clavicular bones
- Three linear, roughly parallel wounds, anterior face of the right thigh, with four dot-shaped wounds in each (Figure 2)
- Left cardiac hypertrophy
- A non-specific asphyxia syndrome with pulmonary edema

The histological examination showed septal myocardial sub-acute ischemia which might have caused cardiac rhythm disorders and heart failure (Figure 3A and B). The toxicology exams noted a sanguine concentration potentially lethal in cocaine (994 µg/L) (metabolites: Benzoyl Ecgonine: 6230 µg/L, Ecgonine Methyl Ester : 2020 µg/L) .

The cause of death was assigned to the cocaine consumption and cardiac failure.

Discussion

In the first case, according to the allegation of the actors and the clinical exam, the wounds of the chest and the right thigh were assigned to the Taser® effect and the wounds of the left hand, left hypochondrium, and the left thigh to the Flashball® effect.

In the second case, taking account of the different statements and of the corpse exam, the three right thigh wounds were attributed to the Taser® effect.

How can we explain the absence of response to the Taser®?

A psychological explanation is possible. The psychomotor agitation or Excited delirium syndrome (ExDS) can play a role. Psychomotor agitation can have different causes like bipolar disorder, post-traumatic stress disorder, panic attacks, anxiety disorder, alcohol withdrawal, claustrobia, dementia, parkinson’s disease, traumatic brain injury, organic brain disease, drugs abuse... etc.

In our first case, the cause was a bipolar disorder in “therapeutic break” and in our second case, the use of cocaine can explain the agitation. During this episode, the person behavior is modified with agitation, suicidal ideation, and some consciousness impairments... Furthermore, Di Maio [6] defined Excited delirium syndrome (ExDS) as “an acute (minutes to hours), transient disturbance in consciousness and cognition; disorganized and inconsistent thought processes; inability to distinguish reality from hallucinations; disturbances in speech; disorientation to time and place; misidentification of individuals “associating combative and/or violent behavior” with delirium. According to Vilke [7], it’s a complex entity, formerly associated with an agitation state and the sudden death in custody syndrome. Recently, the American College of Emergency Physicians recognized the ExDS and a Canadian study brought to light 10 clinical features: pain tolerance, tachypnea, sweating, agitation, tactile

hyperthermia, non-compliance with police, lack of tiring, unusual strength, inappropriately clothing, and mirror or glass attraction [8]. The causes can be drugs use [9,10] or brutal cessation of psychotherapeutic drug [11]. Biologically, acidosis, rhabdomyolysis, hyperkalemia and hyperthermia can be found [7].

The treatment associates physical control measures and chemical sedation under medical control [7,12].

This description seems to match with our cases and we can speak of Excited Delirium syndrome especially about the first case, which is more detailed.

In a first case, a physiological explanation to the absence of response is also possible. A study [13] demonstrates the shield effect of the sternum. In their study, helped with finite element modeling, inspired by human model with average human dimension, on which they applied 1700 V, they showed that the sternum had a higher resistivity to the electrical current than the fat tissue. The results were the same even with just one dart hitting the sternum or in case of one dart in the sternum and one in the abdomen. In addition, the residual electrical current predicted on the models was insufficient to cause either cardiac capture or induction of ventricular fibrillation.

So, in our case, the association of fat (woman in overweight) and sternum shield effect can play an important role. This finding may explain the absence of secondary cardiac effect like rhythm disorders which could be occur.

In the second case, we can't demonstrate the effect of the Taser[®] but it could play a role.

Flashball[®] and Taser[®] risks.

Concerning the Taser[®] risks, the scientific literature reports severe fingers trauma, severe ocular lesions, facial and testicular trauma with sequelae can occur [14-17].

According to the scientific literature, Flash Ball[®] can be responsible of chest injury (lung contusion) [18], severe eye and facial trauma (skin kids, hyphaema, ruptured globe, orbital fracture and retinal damage) [19,20] and severe craniocerebral trauma with sequelae [21]. A suicidal death using a Flashball[®] with a shot in the mouth was published [22] showing the possible lethal effect of this weapon, depending of the range of fire.

In our first case, the multiplication of the shots in the agitation condition could have serious consequences.

In the light of these elements, the use of those less-lethal weapons appears inappropriate and dangerous in the context of a person in state of psychomotor agitation or ExDS. The safety rules can be non-observed (range, multiple firing) and can lead to severe injuries.

Conclusion

Police officers and Security agents must be trained to recognize persons in psychomotor agitation and Excited Delirium syndrome. As we seen it, the use of less-lethal weapons cannot have effect on them, and the multiplication of the shots and the electric shocks are dangerous and may lead to severe sequelae or even death.

References

- Alexander JB. An overview of the future of non-lethal weapons. *Med Confl Surviv.* 2001; 17: 180-193.
- Jussila J. Future police operations and non-lethal weapons. *Med Confl Surviv.* 2001; 17: 248-259.
- Scolan V, Herry C, Carreta M, Stahl C, Barret L, Romanet JP, et al. Risks of non-lethal weapon use: case studies of three French victims of stinger grenades. *Forensic Sci Int.* 2012; 223: e18-e21.
- Coupland RM. "Non-lethal" weapons: precipitating a new arms race. *BMJ.* 1997; 315: 72.
- Di Maio VJ. Rubber plastic bullet, in: F.L. Boca Raton (Ed.), *Gunshot Wounds*, 2nd ed. CRC Press; 1999.
- Di Maio T, Di Maio VJM. *Excited delirium syndrome; cause of death and prevention.* CRC/Taylor and Francis; 2006.
- Vilke GM, DeBard ML, Chan TC, Ho JD, Dawes DM, Hall C, et al. Excited Delirium Syndrome (ExDS): defining based on a review of the literature. *J Emerg Med.* 2012; 43: 897-905.
- Hall C, Butler C, Kader A, et al. Police use of force, injuries and death: prospective evaluation of outcomes for all police use of force/restraint including conducted energy weapons in a large Canadian city. *Acad Emerg Med.* 2009; 16: S198-S199.
- Karch SB, Wetli CV. Agitated delirium versus positional asphyxia. *Ann Emerg Med.* 1995; 26: 760-761.
- Karch SB, Stephens BG. Drug abusers who die during arrest or in custody. *J R Soc Med.* 1999; 92: 110-113.
- Morrison A, Sadler D. Death of a psychiatric patient during physical restraint. Excited delirium--a case report. *Med Sci Law.* 2001; 41: 46-50.
- Vilke GM, Payne-James J, Karch SB. Excited delirium syndrome (ExDS): redefining an old diagnosis. *J Forensic Leg Med.* 2012; 19: 7-11.
- Panescu D, Kroll M, Iverson C, Brave M. The sternum as an Electrical Shield. *Conf Proc IEEE Eng Med Biol Soc.* 2014; 2014: 4464-4470.
- Abada H, Aktouf A, Delaunay F, Lievain L, Auquit-Auckbur I. Alopecia reconstruction by expansion after a scalp burn injury caused by Taser[®]: a case report. *Ann Dermatol Venereol.* 2014; 141: 769-772.
- Dunet B, Erbland A, Abi-Chahla ML, Tournier C, Fabre T. The TASERed finger: A new entity. Case report and review of literature. *Chir Main.* 2015; 34: 145-148.
- Rafailov L, Temnogorod J, Tsai FF, Shinder R. Impaled Orbital TASER Probe Injury Requiring Primary Enucleation. *Ophthal Plast Reconstr Surg.* 2015.
- Theisen K, Slater R, Hale N. Taser-Related Testicular Trauma. *Urology.* 2016; 88: e5.
- Wahl P, Schreyer N, Yersin B. Injury pattern of the Flash-Ball, a less-lethal weapon used for law enforcement: report of two cases and review of the literature. *J Emerg Med.* 2006; 31: 325-330.
- Lavy T, Asleh SA. Ocular rubber bullet injuries. *Eye (Lond).* 2003; 17: 821-824.
- Pinaud V, Leconte P, Berthier F, Potel G, Dupas B. Orbital and ocular trauma caused by the Flash-Ball[®]: a case report. *Injury extra.* 2009; 40: 172-174.
- Hiquet J, Gromb-Monnoyeur S. Severe craniocerebral trauma with sequelae caused by Flash-Ball[®] shot, a less-lethal weapon: Report of one case and review of the literature. *Med Sci Law.* 2016; 56: 237-240.
- Faller-Marquardt M, Braunwarth R. Suicidal shot in the mouth with a rubber shot shell. *Arch Kriminol.* 2004; 213: 76-83.